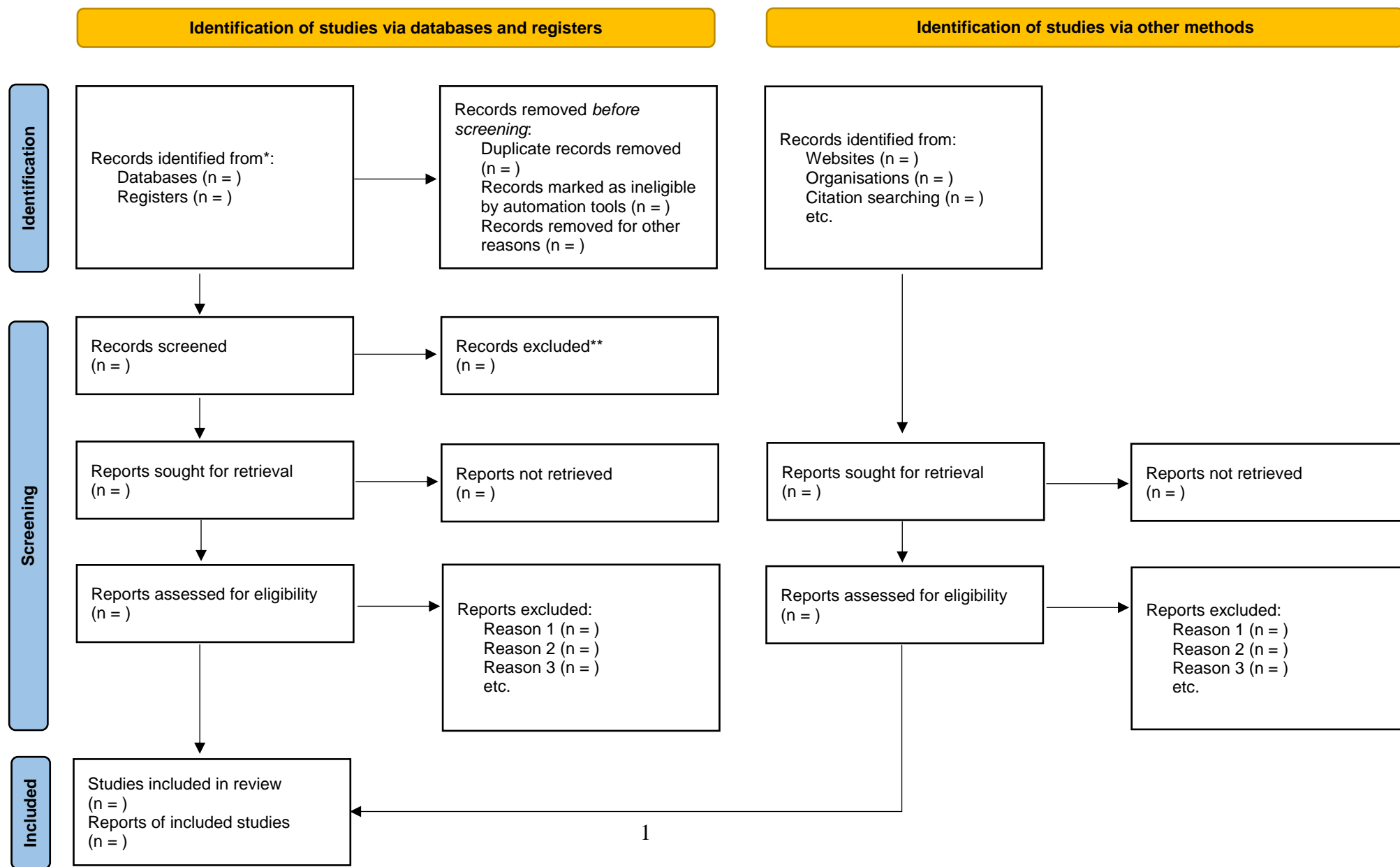


Supplementary Table 1. PRISMA 2020 guideline



*Consider, if feasible to do so, reporting the number of records identified from each database or register searched (rather than the total number across all databases/registers).
**If automation tools were used, indicate how many records were excluded by a human and how many were excluded by automation tools.

From: Page MJ, McKenzie JE, Bossuyt PM, Boutron I, Hoffmann TC, Mulrow CD, et al. The PRISMA 2020 statement: an updated guideline for reporting systematic reviews. *BMJ* 2021;372:n71. doi: 10.1136/bmj.n71. For more information, visit: <http://www.prisma-statement.org/>

Supplementary Table 2. Risk of bias assessment

	DOI	Study participation	Study attrition	Prognostic factors	Prognostic factor measurement	Outcome(s)	Outcome measurement	Study confounding	Statistical analysis and reporting	Overall rate
Allassaf et al. ¹ 2018	10.1007/s00590-019-02601-5	Low	N/A	age, gender, laterality, uni-bilateral, IHDI grade, acetabular index	Low	intraoperative failure, postoperative failure, failed reduction	Low	Low	Low	High quality
Arneill et al. ² 2021	10.1302/2633-1462.28.BJO2021-0088.R1	Moderate	N/A	gender, age at Pavlik application, age at closed reduction, laterality, US classification, adductor tenotomy	Low	intraoperative failure, postoperative failure, failed reduction, overall failure	Low	Low	Low	High quality
Bachy et al. ³ 2012	10.1007/s11832-012-0382-6	Low	High	age, gender, uni-bilateral, previous treatment, traction	Moderate	postoperative failure	Low	Moderate	N/A	Acceptable quality
Barakat et al. ⁴ 2017	10.1097/BCO.000000000000478	Low	Low	age, laterality, Tönnis grade, acetabular index	Low	overall failure	Low	Low	Low	High quality
Bhaskar et al. ⁵ 2016	10.4103/0019-5413.189610	Low	N/A	uni-bilateral, acetabular index, ossific nucleus	Low	redislocation	Low	Moderate	Low	High quality
Danielsson et al. ⁶ 2000	10.1080/000164700317411816	Low	Low	age, gender, uni-bilateral, laterality	Low	intraoperative failure, redislocation	Low	Moderate	N/A	High quality
Daoud et al. ⁷ 1996	10.2106/00004623-199601000-00005	Low	N/A	age, gender, uni-bilateral, laterality	Low	failed reduction, redislocation	Low	Moderate	N/A	High quality
Elerson et al. ⁸ 2022	10.1097/BPO.0000000000002038	Low	Low	traction	Low	overall failure	Low	Moderate	Low	High quality
Elghobashy et al. ⁹ 2021	10.1097/BPB.0000000000000749	Moderate	N/A	Tönnis grade, FAZ grade	Low	overall failure	Low	Moderate	Low	Acceptable quality
Fleissner et al. ¹⁰ 1994	10.1097/01241398-199409000-00016	Moderate	N/A	limbus type, cone of stability	Low	redislocation	Moderate	Moderate	Moderate	Acceptable quality
Forlin et al. ¹¹ 1992	10.2106/00004623-199274080-00003	Low	N/A	age, gender, laterality, uni-bilateral, tenotomy, shape of limbus, medialization ratio, distance from H-line, width of pool of contrast medium	Low	redislocation	Low	Moderate	N/A	High quality

Huang et al. ¹² 1997	10.1097/00004694-199703000-00009	Low	N/A	age, laterality, uni-bilateral, Tönnis grade, acetabular index, traction	Low	failed reduction, redislocation, overall failure	Low	Low	N/A	High quality
Jones et al. ¹³ 1992	10.1097/01241398-199211000-00004	Low	N/A	age, laterality, uni-bilateral	Low	overall failure	Low	Moderate	N/A	High quality
Kubo et al. ¹⁴ 2019	10.1097/BPB.0000000000000604	Low	N/A	Graf grade	Low	postoperative failure, redislocation	Low	Moderate	N/A	High quality
Li et al. ¹⁵ 2019	10.1097/BPB.0000000000000586	Low	N/A	traction, Tönnis grade	Low	failed reduction	Low	Moderate	Low	High quality
Li et al. ¹⁶ 2020	10.1097/BPB.0000000000000672	Low	N/A	age, Tönnis grade	Low	redislocation	Low	Moderate	Low	High quality
Mitani et al. ¹⁷ 1997	10.1302/0301-620x.79b5.7728	Moderate	N/A	limbus type	Low	redislocation	Low	Moderate	Moderate	Acceptable quality
Morris et al. ¹⁸ 2021	10.2106/JBJS.20.00562	Low	N/A	age, gender, IHDI grade	Low	intraoperative failure	Low	Low	Low	High quality
Murray et al. ¹⁹ 2007	-	Low	N/A	uni-bilateral	Low	failed reduction	Low	Low	Low	High quality
Pospischill et al. ²⁰ 2012	10.1007/s11999-011-1929-4	Low	N/A	uni-bilateral, Graf grade, previous brace treatment, ossific nucleus	Low	intraoperative failure	Low	Low	Low	High quality
Ramo et al. ²¹ 2018	10.1097/BPO.0000000000000733	Moderate	N/A	IHDI grade, Tönnis grade	Low	overall failure	Low	Moderate	Low	High quality
Sankar et al. ²² 2019	10.1097/BPO.0000000000000895	Low	Low	age, gender, laterality, uni-bilateral, anamnesis, ossific nucleus, previous brace treatment, traction, prereluction reducibility, soft tissue release, arthrogram, IHDI grade, length of spica casting	Low	failed reduction, redislocation	Low	Low	Low	High quality
Schoenecker et al. ²³ 1995	10.1097/01241398-199511000-00008	Moderate	N/A	age, modified Tönnis grade, acetabular index	Low	failed reduction, redislocation, overall failure	Low	Low	N/A	Acceptable quality
Senaran et al. ²⁴ 2007	10.1097/01.bpb.0000248567.49089.f0	Low	N/A	age, gender, laterality, uni-bilateral, duration of previous brace treatment, Harcke grade	Low	failed reduction, redislocation, overall failure	Low	Low	N/A	High quality
Sucato et al. ²⁵ 2017	10.1097/BPO.0000000000000747	Low	N/A	traction, Tönnis grade	Low	overall failure	Low	Moderate	Low	High quality
Talathi et al. ²⁶ 2020	10.1097/BPO.00000000000001429	Low	Low	age, gender, laterality, uni-bilateral, previous brace treatment, hip abduction, prereluction	Low	overall failure	Low	Low	Low	High quality

				reducibility, Graf grade, femoral head coverage (US), IHDI grade						
Tennant et al. ²⁷ 2016	10.1302/0301-620X.981311.36606	Low	N/A	age, gender, previous brace treatment, laterality, uni-bilateral, ossific nucleus, acetabular index, Tönnis grade, soft tissue release	Low	overall failure	Low	Low	Low	High quality
Tennant et al. ²⁸ 2019	10.1097/BPO.0000000000001297	Low	N/A	Tönnis grade	Low	overall failure	Low	Moderate	N/A	High quality
Terjesen et al. ²⁹ 2020	10.1302/2633-1462.14.BJO-2019-0005.R1	Low	N/A	age, traction	Low	overall failure	Low	Moderate	Low	High quality
Ucpunar et al. ³⁰ 2020	10.1007/s43465-020-00079-6	Low	N/A	age, gender, previous brace treatment, IHDI grade	Low	overall failure	Low	Low	N/A	High quality
Yilar et al. ³¹ 2021	10.1097/BPB.0000000000000752	Low	N/A	age, gender, laterality, uni-bilateral, Tönnis grade, acetabular index	Low	redislocation	Low	Low	Low	High quality
Yu et al. ³² 2021	10.1016/j.ultrasmedbio.2020.08.010	Low	N/A	age, gender, laterality, uni-bilateral	Low	postoperative failure	Low	Moderate	N/A	High quality
Yuan et al. ³³ 2020	10.1302/1863-2548.14.200132	Low	N/A	age, gender, laterality, uni-bilateral, hip abduction, IHDI grade, presence of ossific nucleus, acetabular index, inverted labrum, delineation of arthrogram	Low	failed reduction	Low	Low	Low	High quality
Zhang et al. ³⁴ 2020	10.1186/s13018-020-02098-3	Low	N/A	age, gender, uni-bilateral, presence of ossific nucleus, duration of previous brace treatment, Tönnis grade, IHDI grade, acetabular index, walking	Low	redislocation	Low	Low	Low	High quality

REFERENCES

1. Alassaf N: Treatment of developmental dysplasia of the hip (DDH) between the age of 18 and 24 months. *Eur J Orthop Surg Traumatol* 2020 May;30(4):637-641.
2. Arneill M, Cosgrove A, Robinson E: Should closed reduction of the dislocated hip be attempted after failed Pavlik harness treatment in developmental dysplasia of the hip? *Bone Jt Open* 2021 Aug;2(8):584-588.
3. Bachy M, Thevenin-Lemoine C, Rogier A, Mary P, Ducou Le Pointe H, Vialle R: Utility of magnetic resonance imaging (MRI) after closed reduction of developmental dysplasia of the hip. *J Child Orthop* 2012 Mar;6(1):13-20.
4. Barakat AS, Zein AB, Arafa AS, Azab MA, Reda W, Hegazy MM, Al Barbary HM, Kaddah MA: Closed reduction with or without adductor tenotomy for developmental dysplasia of the hip presenting at walking age. *Curr Orthop Pract* 2017 Mar;28(2):195-199.

5. Bhaskar A, Desai H, Jain G: Risk factors for early redislocation after primary treatment of developmental dysplasia of the hip: Is there a protective influence of the ossific nucleus? *Indian J Orthop* 2016 Sep;50(5):479-485.
6. Danielsson L: Late-diagnosed DDH: a prospective 11-year follow-up of 71 consecutive patients (75 hips). *Acta Orthop Scand* 2000 Jun;71(3):232-42.
7. Daoud A, Saighi-Bououina A: Congenital dislocation of the hip in the older child. The effectiveness of overhead traction. *J Bone Joint Surg Am* 1996 Jan;78(1):30-40.
8. Elerson EE, Martin BD, Muchow RD, Pierce WA, Jo CH, Hinds SA, Birch JG: Outpatient Bryant's Overhead Traction Does Not Affect the Rate of Open Reduction or Avascular Necrosis in Developmental Dislocation of the Hip. *Journal of Pediatric Orthopaedics* 2022 Mar 1;42(3):e266-e270.
9. Elghobashy OH, Kutty S, Dawood AA, Hadrawi AT, Alharbi HH, Barakat AS, Zohdy KK, Gaine WJ: Proposal of a novel predictive radiological method to assess the possibility of closed reduction in late presenting developmental dysplasia of the hip: the femoro-acetabular zones. *J Pediatr Orthop B* 2021 Mar 1;30(2):132-138.
10. Fleissner PR Jr, Ciccarelli CJ, Eilert RE, Chang FM, Glancy GL: The success of closed reduction in the treatment of complex developmental dislocation of the hip. *J Pediatr Orthop* 1994 Sep-Oct;14(5):631-5.
11. Forlin E, Choi IH, Guille JT, Bowen JR, Glutting J: Prognostic factors in congenital dislocation of the hip treated with closed reduction. The importance of arthrographic evaluation. *J Bone Joint Surg Am* 1992 Sep;74(8):1140-52.
12. Huang SC, Wang JH: A comparative study of nonoperative versus operative treatment of developmental dysplasia of the hip in patients of walking age. *J Pediatr Orthop* 1997 Mar-Apr;17(2):181-8.
13. Jones GT, Schoenecker PL, Dias LS: Developmental hip dysplasia potentiated by inappropriate use of the Pavlik harness. *J Pediatr Orthop* 1992 Nov-Dec;12(6):722-6.
14. Kubo H, Pilge H, Holthoff JP, Westhoff B, Krauspe R: MRI reveals unrecognized treatment failures after application of Fettweis plaster in children with unstable hip joints. *J Pediatr Orthop B* 2019 Sep;28(5):430-435.
15. Li YQ, Li M, Guo YM, Shen XT, Mei HB, Chen SY, Shao JF, Tang SP, Canavese F, Xu HW: Traction does not decrease failure of reduction and femoral head avascular necrosis in patients aged 6-24 months with developmental dysplasia of the hip treated by closed reduction: a review of 385 patients and meta-analysis. *J Pediatr Orthop B* 2019 Sep;28(5):436-441.
16. Li Y, Lin X, Liu Y, Li J, Liu Y, Pereira B, Canavese F, Xu HW: Effect of age on radiographic outcomes of patients aged 6-24 months with developmental dysplasia of the hip treated by closed reduction. *J Pediatr Orthop B* 2020 Sep;29(5):431-437.
17. Mitani S, Nakatsuka Y, Akazawa H, Aoki K, Inoue H: Treatment of developmental dislocation of the hip in children after walking age. Indications from two-directional arthrography. *J Bone Joint Surg Br* 1997 Sep;79(5):710-8.
18. Morris WZ, Hinds S, Worrall H, Jo CH, Kim HKW: Secondary Surgery and Residual Dysplasia Following Late Closed or Open Reduction of Developmental Dysplasia of the Hip. *J Bone Joint Surg Am* 2021 Feb 3;103(3):235-242.
19. Murray T, Cooperman DR, Thompson GH, Ballock T: Closed reduction for treatment of development dysplasia of the hip in children. *Am J Orthop (Belle Mead NJ)*. 2007 Feb;36(2):82-4.
20. Pospischill R, Weninger J, Ganger R, Altenhuber J, Grill F: Does open reduction of the developmental dislocated hip increase the risk of osteonecrosis? *Clin Orthop Relat Res* 2012 Jan;470(1):250-60.

21. Ramo BA, De La Rocha A, Sucato DJ, Jo CH: A New Radiographic Classification System for Developmental Hip Dysplasia is Reliable and Predictive of Successful Closed Reduction and Late Pelvic Osteotomy. *J Pediatr Orthop* 2018 Jan;38(1):16-21.
22. Sankar WN, Gornitzky AL, Clarke NMP, Herrera-Soto JA, Kelley SP, Matheney T, Mulpuri K, Schaeffer EK, Upasani VV, Williams N, Price CT, International Hip Dysplasia Institute: Closed Reduction for Developmental Dysplasia of the Hip: Early-term Results From a Prospective, Multicenter Cohort. *J Pediatr Orthop* 2019 Mar;39(3):111-118.
23. Schoenecker PL, Dollard PA, Sheridan JJ, Strecker WB: Closed reduction of developmental dislocation of the hip in children older than 18 months. *J Pediatr Orthop* 1995 Nov-Dec;15(6):763-7.
24. Senaran H, Bowen JR, Härke HT: Avascular necrosis rate in early reduction after failed Pavlik harness treatment of developmental dysplasia of the hip. *J Pediatr Orthop* 2007 Mar;27(2):192-7.
25. Sucato DJ, De La Rocha A, Lau K, Ramo BA: Overhead Bryant's Traction Does Not Improve the Success of Closed Reduction or Limit AVN in Developmental Dysplasia of the Hip. *J Pediatr Orthop* 2017 Mar;37(2):e108-e113.
26. Talathi NS, Trionfo A, Patel NM, Upasani VV, Matheney T, Mulpuri K, Sankar WN: Should I Plan to Open? Predicting the Need for Open Reduction in the Treatment of Developmental Dysplasia of the Hip. *J Pediatr Orthop* 2020 May-Jun;40(5):e329-e334.
27. Tennant SJ, Eastwood DM, Calder P, Hashemi-Nejad A, Catterall A: A protocol for the use of closed reduction in children with developmental dysplasia of the hip incorporating open psoas and adductor releases and a short-leg cast: Mid-term outcomes in 113 hips. *Bone Joint J* 2016 Nov;98-B(11):1548-1553.
28. Tennant SJ, Hashemi-Nejad A, Calder P, Eastwood DM: Bilateral Developmental Dysplasia of the Hip: Does Closed Reduction Have a Role in Management? Outcome of Closed and Open Reduction in 92 Hips. *J Pediatr Orthop* 2019 Apr;39(4):e264-e271.
29. Terjesen T, Horn J: Management of late-detected DDH in children under three years of age: 49 children with follow-up to skeletal maturity. *Bone Jt Open* 2020 Oct 27;1(4):55-63.
30. Ucpunar H, Mert M, Camurcu Y, Sofu H, Yildirim T, Bayhan AI: Does Adductor Tenotomy Need During Closed Reduction Have a Prognostic Value in the Treatment of Developmental Dysplasia of the Hip Between 6 and 12 Months of Age? "Adductor Tenotomy in the Treatment of Developmental Dysplasia". *Indian J Orthop* 2020 Mar 9;54(4):486-494.
31. Yilar S, Köse M, Tuncer K, Karsan O, Topal M, Ezirmik N: Impact of presence of ossific nucleus on results of closed reduction in treatment of developmental dysplasia of the hip (302 hips). *J Pediatr Orthop B* 2021 Mar 1;30(2):126-131.
32. Yu J, Duan F, Guo W, Wang D, Qin X, Fu G, Chen T: Consistency of Indices Obtained via Hip Medial Ultrasound and Magnetic Resonance Imaging in Reduction and Spica Cast Treatment for Developmental Dysplasia of the Hip. *Ultrasound Med Biol* 2021 Jan;47(1):58-67.
33. Yuan Z, Li Y, Hong K, Wu J, Canavese F, Xu H: Poor delineation of labrum and acetabular surface on arthrogram is a predictor of early failure of closed reduction in children aged six to 24 months with developmental dysplasia of the hip. *J Child Orthop* 2020 Oct 1;14(5):372-378.
34. Zhang Z, Li H, Li H, Zhang Z: Timing for closed reduction procedure for developmental dysplasia of the hip and its failure analysis. *BMC Musculoskelet Disord* 2020 Sep 14;21(1):613.

Supplementary Table 3. Basic characteristics of analyzed groups

	Number of studies/cohorts	Number of patients (hips)	Average number of patients (hips)	Range number of patients (hips)	Age in months (range)	Follow up time (range)
Group 0-24	27	2.304 ¹ (2.955)	92 (109)	13-385 (17-440)	0-24	0 months-20.8 years ²
Group 0-36	34	2.839 ¹ (3.810)	92 (112)	15-385 (17-440)	0-36	0 months-27.7 years

¹In 4 studies [Mitani, Morris, Ramo, Terjesen], only the number of the hips (altogether 423) but not the patients were described in the investigated cohorts. The number of patients does not include these patients.

²20.8 years: age at final follow up

Supplementary Table 4. Potential risk factors for failure

Risk factor group	Number of potential risk factors ($\Sigma=71$)	Potential risk factors
Gender	2	male - female
Age	12	age at baseline exam, age at reduction, < 6 months, < 12 months, < 24 months, 6-12 months, 12-18 months, 18-24 months, 6-18 months, 12-24 months, 24-36 months, 6-24 months
Anamnesis	4	positive family history, breech presentation, swaddling, other foot disease or torticollis
Previous treatment	6	preoperative traction – no traction, previous brace treatment – no brace treatment, traction time, length of orthotic treatment
Laterality	6	unilateral – bilateral, left – right, bilateral – unilateral failure in bilateral dislocation
Clinical exam	5	preoperative hip abduction, first visit irreducible – reducible, preoperative irreducible - reducible
Ultrasound findings	7	less femoral head coverage, Harcke method, initial alfa angle - initial beta angle, Graf IIc, III, IV
X-ray finding	14	Tönnis grade II, III, IV IHDI grade II, III, IV FAZ zone I, II, III Grade II (mild), Grade III (severe) ossific nucleus present – absent, acetabular index
Soft tissue release	2	adductor tenotomy psoas release
Arthrogram findings	11	delineation of the labrum or acetabular surface at arthrogram, medial dye pool (MDP) distance/width of pool contrast, obstructive limbus, shape of limbus, cone stability, Tönnis grade, reduction grade, stability grade, medialization ratio, acetabular coverage, inverted labrum
Cast application	1	length of postreduction spica casting
Walking	1	walking ability