

## HIP

# Femoral bone defect classifications in revision total hip arthroplasty: a comprehensive review and proposal of a new algorithm of management

Mattia Loppini<sup>1,2,3</sup>, Francesco Manlio Gambaro<sup>1,2</sup>, Marco di Maio<sup>4</sup> and Guido Grappiolo<sup>2,3</sup>

<sup>1</sup>Department of Biomedical Sciences, Humanitas University, Via Rita Levi Montalcini 4, Pieve Emanuele, Milan, Italy

<sup>2</sup>IRCCS Humanitas Research Hospital, Via Manzoni 56, Rozzano, Milan, Italy

<sup>3</sup>Fondazione Livio Sciuotto Onlus, Campus Savona - Università degli Studi di Genova, Via Magliotto 2, Savona, Italy

<sup>4</sup>Università degli Studi di Trieste, Piazzale Europa 1, Trieste, Italy

Correspondence should be addressed to M Loppini Email [mattia.loppini@hunimed.eu](mailto:mattia.loppini@hunimed.eu)

- The number of primary total hip arthroplasties (THAs) and revisions is expected to steadily grow in the future. The femoral revision surgery can be technically demanding whether severe bone defects need to be addressed.
- The femoral revision aims to obtain a proper primary stability of the stem with a more proximal fixation as possible. Several authors previously proposed classification systems to describe the morphology of the bony femoral defect and to drive accordingly the surgeon in the revision procedure.
- The previous classifications mainly considered cortical and medullary bone at the level of the defect of poor quality by definition. Therefore, the surgical strategies aimed to achieve a distal fixation bypassing the defect or to fill the defect with bone impaction grafting or structured bone grafts up to the replacement of the proximal femur with megaprosthesis.
- The consensus on a comprehensive and reliable classification system and management algorithm is still lacking. A new classification system should be developed taking into account the bone quality. The rationale of a new classification is that 'functional' residual bone stock could be present at the level of the defect. Therefore, it can be used to achieve a primary (mechanical) and secondary (biological) stability of the implants with a femoral fixation more proximal as possible.

Keywords: bone defect; classification; femur

## Introduction

In industrialized countries, the increased life expectancy and aging population results in the increased use of total hip replacement (THA). In the United States, the number of primary THA has been expected to increase by 174% from 2005 to 2030 (1). Because of the significant increase of primary procedures, the number of THA revision procedures are also expected to steadily grow in the future (2).

The revision surgery can be technically demanding whether severe bone defects need to be addressed.

Although more severe bone loss patterns have variable amounts of diaphysis remaining, the femoral revision aims to obtain a proper primary stability of the stem with a more proximal fixation as possible to preserve and if possible to restore the bone stock (3, 4).

During the past decades, the development of classification systems to describe the femoral defects has been the subject of increasing interest. The first classification was developed by Gross *et al.* (5) in the 1985 focusing on the patterns of THA failure.

Afterward, several authors proposed classification systems to describe the morphology of the bony defect and an algorithmic approach to drive accordingly the surgeon in the revision procedure. Therefore, many different surgical strategies have been proposed such as stem with proximal press-fit or extended porous coating (6), monoblock or modular conical stem (7, 8), stem combined with bone grafts (9), cemented stem, bone impaction grafting technique, and megaprosthesis (10, 11). Nevertheless, a consensus on a comprehensive and reliable approach is still lacking (12, 13, 14, 15). The aim of the present study is to provide a comprehensive overview of the available classification systems of femoral bone defects associated with THA and to propose a new algorithm for the management of these patients.

## Methods

A comprehensive search of PubMed, Medline, CINAHL, Cochrane, Embase, and Google Scholar was performed, using various combinations of the following keywords: 'femoral classification' in combination with 'bone loss', 'defect', 'revision', 'total hip arthroplasty', 'cementless,' and 'cemented.'

All peer-reviewed journals were considered and all articles reporting classification systems of femoral bone defects associated with THA were analyzed. Cross-reference research of the selected articles was also performed to obtain other relevant articles for the study. The classifications describing both acetabular and femoral defects were reported only regarding the femoral part. On the new classification proposed by the authors, the inter- and intra-observer reliability using weighted kappa coefficients was determined by two separated orthopedic surgeons in two separate occasions at 2 weeks' distance (occasion 1 and occasion 2). The extent of agreement was interpreted using the criteria described by Landis & Koch (16), such that a score greater than 0.80 indicated excellent agreement from 0.61 to 0.80 good agreement, from 0.41 to 0.60 moderate agreement, from 0.21 to 0.40 fair agreement, and 0.20 or less poor agreement.

## Results

### Gross classification (1985)

The first description of femoral defects by Gross *et al.* included only two categories: the calcar and the proximal femoral defect. The proposed management of both lesions included the use of allografts (17, 18). Subsequently, a new version has been proposed distinguishing the defect in intraluminal and cortical (5) (Table 1). The intraluminal defect was characterized by an intact cortex which is supportive enough to allow the insertion of the implant. The cortical defect can be non-circumferential or circumferential and requires the use of allografts.

A modified version of Gross classification (15) (Table 2) has been suggested by other authors evaluating the localization and extension of the defect in five different types of bony lesion. The extension of the defect in the axial plane was described as intraluminal, cortical, or circumferential. The longitudinal length of the defect was expressed as more or less than 5 cm extending distally from the lesser trochanter. The periprosthetic fracture associated with the bony defect characterized the most severe lesion (type V). The modified Gross classification (15) demonstrated very good intra-observer reliability ( $K=0.75$ ) and validity ( $K=0.75$ ).

### Gustilo and Pasternak classification (1988)

The Gustilo and Pasternak classification (18) was developed to evaluate failed cemented stems (Table 3) including four categories based to the extent of the defect. The type I was characterized by a minimal endosteal or inner cortical bone loss. The type II delineated a proximal canal enlargement with an intact circumferential wall. In the most severe cases, the defect involved the lesser trochanter (type III) or it determined a total proximal circumferential loss below the lesser trochanter (type IV). The authors suggested a management mainly based on cementless stems eventually associated to bone grafts.

**Table 1** Gross classification.

Type	Description of the defect	Management
Intraluminal	Intact cortex with widened canal	The same for primary replacement
Cortical non-circumferential	Cortex with some damage, widened canal may be present	Strut allograft
Cortical circumferential	A) Calcar, <3 cm in length distal to the lesser trochanter B) Proximal femur, >3 cm in length distal to the lesser trochanter	Proximal femoral allograft

**Table 2** Modified Gross classification.

Type	Description of the defect	Management
I	No significant bone loss	The same for primary replacement
II	Intraluminal bone loss with the majority of bone stock still available	Proximal or distal cementless fixation, or cemented fixation with a long stem
III	Cortical defects either non-circumferential or circumferential, extending for <5 cm in length distal to the lesser trochanter	Cortical strut allograft or calcar-replacing implant
IV	Circumferential loss of the entire proximal femur extending for >5 cm in length distal to the lesser trochanter	Proximal femoral allograft or proximal femoral replacement
V	Type IV criteria + sustained periprosthetic fracture	Proximal femoral allograft or proximal femoral replacement

### Endo-Klinik classification (1988)

The Endo-Klinik classification evaluated the femoral bony defects associated with cemented stems (19) and demonstrated an excellent intra-observer ( $K=0.83$ ) and inter-observer ( $K=0.84$ ) agreement (20).

The classification focused on the location and the proximal to distal extension of radiolucent lines taking into account the involvement of femoral isthmus considered a critical anatomical structure to obtain a proper distal fixation (Table 4). In type I defects, the authors suggested to perform femoral osteotomies to prevent fractures during the removal of fixed femoral stems. In type II defects, they proposed to fill large defects with fracture plates embedded in the cement ('reinforced concrete' technique) and to use standard or long cemented stems basing on the extension of the femoral defect. In type III defects, several strategies have been suggested from long cemented stems to combined constructs including bone grafts, cement embedded hardware, and revision prostheses. The type IV defect was managed with total femoral replacement or resection arthroplasty.

### Mallory classification (1988)

The Mallory classification (21) described the proximal femoral defects in cemented stems (Table 5) evaluating the type of the bone affected (cortical and/or cancellous) and the longitudinal extension of the lesion. The authors identified three different zones according to anatomical bony landmarks: zone 1, proximal to lesser trochanter; zone 2, between lesser trochanter and femoral isthmus; and zone 3, distal to the isthmus. The management was

based on the residual bone stock, with a preference for the long cementless stems to obtain a distal fixation. The optional use of proximal allografts has been also considered if the proximal part did not provide the required support for the new implant.

### Engel classification (1988)

The Engel classification (22) provided a qualitative description of the defect including three main patterns: minimal, moderate, and severe damage (Table 6). The proximal bone deficiency affecting the femoral neck and metaphysis corresponded to a moderate damage, whereas the distal deficiency involving both femoral metaphysis and diaphysis characterized the severe damage.

The most common defects were represented by moderate-to-severe bone loss (types II and III) characterized by the irreversible sclerosis with loss of osteogenic potential of the femoral cortical bone. The authors suggested the use of stem with proximal or full porous coating instead of cemented stems to achieve a stable primary implant fixation. Whether distal fixation was not possible, the use of large implants to replace the portion of bone loss, bipolar components, and total acetabular allograft has been proposed.

### Chandler and Penenberg classification (1989)

The Chandler and Penenberg classification (23) described the femoral bony defect evaluating the location and the extension of the lesion, and the type of bone involved (Table 7). In the types I and II, the location was defined by anatomical structures such

**Table 3** Gustilo and Pasternak classification.

Type	Description of the defect	Management
I	Minimal endosteal or inner cortical bone loss, loosening from the cement-metal-bone interface or broken prosthesis	Cementless stem; cemented stem in patient >65 years
II	Proximal canal enlargement with cortical thinning $\geq 50\%$ of the width; eventual lateral wall defect with an intact circumferential wall	Cementless stem with bone grafting
III	Posteromedial wall defect involving the lesser trochanter	Cementless stem with bone grafting
IV	Total proximal circumferential loss distal to the lesser trochanter	Cementless stem with bone grafting

**Table 4** Endo-Klinik classification.

Type	Description of the defect	Management
I	Radiolucent lines surrounding proximal half of the cement mantle	Fixed component must be replaced; ventral or dorsal osteotomy cannot be avoided due to the risk of fractures
II	Diffuse radiolucent areas surrounding the cement mantle, endosteal destruction of the proximal femoral metaphysis, widening of the medullary canal	The 'reinforced concrete' technique; if other defects are present they are covered through the implant or filled with cement
III	Ectasia of the proximal femur with widening of the medullary canal, proximal bone loss	Long cemented stem; cement composite, steep prosthesis and autologous cancellous graft; combined massive bone transplant or corticospongyous graft with acetabular screws and/or femoral cerclages embedded in cement and revision prosthesis
IV	Destruction of the proximal one third of the femur, involvement of the middle third, damage of the distal third, resulting in loss of support, even in long stems	Total femoral replacement or resection arthroplasty

as the calcar and greater trochanter. In the types III, IV, and VI, the general features of cortical thinning, cortical perforation, and circumferential deficiencies were taken into account. The type V was characterized by the presence or not of periprosthetic fractures. The authors identified different causes for each of the six types: stress shielding for types I and II, stem loosening for type III, stem drifting to varus for type IV, host bone fractures for type VA, or previous allograft-prosthetic composite fracture for type VB. The authors proposed three main therapeutic strategies: the strut or napkin-ring allografts for all types of defect except for the type VI, the allografts and/or long stems for the type VI, and internal plates and screws for bone fixation in allograft fractures.

### American Academy of Orthopaedic Surgeons classification (1993)

The American Academy of Orthopaedic Surgeons (AAOS) classification was characterized by a three-step assessment of the bony defect including both preoperative and intraoperative findings (Table 8) (24). It demonstrated an excellent intra-observer ( $K=0.81$ ) and a very good inter-observer ( $K=0.65$ ) agreement (19).

The first step was focused on the evaluation of the morphology of the defect and the shape of the femur describing six categories: segmental, cavitory, combined (segmental and cavitory), malalignment,

femoral stenosis, and femoral discontinuity or femoral fractures. The segmental defect was defined as any loss of bone in the cortices; the cavitory defect was characterized by a medullary-contained lesion or also an ectasia, if thinning of the diaphyseal cortex is present. The femoral malalignment is characterized by a rotational or angular distortion of the diaphysis. The femoral stenosis was defined as the narrowing of the femoral canal. The femoral discontinuity described the lack of bony integrity resulting from a femoral fracture regardless the presence of the implant. The second step focused on the defect extension distinguishing three levels: level I, proximal to the inferior portion of the lesser trochanter; level II, up to 10 cm from the lesser trochanter; and level III, more than 10 cm from the lesser trochanter. Finally, the third step focused on the intraoperative findings according with the degree of prosthesis–bone contact.

The three-step evaluation could provide a standard classification system to describe preoperatively the defect and to report the result of the surgical reconstruction. Basing on the current state of art procedures, the author suggested different surgical strategies from bone grafting to cementless stems.

### Paprosky classification (1993)

The Paprosky classification (25, 26, 27, 28) has been developed for the assessment of preoperative

**Table 5** Mallory classification.

Type	Description of the defect	Management
I	Normal medullary canal and intact cortex	The same for primary replacement
II	Intact cortices but loss of cancellous bone in the medullary canal	Cementless long stem; additional support was provided with either allograft or proximal femoral replacing techniques
III	Defects in both medullary canal and cortex A) Cortical and cancellous deficiency proximal to lesser trochanter B) Cortical and cancellous deficiency between lesser trochanter and isthmus of the femur C) Cortical and cancellous deficiency distal to the isthmus	Cementless long stem; additional support was provided with either allograft or proximal femoral replacing techniques

**Table 6** Engh classification.

Type	Description of the defect	Management
I	Minimal or no damage	Proximal porous-coated stem
II	Moderate damage, bone deficiency in the neck and intertrochanteric region, support is provided by diaphysis	Proximal porous-coated stem with press-fit at the femoral isthmus
III	Severe bone loss in the metaphysis and diaphysis	Fully porous-coated stem, corrective osteotomy if necessary; if distal fixation is not possible, large implant replacing a bone portion, bipolar components or total acetabular allograft

radiographs to classify the location and the extent of femoral bone loss (Table 9 and 10).

The classification evaluated the type of bone affected (cancellous and cortical) and the involved portion of the femur (metaphysis and diaphysis). In the most severe cases, characterized by diaphyseal bone defect, the authors focused on the integrity of the isthmus to achieve or not 4 cm scratch fit (Table 10). For each type of the defect type defined, the authors reported the most common etiology. The type I defect resulted by the removal of a cementless femoral component without a biological ingrowth surface. The type II defect occurred after the removal of a cemented or cementless femoral component, in the earlier stages of loosening. The type IIIA defect was commonly seen after the removal of a grossly loose femoral component that was inserted with first-generation cementing techniques. The type IIIB defect often resulted by the failure of a cemented femoral component that was inserted with a cement restrictor or a cementless femoral component that was associated with substantial distal osteolysis. No specific causes have been described for the type IV defect.

The management of type I defect was the same for primary replacement with the use of cemented or cementless stems. In type II and III defects, the authors suggested to achieve a diaphyseal fixation with proximally or fully porous-coated cementless stems. The most severe cases were characterized by a non-supportive isthmus with unavailable 4 cm scratch fit. Therefore, the authors proposed the use of modular, tapered, cementless stems or impaction bone grafting or femoral allograft–prosthesis composite. For selected patients, such as elderly or patients with low physical demand, a long femoral cemented or uncemented component or a proximal femoral replacing prosthesis can be used. Finally, the authors recommended the use of the extended trochanteric osteotomy for the removal of a well-fixed cemented or cementless stem. This procedure can also facilitate the insertion of revision stems in the presence of complicated femoral deformities.

Käfer *et al.* (29) demonstrated that the classification does not provide a valid and reliable assessment of femoral bone stock loss, showing an inter-observer reliability

**Table 7** Chandler and Penenberg classification.

Type	Description of the defect	Management
I	Loss of calcar bone A) Intramedullary or cancellous bone loss B) Complete loss of the calcar region	Strut or napkin-ring allograft, if needed iliac crest graft. Failed implants are revised with cementless stem
II	Greater trochanter deficiency	Strut or napkin-ring allograft, if needed iliac crest graft. Failed implants are revised with cementless stem
III	Cortical thinning	Strut or napkin-ring allograft, if needed iliac crest graft. Failed implants are revised with cementless stem
IV	Cortex perforation	Strut or napkin-ring allograft, if needed iliac crest graft. Failed implants are revised with cementless stem
V	Peri-prosthetic fractures A) Fractures of native femur B) Allograft fractures	Strut or napkin-ring allograft, if needed iliac crest graft. Failed implants are revised with cementless stem Strut or napkin-ring allograft, if needed iliac crest graft. Failed implants are revised with cementless stem Supported with internal plates and screws
VI	Circumferential deficiency of the metaphysis and proximal diaphysis deficiency A) Absence of trochanter and metaphysis with intact diaphyseal shell B) Total loss of entire proximal femur	Proximal femoral allograft and one of - Long-stem cementless prosthesis; - Allograft internal fixation and a standard stem



**Table 8** American Academy of Orthopaedic Surgeons (AAOS) classification.

	Description of the defect	Management
Step 1	Thickness or depth of bone loss	Several options from bone grafting to cementless stem
Type I	Segmental lesions	
Type II	Cavitary lesions	
Type III	Combined	
Type IV	Femoral malalignment	
Type V	Stenotic femoral canals	
Type VI	Femoral discontinuity or fractures	
Step 2	Vertical evaluation	Several options from bone grafting to cementless stem
Level 1	Defects ends at the inferior level of the lesser trochanter	
Level 2	<10 cm distal to the lesser trochanter	
Level 3	>10 cm distal to the lesser trochanter	
Step 3	Grading bone integrity at surgery	Several options from bone grafting to cementless stem
Grade I	Complete prosthesis–bone contact	
Grade II	Stable fixation but partial prosthesis–bone contact	
Grade III	Unstable, required onlay allograft	

of  $r_s = 0.45$ – $0.67$  and  $r_s = 0.59$ – $0.68$  in the preoperative and intraoperative setting respectively. The authors also reported that the defects were grossly underestimated preoperatively and the level of experience did not influence the validity of measurements. On the other hand, Parry *et al.* (19) demonstrated a very good intra-observer ( $K=0.77$ ) and inter-observer ( $K=0.71$ ) agreement.

### Deutschen Gesellschaft für Orthopädie und Traumatologie classification (1997)

The Deutschen Gesellschaft für Orthopädie und Traumatologie (DGOT) classification (30) focused on the type of bone involved (cancellous and cortical)

and the proximal-to-distal extension of the lesion (intramedullary, trochanteric, calcar, metaphysis, diaphysis) (Table 11). No management has been included. Käfer *et al.* (29) reported that the classification provides a poor reliable assessment of femoral bone stock loss, showing an inter-observer reliability of  $r_s = 0.38$ – $0.59$  and  $r_s = 0.44$ – $0.60$  in the preoperative and intraoperative setting, respectively.

### Modified Mallory classification (1999)

The modified Mallory classification (31) (Table 12) focused on the type of bone involved (cancellous and cortical) and the proximal-to-distal extension of the lesion (metaphysis and diaphysis). Moreover, the authors described the quality of the remaining bone

**Table 9** Paprosky classification (first version).

Type	Description of the defect	Management
I	Minimal diaphyseal-metaphyseal bone loss	No grafting required; cemented or proximally porous-coated cementless stem
II	Calcar absent with intact diaphysis, the damage is confined into the metaphysis	Extensively porous-coated cementless stem; cemented stem should be avoided because of the loss of metaphyseal endosteal bone
	A) Calcar defect just below inter-trochanteric line	Napkin-ring allograft to the calcar
	B) A + anterolateral metaphyseal bone loss	Strut allograft
	C) A + posteromedial metaphyseal bone loss	Strut allograft
III	Meta-diaphyseal defects	
	A) IIA + diaphyseal bone loss	Strut allograft; extensively porous-coated stem or modular distal fitting tapered stem with 4 cm scratch fit at the isthmus
	B) IIB + diaphyseal damage	Strut allograft; modular-tapered cementless stem with distal scratch fit
	C) IIC + deficient diaphysis	Strut allograft
IV	Extensive metaphyseal loss	Impaction bone grafting with tapered cemented stem if intact cortex; composite prosthesis allograft if no proximal cortex; long cemented stem is an option in elderly

**Table 10** Reviewed Paprosky classification.

Type	Description of the defect	Management
I	Minimal metaphyseal-diaphyseal cancellous bone loss	Cemented or cementless stem
II	Extensive loss of metaphyseal cancellous bone with an intact diaphysis	Proximally porous-coated cementless stem with diaphyseal fixation or extensively porous-coated stem. If significant femoral remodeling, extended trochanteric osteotomy plus a diaphyseal fitting implant is suggested
III A	Non-supportive and severely damaged metaphysis with >4 cm of diaphyseal bone available for distal fixation	Extensively porous-coated stem with diaphyseal fixation Additional options include impaction bone grafting, tapered cementless stem
III B	Non-supportive and severely damaged metaphysis with <4 cm of diaphyseal bone available for distal fixation	Modular, tapered, cementless stem, or impaction bone grafting
IV	Extensive metaphyseal and diaphyseal damage in conjunction with a widened femoral canal. The isthmus is non-supportive so that distal fixation cannot be achieved	Impaction bone grafting, femoral allograft-prosthesis composite with the three-point fixation or alternatively with cemented technique. If elderly or low physical demand, long cemented/ cementless stem, or proximal femoral replacing prosthesis

reporting the ability or not to support the femoral implant. In type II defect, the metaphyseal support is intact but compromised, whereas the metaphysis is not supportive in type III defect. Finally, the type IV defect is characterized by the involvement of the diaphysis with a non-supportive isthmus. The proposed management ranges from primary implants to impaction bone grafting or fully porous-coated stems or cemented stems combined with structural femoral allograft for proximal reconstruction.

### Italian Society for Revision Arthroplasty classification (2000)

The Italian Society for Revision Arthroplasty (GIR) classification has been developed to correlate the femoral bone defects with surgical strategies for the reconstruction (32) (Table 13). A new concept introduced by this classification was the dynamic grading of the defect. Because the bone is continuously reshaping,

emphasizing the possible evolution not only overtime but even intra-operatively of the defect, the authors decided to not distinguish bone loss into types but they used different grades to describe the evolution of the defect.

The classification assessed quality, extension, and location of the defect, distinguishing between medullary loss and cortical thinning. The description of the lesion aimed to identify the ability of the remaining bone to support femoral implant. In grades I and II, the bone allows the proximal fixation through larger and longer stems. In grades III and IV, the distal fixation and bone reconstruction represent the management of choice.

### Saleh classification (2001)

The Saleh classification (33) (Table 14) focused on the extension of the lesion in both axial and longitudinal axes. In terms of the axial extension, the authors distinguished between non-circumferential and circumferential lesion; in terms of the longitudinal

**Table 11** Deutschen Gesellschaft für Orthopädie und Traumatologie (DGOT) classification.

Type	Position	Description of the defect
I	Intramedullary	Loss of the normal cancellous bone in the medullary canal. Femoral metaphysis and the isthmus are intact
II	Trochanteric	Defect in the intertrochanteric area especially in the greater trochanter. The femoral metaphysis is proximally enlarged with thinning of the cortical bone. The calcar area is not damaged
III	Calcar	Evident reabsorption and thinning of proximal femoral cortical bone, involving also the lesser trochanter
IV	Medial shaft	The defect is the same of type III but distal to the lesser trochanter. This defect is due to valgus deformity of prosthesis
V	Lateral shaft	The bone defect is mainly on the lateral cortical bone. It extends distally over the greater trochanter and lies below the lesser trochanter. This defect is due to varus deformity of prosthesis
VI	Diaphyseal – partial	The bone defect is circular or segmental involving the cortical bone distal to lesser trochanter. It may involve also the proximal part
VII	Diaphyseal – total	The bone defect is circular or segmental in which two-thirds of the femur is destroyed. Almost the entire diaphyseal femur is missing

**Table 12** Modified Mallory classification.

Type	Description of the defect	Management
I	Intact cancellous and cortical bone, intact metaphyseal cortical support	The same for primary replacement
II	Intact cortices but loss of cancellous bone in the medullary canal. May be present distal cortical thinning. Metaphyseal support is intact but compromised	Fully porous-coated stem, impaction bone grafting
III	Cancellous and cortical bones are deficient. Extensive cavitation or cortical perforation. No metaphyseal support	Fully porous-coated stem with 4–6 cm scratch fit distal fixation
IV	Absent cancellous and cortical bone. Segmental structural bone loss of metaphysis and isthmus	Fully porous-coated stem or cemented stem (if 4–6 cm scratch fit distal fixation is unavailable) combined with structural femoral allograft for proximal reconstruction. Cementation between allograft and whatever used stem is recommended

extension, they distinguished between lesions involving the femoral diaphysis more or less 5 cm distal to the lesser trochanter. According with the severity of the defect, the management included since cemented and uncemented stems as in primary THA to porous-coated stems, modular stems, impaction bone grafting, and custom implants. This classification demonstrated an excellent inter-observer reliability ( $K=0.88$ ) (34).

### Parry classification (2010)

The Parry classification (19) (Table 15) focused on the femoral region involved (metaphysis and diaphysis) and the continuity of the supporting structures. The authors distinguished between contained and uncontained defect, both potentially occurring in metaphysis or diaphysis. The main surgical strategies included implants with distal fixation to bypass the defect and bone grafts. This classification demonstrated an excellent intra-observer agreement ( $K=0.87$ ) and a good inter-observer agreement ( $K=0.59$ ).

### Functional bone stock classification

The functional bone stock classification (FBSC) is a new classification proposed by the authors (Table 16) that

subdivides femoral bone defects in three stages based on two different features: the 'functional' residual bone stock and the extension of the defect. The 'functional' residual bone stock has been defined as the remaining cortical and medullary femoral bone available to obtain a primary press-fit fixation of the stem and a secondary biological fixation by the osteointegration. The quantitative assessment of the bone stock was performed with the cortico-femoral index (CFI), which is defined as the ratio of the femoral diaphyseal diameter minus the intramedullary canal diameter to the femoral diaphyseal diameter (35) (Fig. 1). The 'functional' residual bone stock is characterized by a CFI  $\geq 0.5$  since the average healthy CFI is  $\geq 0.5$  (36). Indeed Nguyen *et al.* (36) found a correlation between the decrease in CFI below 0.5 and a decrease in bone mineral density and the fracture risk assessment tool. In terms of the extension of the lesion, the authors distinguished in minimal proximal defects, and medium-to-very large defects localized within or over 150 mm from the apex of the great trochanter with subsequent impairment of the femoral isthmus.

In the management algorithm, the authors also considered the use of trochanteric osteotomy (short or extensive) as technique to remove the stem and also to preserve the residual trochanteric bone stock.

**Table 13** Italian Society for Revision Arthroplasty (GIR) classification.

Grade	Description of the defect	Management
I	Cavitory loss, enlargement of the proximal canal, and thinning of the cortical wall, without disruption	Larger and longer stem, cemented or cementless, eventually combined with impacted morselized graft, cerclage wires if needed
II	Proximal canal enlargement and cortical thinning, resorption of one of the cortical walls (segmental loss at the medial wall and calcar)	Proximal fixed stem cemented or cementless, minor structural bone grafts
III	Canal ectasia, proximal cortical thinning, and disruption in two or more cortical walls, unable to contain and stabilize a stem	Cementless anatomic-bowed long stem distally fixed with modular sleeve to fill the proximal canal. Additional options include revision modular stem distally fixed, and proximal structural graft
IV	Extensive, proximal circumferential bone loss	Resection prosthesis or cementless monoblock or modular long stem with massive structural allograft



**Table 14** Saleh classification.

Type	Description of the defect	Management
I	No significant bone loss	Conventional cemented/cementless stem
II	Contained bone loss, cortical sleeve intact	Proximal fixation, impaction grafting, porous-coated implant, modular implant
III	Uncontained non-circumferential loss of bone stock	Cortical strut allograft, calcar replacing prosthesis
IV	Circumferential loss of bone stock >5 cm in length distal to the lesser trochanter	Custom implant, tumor implant, or proximal femoral allograft
V	Periprosthetic fracture with proximal circumferential loss of bone stock	Restoration of bone stock plus long-stem femoral component custom implant, tumor implant, or proximal femoral allograft

The stage 1 is characterized by good quality of the bone, absent or minimal bone defect with proximal localization, and a possible economic removal of the stem. The revision can be performed with cementless stem with rectangular or conical section. Small bone defects can be filled with autologous or synthetic bone transplants. In patients with previous cemented stem with a continuous and stable mantle, the 'cement-within-cement' technique (34) can be performed.

The stage 2 is characterized by poor quality of the bone, cavitary or segmentary bone defect with medium-to-large size, localized within 150 mm from the apex of the great trochanter. Therefore, with a CFI at 150 mm  $\geq 0.5$  (Fig. 1A). The removal of the stem is not simple with consequent but limited provoked bone defect. In this stage, the residual functional bone stock still remains at less than 150 mm from the apex of the great trochanter without impairment of the anatomical femoral isthmus. For this reason, an eventual trochanteric osteotomy should not be extensive. The revision can be performed with a monoblock straight stem with length less than 250 mm (Wagner Cone and Wagner SL 190 and 225). The Wagner Cone and Wagner SL stems are cylindrical implants with diaphyseal fixation, respectively proximal and distal, with longitudinal fins providing the rotational stability. Whether a significant thinning of the cortices with a widening of the femoral canal occurs, the proximal diaphyseal fixation of conical stems cannot be obtained. However, a proximal primary fixation is still possible basing on the functional residual bone stock. Therefore, porous modular stems shorter than 250 mm allow to obtain a diaphyseal press-fit combining a distal component of larger diameter with an appropriate

proximal component for the reconstruction of the correct length and offset.

The stage 3 is characterized by poor quality of the bone, extended cavitary or segmentary bone defect, localized more than 150 mm from the apex of greater trochanter. Therefore, with a CFI at 150 mm  $< 0.5$  (Fig. 1B). The removal of the stem is probably difficult and destructive. In this stage, the femoral isthmus is partially or completely non-supportive and the residual functional bone stock is localized distally at more than 150 mm from the apex of the greater trochanter. Therefore, the trochanteric osteotomy should be extended, if required. The revision can be performed with monoblock cylindrical stems (e.g. Wagner), straight or curved modular stems, with or without the locking system longer than 250 mm. The choice between the different types of stem depends on the type of filling needed for the cavity, because they have taper of different degrees. The modular cementless, conical, distal fixating, porous titanium stems have a more conical distal geometry than the Wagner stem, which allows the isthmus to be engaged more effectively providing stability of the stem also with a diaphyseal contact of 2–3 cm. The curved stems aim to maximize the cortical contact and primary stability following the native femoral shape. Finally, the stems with locking systems can be useful if it is not possible to obtain the primary stability by press-fit. In any case, the secondary biological stability is obtained through the osteointegration of the porous surface.

The inter-reliability evaluation between the two orthopedic surgeons expressed as kappa coefficient was 0.504 on occasion 1 and on occasion 2, 2 weeks later 0.694. Instead the intra-reliability evaluation

**Table 15** Parry classification.

Type	Description of the defect	Management
A	Contained defect with minimal bone stock loss	The same for primary replacement
B1	Contained defect with significant bone stock loss in metaphysis	Graft
B2	Contained defect with significant bone stock loss in diaphysis	Graft and bypass
C1	Uncontained defect with significant bone stock loss in metaphysis	Contain and graft
C2	Uncontained defect with significant bone stock loss in diaphysis	Contain, graft, and bypass

**Table 16** The Functional Bone Stock Classification (FBSC).

Defect type	Description of the defect	Management
Stage I – minimal/absent		No osteotomy required Cementless stem or cement-within-cement technique
Stage II – moderate	'Functional' (CFI $\geq 0.5$ ) residual bone stock <150 mm from the apex of the greater trochanter Preserved femoral isthmus	Short trochanteric osteotomy may be required  Cementless cylindrical monoblock or porous modular stem <250 mm
Stage III – severe	Severe defect 'Functional' (CFI < 0.5) residual bone stock >150 mm from the apex of the greater trochanter Partially or completely compromised femoral isthmus	Extended trochanteric osteotomy may be required Cementless cylindrical monoblock stem >250 mm, if 4 cm scratch fit available at the isthmus  Porous straight or curved modular stem >250 mm, if <4 cm scratch fit available at the isthmus Locked stem if press fit is not available

CFI, cortico-femoral index.

between occasion 1 and occasion 2 was 0.84 in the first orthopedic surgeon and 0.64 in the second one.

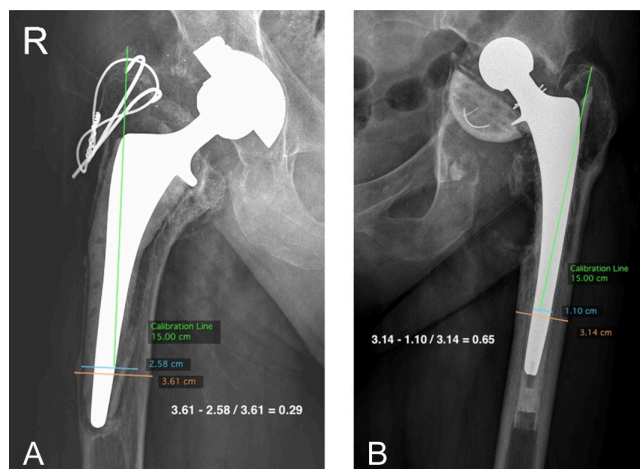
## Discussion

Several classification systems have been proposed overtime to describe the morphology of the femoral bone defect and to drive accordingly the surgeon in the revision procedure. Each of them described the defect focusing on specific variables, and if the same variables were taken into account, different methods were used for the evaluation (Table 17). For this reason, a direct comparison of these classifications systems becomes difficult.

The location of the defect in the femur was reported in all classifications, whereas a proper evaluation of its extension is lacking in the Engh (22), Paprosky (25, 26,

27, 28), and modified Mallory (21) classifications. The quality of the remaining bone was variably described in terms of supportive or non-supportive bone for the new implant in the Endo-Klinik (19), Mallory (32), Engh (22), Paprosky (25, 26, 27, 28), modified Mallory (31), and GIR (32) classifications. All these authors assumed that the quality of the bone at the level of the defect was poor by definition. In this respect, they mainly proposed strategies to achieve a distal fixation bypassing the defect or to fill the defect with bone impaction grafting or structured bone grafts up to the replacement of the proximal femur with large implants. The FBSC is based on the 'functional' residual bone stock assuming that medullary and cortical bone at the level of the defect is still useful to achieve a primary other than a secondary stability with the use of cementless implants. For this reason, the management of femoral bone defects should be based on the quality of the bone. In the FBSC, the extension of the defect does not refer to the anatomical-pathological lesion but to the bone tissue deemed non-functional as described previously (CFI <0.5). At the time of the revision, there is a certain proportion of proximal cortical and medullary bone that is not involved in the primary distal fixation in the femur. However, if this bone tissue is spared, it can subsequently regenerate providing a more extensive secondary fixation based on the osteointegration of both distal and proximal portions of the femur.

The assessment of the great trochanter region represents another critical issue influencing the surgical strategy, because of the insertion of the gluteal muscles. At the time of the revision, the trochanteric mass can present a significant bone resorption because of the stress shielding phenomena and/or the debris released by the prosthesis. According to the fragility of the greater trochanter, it may be recommended to perform a trochanteric osteotomy to preserve the residual trochanteric bone stock and the muscular insertions. Among the previous authors, the great trochanter has been taken into account in the Chandler

**Figure 1**

A: Stage 3 according to the FBSC, characterized by CFI: 0.29. B: Stage 2 according to the FBSC, characterized by CFI: 0.65.

**Table 17** Description of the variables considered in the different classification systems.

Classification	DE	DL	BT	FO	GTE	FIE	CLF	QD	OR, K values	
									Intra	Inter
Gross	Yes	Yes	Yes	No	No	No	No	No	0.75	No
Gustilo and Pasternak	Yes	Yes	Yes	No	No	No	No	No	No	No
Endo-Klinik	Yes	Yes	Yes	Yes	No	Yes	No	Yes	0.83	0.84
Mallory	Yes	Yes	Yes	No	No	Yes	No	Yes	No	No
Engl	No	Yes	No	Yes	No	Yes	No	Yes	No	No
Chandler and Penenberg	Yes	Yes	Yes	No	Yes	No	No	No	No	No
AAOS	Yes	Yes	No	No	No	No	No	No	0.81	0.65 (23)
Paprosky	No	Yes	Yes	Yes	Yes	Yes	Yes	No	0.77	0.71
DGOT	Yes	Yes	Yes	No	Yes	Yes	No	No	0.52*	No
Modified Mallory	No	Yes	Yes	No	No	Yes	Yes	Yes	No	No
GIR	Yes	Yes	Yes	No	No	No	No	Yes	No	No
Saleh	Yes	Yes	No	No	No	No	No	No	0.39	0.56
Parry	Yes	Yes	No	No	No	Yes	No	No	0.87	0.59
FBSC	Yes	Yes	No	Yes	Yes	Yes	Yes	Yes	0.74	0.69

\* $r_s$  value.

BT, bone type (medullary or cortical); CLF, contact length for fixation in bone prosthesis; DE, defect extension; DL, defect location; FIE, femoral isthmus evaluation; FO, femoral osteotomy; GTE, greater trochanter evaluation; OR, observer reliability; QD, quality of the defect.

and Penenberg (23), Paprosky (25, 26, 27, 28), and DGOT (30) classifications. In the FBSC, the involvement of the trochanteric region has been also considered evaluating the proximal-to-distal extension of the defect since the apex of the great trochanter.

The femoral osteotomy is another factor influencing the surgical revision strategy. It can be required to preserve the great trochanter, to perform a realignment of the femur, or to remove cementless stem or endocanal cement or endosteal reactive pedestals. Among the previous authors, this procedure has been considered in the Endo-Klinik (19), Engl (22), and Paprosky (25, 26, 27, 28) classifications. In the FBSC, the authors distinguished between short and extended trochanteric osteotomy respectively used in moderate (Stage II) and severe (Stage III) defects. The short trochanteric osteotomy allows the use of stems within 225 mm in length because the portion of the diaphysis between the osteotomy and the femoral procurvation is sufficient to obtain a primary fixation of the stem. On the other hand, the extended trochanteric osteotomy interrupts the procurvation of the femur affecting its support for the primary fixation. Therefore, stems longer than 225 mm are required to obtain the distal fixation at the femoral isthmus. In the authors' experience, the length of the distal contact needed between stem and shaft depends on the type of osteotomy. In the trochanteric osteotomy, the medial femoral column is intact and 4–7 cm length of contact is required; in the transverse femoral osteotomy, a contact portion of 10 cm in length is needed because of the interruption of the medial column.

The analysis of inter-observer and intra-observer agreement has been performed only for Gross (17),

Endo-Klinik (19), AAOS (24), Paprosky (25, 26, 27, 28), DGOT (30), Saleh (33), and Parry (19) classifications. The FBSC showed a similar inter- and intrareliability when compared to the other classifications, being defined as 'good' accordingly to Landis and Koch (16).

A major difference between the FBSC proposed by the authors and the others is that the latter require an intraoperative evaluation of the defect to guide the defect management, while the former can be employed before entering the operating room and therefore enables a more precise preoperative planning.

## Conclusion

Several classification systems have been developed to describe the morphology of the bony defect and to drive accordingly the surgeon in the revision procedure. The previous classifications mainly considered cortical and medullary bone at the level of the defect of poor quality by definition. Therefore, the surgical strategies aimed to achieve a distal fixation bypassing the defect or to fill the defect with bone impaction grafting or structured bone grafts up to the replace the proximal femur with megaprosthesis. The rationale of the FBSC is that 'functional' residual bone stock is present at the level of the defect. Therefore, it can be used to achieve a primary (mechanical) and secondary (biological) stability with cementless implants in order to obtain a femoral fixation more proximal as possible.

### ICMJE Conflict of Interest Statement

The authors declare that there is no conflict of interest that could be perceived as prejudicing the impartiality of the study reported.

**Funding Statement**

The authors received no financial support for the research, authorship, and/or publication of this article.

**References**

- 1 Kurtz S, Ong K, Lau E, Mowat F & Halpern M. Projections of primary and revision hip and knee arthroplasty in the United States from 2005 to 2030. *Journal of Bone and Joint Surgery* 2007 **89** 780–785. (<https://doi.org/10.2106/JBJS.F.00222>)
- 2 Bozic KJ, Kurtz SM, Lau E, Ong K, Vail TP & Berry DJ. The epidemiology of revision total hip arthroplasty in the United States. *Journal of Bone and Joint Surgery* 2009 **91** 128–133. (<https://doi.org/10.2106/JBJS.H.00155>)
- 3 Sheth NP, Melnic CM, Rozell JC & Paprosky WG. Management of severe femoral bone loss in revision total hip arthroplasty. *Orthopedic Clinics of North America* 2015 **46** 329–342. (<https://doi.org/10.1016/j.ocl.2015.02.002>)
- 4 Bianchi L, Galante C & Zagra L. The management of femoral bone stock in THA revision: indications and techniques. *Hip International* 2014 **24**(Supplement 10) S37–S43. (<https://doi.org/10.5301/hipint.5000174>)
- 5 Gross AE, Allan DG, Lavoie GJ & Oakeshott RD. Revision arthroplasty of the proximal femur using allograft bone. *Orthopedic Clinics of North America* 1993 **24** 705–715. ([https://doi.org/10.1016/S0030-5898\(20\)31850-2](https://doi.org/10.1016/S0030-5898(20)31850-2))
- 6 Weeden SH & Paprosky WG. Minimal 11-year follow-up of extensively porous-coated stems in femoral revision total hip arthroplasty. *Journal of Arthroplasty* 2002 **17**(Supplement 1) 134–137. (<https://doi.org/10.1054/arth.2002.32461>)
- 7 Munro JT, Garbuz DS, Masri BA & Duncan CP. Role and results of tapered fluted modular titanium stems in revision total hip arthroplasty. *Journal of Bone and Joint Surgery* 2012 **94**(Supplement A) 58–60. (<https://doi.org/10.1302/0301-620X.94B11.30612>)
- 8 Regis D, Sandri A & Bonetti I. Long-term results of femoral revision with the Wagner self-locking stem. *Surgical Technology International* 2013 **23** 243–250.
- 9 Rogers BA, Sternheim A, Backstein D, Safir O & Gross AE. Proximal femoral allograft for major segmental femoral bone loss: a systematic literature review. *Advances in Orthopedics* 2011 **2011** 257572. (<https://doi.org/10.4061/2011/257572>)
- 10 Halliday BR, English HW, Timperley AJ, Gie GA & Ling RSM. Femoral impaction grafting with cement in revision total hip replacement. Evolution of the technique and results. *Journal of Bone and Joint Surgery* 2003 **85** 809–817.
- 11 Parvizi J, Tarity TD, Slenker N, Wade F, Trappler R, Hozack WJ & Sim FH. Proximal femoral replacement in patients with non-neoplastic conditions. *Journal of Bone and Joint Surgery* 2007 **89** 1036–1043. (<https://doi.org/10.2106/JBJS.F.00241>)
- 12 Gao ZB, Wang ZS & Wang ZQ. Current study on classification of bone deficiency in the revision of total hip replacement. *Zhongguo Gu Shang* 2009 **22** 480–482.
- 13 Ashraf M. Classifications used in total hip arthroplasty. *Total Hip Replacement – An Overview* 2018. (<https://doi.org/10.5772/intechopen.77231>)
- 14 Saleh KJ, Holtzman J, Gafni A, Saleh L, Davis A, Resig S & Gross AE. Reliability and intraoperative validity of preoperative assessment of standardized plain radiographs in predicting bone loss at revision hip surgery. *Journal of Bone and Joint Surgery* 2001 **83** 1040–1046. (<https://doi.org/10.2106/00004623-200107000-00009>)
- 15 Callaghan JJ, Rosenberg AG, Rubash HE, Clohisy JC, Beaulé PE & Valle CJD. *The Adult Hip: Hip Arthroplasty Surgery*, 3rd ed. Wolters Kluwer Health Adis (ESP) 2015.
- 16 Landis JR & Koch GG. The measurement of observer agreement for categorical data. *Biometrics* 1977 **33** 159–174. (<https://doi.org/10.2307/2529310>)
- 17 Gross AE, Lavoie MV, McDermott P & Marks P. The use of allograft bone in revision of total hip arthroplasty. *Clinical Orthopaedics and Related Research* 1985 **197** 115–122. (<https://doi.org/10.1097/00003086-198507000-00014>)
- 18 Gross AE, Allan DG, Leitch KK & Hutchison CR. Proximal femoral allografts for reconstruction of bone stock in revision arthroplasty of the hip. *Instructional Course Lectures* 1996 **45** 143–147.
- 19 Parry MC, Whitehouse MR, Mehendale SA, Smith LK, Webb JC, Spencer RF & Blom AW. A comparison of the validity and reliability of established bone stock loss classification systems and the proposal of a novel classification system. *Hip International* 2010 **20** 50–55. (<https://doi.org/10.1177/112070001002000108>)
- 20 Gozzard C, Blom A, Taylor A, Smith E & Learmonth I. A comparison of the reliability and validity of bone stock loss classification systems used for revision hip surgery. *Journal of Arthroplasty* 2003 **18** 638–642. ([https://doi.org/10.1016/s0883-5403\(03\)00107-4](https://doi.org/10.1016/s0883-5403(03)00107-4))
- 21 Mallory TH. Preparation of the proximal femur in cementless total hip revision. *Clinical Orthopaedics and Related Research* 1988 **235** 47–60. (<https://doi.org/10.1097/00003086-198810000-00006>)
- 22 Engh CA, Glassman AH, Griffin WL & Mayer JG. Results of cementless revision for failed cemented total hip arthroplasty. *Clinical Orthopaedics and Related Research* 1988 **235** 91–110. (<https://doi.org/10.1097/00003086-198810000-00010>)
- 23 Bone stock deficiency in total hip replacement classification and management - AbeBooks. Available at: <https://www.abebooks.com/book-search/title/bone-stock-deficiency-in-total-hip-replacement-classification-and-management/> (Accessed 4 October 2022).
- 24 D'Antonio J, McCarthy JC, Bargar WL, Borden LS, Cappello WN, Collis DK, Steinberg ME & Wedge JH. Classification of femoral abnormalities in total hip arthroplasty. *Clinical Orthopaedics and Related Research* 1993 **296** 133–139. (<https://doi.org/10.1097/00003086-199311000-00025>)
- 25 Pak JH, Paprosky WG, Jablonsky WS & Lawrence JM. Femoral strut allografts in cementless revision total hip arthroplasty. *Clinical Orthopaedics and Related Research* 1993 **295** 172–178. (<https://doi.org/10.1097/00003086-199310000-00025>)
- 26 Aribindi R, Barba M, Solomon MI, Arp P & Paprosky W. Bypass fixation. *Orthopedic Clinics of North America* 1998 **29** 319–329. ([https://doi.org/10.1016/s0030-5898\(05\)70330-8](https://doi.org/10.1016/s0030-5898(05)70330-8))
- 27 Valle CJD & Paprosky WG. Classification and an algorithmic approach to the reconstruction of femoral deficiency in revision total hip arthroplasty. *Journal of Bone and Joint Surgery* 2003 **85–A**(Supplement 4) 1–6. (<https://doi.org/10.2106/00004623-200300004-00001>)
- 28 Della Valle CJ & Paprosky WG. The femur in revision total hip arthroplasty evaluation and classification. *Clinical Orthopaedics and Related Research* 2004 **420** 55–62. (<https://doi.org/10.1097/00003086-200403000-00009>)
- 29 Käfer W, Fraitzl CR, Kinkel S, Puhl W & Kessler S. Analysis of validity and reliability of three radiographic classification systems for preoperative assessment of bone stock loss in revision total hip arthroplasty. *Zeitschrift für Orthopädie und Ihre Grenzgebiete* 2004 **142** 33–39. (<https://doi.org/10.1055/s-2004-818027>)
- 30 Bettin D & Katthagen BD. The German Society of orthopedics and Traumatology classification of bone defects in total hip endoprostheses revision operations. *Zeitschrift für Orthopädie und*

- Ihre Grenzgebiete* 1997 **135** 281–284. (<https://doi.org/10.1055/s-2008-1039389>)
- 31 Taylor J & Rorabeck C. Hip revision arthroplasty Approach to the femoral side. *Clinical Orthopaedics and Related Research* 1999 **369** 208–222.
- 32 Pipino F & Molfetta L. GIR classification of acetabular and femoral bone loss in revision hip arthroplasty surgery. *Journal of Orthopaedics and Traumatology* 2000 **2** 69–77. (<https://doi.org/10.1007/pl00012200>)
- 33 Saleh KJ, Holtzman J, Gafni A, Saleh L, Jaroszynski G, Wong P, Woodgate I, Davis A, Gross AE. Development, test reliability and validation of a classification for revision hip arthroplasty. *Journal of Orthopaedic Research* 2001 **19** 50–56. ([https://doi.org/10.1016/s0736-0266\(00\)00021-8](https://doi.org/10.1016/s0736-0266(00)00021-8))
- 34 Lieberman JR, Moeckel BH, Evans BG, Salvati EA & Ranawat CS. Cement-within-cement revision hip arthroplasty. *Journal of Bone and Joint Surgery* 1993 **75** 869–871. (<https://doi.org/10.1302/0301-620X.75B6.8245073>)
- 35 Dorr LD, Faugere MC, Mackel AM, Gruen TA, Bogner B & Malluche HH. Structural and cellular assessment of bone quality of proximal femur. *Bone* 1993 **14** 231–242. ([https://doi.org/10.1016/8756-3282\(93\)90146-2](https://doi.org/10.1016/8756-3282(93)90146-2))
- 36 Nguyen BN, Hoshino H, Togawa D & Matsuyama Y. Cortical thickness index of the proximal femur: a radiographic parameter for preliminary assessment of bone mineral density and osteoporosis status in the age 50 years and over population. *Clinics in Orthopedic Surgery* 2018 **10** 149–156. (<https://doi.org/10.4055/cios.2018.10.2.149>)