

Anterior cruciate ligament failure and management

Juan Carlos Monllau^{1,2}, Simone Perelli^{1,2} and Giuseppe Gianluca Costa³

¹Department of Orthopaedic Surgery, Hospital del Mar, Universitat Autònoma de Barcelona (UAB), Barcelona, Spain

²ICATKnee, Institut Català de Traumatologia i Medicina de l'Esport (ICATME), Hospital Universitari Dexeus, UAB, Barcelona, Spain

³Orthopaedic Surgery Department, Ospedale Umberto I, Enna, Italy

Correspondence should be addressed to J C Monllau

Email
jmonllau@psmar.cat

- Anterior cruciate ligament (ACL) reconstruction failure can be defined as abnormal knee function due to graft insufficiency with abnormal laxity or failure to recreate a functional knee according to the expected outcome.
- Traumatic ruptures have been reported as the most common reason for failure. They are followed by technical errors, missed concomitant knee injuries, and biological failures.
- An in-depth preoperative examination that includes a medical history, clinical examinations, advanced imaging, and other appropriate methods is of utmost importance.
- There is still no consensus as to the ideal graft, but autografts are the favorite choice even in ACL revision.
- Concomitant meniscal treatment, ligamentous reconstruction, and osteotomies can be performed in the same surgical session to remove anatomical or biomechanical risk factors for the failure.
- Patient expectations should be managed since outcomes after ACL revision are not as good as those following primary ACL reconstruction.

Keywords

- ▶ anterior cruciate ligament failure
- ▶ anterior cruciate ligament revision
- ▶ preoperative planning
- ▶ graft choice
- ▶ posterior tibial slope
- ▶ osteotomy
- ▶ outcomes
- ▶ instructional lecture

EFORT Open Reviews
(2023) **8**, 231–244

Introduction

Surgical reconstruction of the anterior cruciate ligament (ACL) is supported in the international literature as the treatment of choice in sports-active patients due to the fundamental role of the ACL in joint kinematics and in the preservation of the intra-articular knee structures (1, 2). The last two decades have seen significant advancements in surgical techniques, our understanding of knee biomechanics and injury prevention expertise. Despite this, the risk of failure is still substantial. It ranges from 1.8 to 11.1% (3, 4) at midterm follow-up and up to 10.4–16.7% at long-term follow-up (5).

The unambiguous and universally accepted definition of failure after ACL reconstruction is yet to be determined. Historically, a failed ACL reconstruction was defined by the presence of abnormal anteroposterior or rotatory knee instability (6). However, a recent meta-analysis reported 34% of patients undergoing ACL reconstruction had a positive Lachman test and 24% of those patients had a positive pivot-shift test in spite of having satisfactory subjective outcomes (7). Conversely, in another meta-analysis evaluating long-term ACL reconstruction results, a positive Lachman and pivot shift test were found in 9.4 and 9.3% of cases, respectively. However, abnormal objective

outcomes have been reported in one-third of all cases (5). Beyond that instability, Johnson and Fu proposed a more inclusive definition of failure considering also pain and stiffness (8). Such objective criteria do not consider the patients' functional demands that could not be met due to a dysfunctional knee. Finally, the 2022 European Society of Sport Traumatology, Knee Surgery and Arthroscopy (ESSKA) consensus defined ACL reconstruction failure as abnormal knee function due to graft failure itself with abnormal laxity or failure to recreate a functional knee according to the expected outcome (9).

When an ACL reconstruction fails, revision surgery is indicated to improve knee function. The number of these procedures has risen over the years (10), as the natural result of the increasing participation in sports. However, ACL revision is still a demanding surgery and provides inferior outcomes (in terms of both patient-reported outcomes and objective function scores) when compared to primary ACL reconstruction (11, 12, 13). Several issues are still a matter of debate. They include the preoperative evaluation, the ideal graft choice, when a one-step approach can be performed or a two-step approach is required, the need for concomitant surgeries

as well as indications for bony deformities correction. The available literature does not provide clear evidence-based knowledge on these topics. As a result, the management of failed ACL reconstructions is still too often based on the surgeons' personal experience.

This article aims at providing an evidence-base as well as an expert opinion about the etiology, preoperative planning, and management of patients with a failed ACL reconstruction. Furthermore, outcomes after ACL revision will be discussed with the aim of providing a friendly-reader review of the currently available literature.

Reasons for failure

The identification of the causes of failure is the first step for a successful ACL revision. However, this can be challenging because several factors may lead to ACL reconstruction failure (14). Sometimes, the main cause can be unclear, or a combination of more reasons may be found (14, 15).

The causes of failure may be temporally distinguished between early and late, although an exact cut-off has not been determined (9). Early failure is usually related to the failure of graft incorporation because of fixation errors or biological factors, aggressive rehabilitation or poor compliance, a premature return to high-demand activities, and a new traumatic event (16). Late failures may be due to technical errors, recurrent trauma, or missed associated injuries (17).

Knee trauma has been reported as the most common reason for failure. It accounts for 29–70% of revision cases (15, 16, 18, 19). Although not predictable, some predisposing factors have been called into question. They comprise a younger age, the male gender, and high-impact activities (14, 20). Early aggressive rehabilitation and a premature return to sport may also lead to reinjury (17, 21). Improper neuromuscular control exposes the ACL graft to increased loads, thus increasing the risk of failure. A large body of research done over the last 25 years that focused on this issue has demonstrated that prevention programs can effectively decrease the number of ACL tears (22, 23, 24).

Technical errors seem to play a major or contributing role in 22–79% of reported ACL failures (16, 19), with tunnel malposition being the leading cause of failure (18, 19). Positioning errors in tunnel placement can involve both the femoral tunnel and the tibial tunnel that may result in excessive graft strain (25), persistent instability (26, 27), graft impingement (28, 29), and loss of motion (19, 30). While inadequate stability and excessive strain may predispose to mechanical failure, graft impingement can cause an attritional rupture or interfere with biological healing. Femoral tunnel positioning errors are found to be more common than tibial tunnel ones (18, 19). Unsurprisingly, one of the

most common causes of recurrent instability identified after ACL reconstruction is vertical femoral tunnel placement high in the intercondylar notch, which is not able to constrain the knee under rotatory forces (26, 27). On the other hand, a graft that is placed too posterior and low in the femoral condyle edge is exposed to high strain during knee extension (25). Tibial tunnel placement plays an important role in knee stability and graft failure risk. An excessively posterior tibial tunnel may result in a vertical ACL graft, thus affecting both anteroposterior and rotatory knee stability (31). However, an anterior tibial tunnel also leads to greater graft impingement in extension and excessive strain in knee flexion (32, 33). Technical errors also include fixation failures even though they seem to be a very uncommon cause of failure. It has only been reported in about 2–5% of cases (15, 34). For instance, interference screw divergence has been proven to affect graft pullout strength (35, 36, 37). Similarly, cortical buttons deployed in the substance of the quadriceps can cause underlying muscle necrosis and eventual graft slippage before full graft incorporation. Otherwise, secondary graft slippage through relatively soft cancellous bone may be responsible for failure if the button is deployed in the femoral tunnel's cancellous bone (38).

Missed concomitant knee injuries constitute another substantial theme in this topic. The available literature reports that nearly 15% of ACL failures are a result of a missed diagnosis of concomitant ligament, meniscus, or cartilage lesions (16, 39). The most commonly unrecognized instability is secondary to a posterolateral corner (PLC) injury (17). Several biomechanical studies have demonstrated that PLC injuries significantly contribute to anteroposterior knee stability (40) and increase loads on the ACL when applying a varus moment or a combined varus-internal rotation moment to the knee joint (41, 42). It also happens during simulated gait and squatting testing (43). In such settings, an isolated ACL reconstruction is not enough to restore native knee stability (42). Similarly, the posteromedial aspect of the knee greatly contributes to anteromedial knee stability. ACL strain was found to be increased after medial collateral ligament (MCL) sectioning in some cadaveric studies, exposing the ACL to the risk of rupture when applying a valgus stress or an intra-rotation movement of the tibia (44, 45). Furthermore, combined MCL and ACL deficiency generates increased anterior tibial translation when compared to isolated ACL-deficient knee (44). Meniscus integrity loss has also been advocated as a potential cause of ACL reconstruction failure. Then again, conflicting outcomes have been described in the literature (14, 46). Nonetheless, there is abundant evidence in the literature about the contribution of the menisci to knee stability as they act as secondary restraints for anterior and rotatory tibial displacement (47, 48, 49). Meniscus repair

would seem to restore knee stability comparable to ACL-reconstructed knees with intact menisci (49).

Biological failure is another unsolved question. The real incidence of this reason for graft failure is unclear since an unambiguous definition has not yet been determined (17). Several pathways have been debated to explain the reasons for biological failure. The reasons encompass a disturbance in revascularization, inhibited cellular proliferation, or deficiency in the ligamentization process (50). Graft choice plays a great role in explaining biological failures since graft incorporation is strictly related to graft type, the bone-to-graft interface as well as patient immune response. It is not surprising that biological failure is found more pronounced in allografts (51). Among the autografts, hamstring tendons showed a significantly higher biological failure rate in comparison to bone-patellar tendon-bone (BPTB) grafts (19). Infection can be counted among the causes of biological failure. Although uncommon, this complication may lead to devastating sequelae for the knee joint (52). Early diagnosis and prompt treatment are crucial to minimize consequences of sepsis (52, 53, 54). Graft preservation protocols have been reported with mixed results. However, the risk of graft removal or secondary graft failure remains high (52, 54, 55). The prevention of infection by adopting appropriate measures (for instance, autograft soaking in vancomycin) remains the trump card (56).

Preoperative assessment

An in-depth preoperative examination that includes the medical history, clinical examinations, and advanced imaging methods is a crucial element for the successful management of ACL reconstruction failures.

Patients' demographic characteristics (age, gender, body mass index) as well as patient-specific modifiable features (type of sport resumed, timing of returning to sport after ACL reconstruction) deserve particular consideration due to their role as predisposing factors to ACL failure (14). The level of activity, pain, swelling, and instability symptoms should also be assessed. Recurrent synovitis and persistent pain should induce suspicion of a low-grade infection. The surgical details of the previous ACL reconstruction need to be collected before performing the revision procedure. Knowledge of the previously used graft, the drilling technique, and the fixation methods help the surgeons to properly make the graft choice and plan the surgical technique. The rehabilitation protocol and postoperative complications also need to be investigated.

Physical examination

A meticulous physical examination must include standing and gait assessment of the lower limbs to evaluate coronal and sagittal limb alignment and the muscular/neurological

status. Varus malalignment has been demonstrated to have a two-fold incidence in the revision setting with respect to primary ACL reconstruction (57). On the other hand, valgus malalignment led to an increase in the *in situ* forces on the ACL graft, with particular regard to the posterolateral bundle (58). Gait analysis may reveal the presence of a valgus/varus thrust or hyperextension, which may be indicative of a more complex structural problem that should be addressed prior to any revision. Likewise, extensor mechanism dysfunction should be identified if present.

Careful inspection of the skin should be performed to plan the skin incision with the aim of preventing wound healing difficulties and skin necrosis. Active and passive range-of-motion (ROM) should be assessed and compared with the uninjured side. Knee extension or flexion deficits represent a contraindication for ACL revision surgery (9) unless they are the result of a malpositioned graft. Knee hyperextension is a well-recognized risk factor for failure (59, 60, 61) and may require concomitant surgical procedures (62). Furthermore, basic knee examination should assess the presence of intra-articular effusion, patellar tracking, patellar tendon discomfort, quadriceps strength, and patellar facet tenderness.

The mainstay of ligament assessment is the manual evaluation of anteroposterior (with the Lachman test and the anterior drawer test) and rotatory knee laxity (with the pivot-shift test). The Lachman test has the greatest sensitivity and is the most accurate test for ruling out ACL injury (63). In patients with large thigh girth, this maneuver can present difficulties. Modified versions of the original Lachman's test in the prone position (64) as well as alternative tests like the Lever test can be used (65). The pivot-shift test better correlates with patients' clinical symptoms and subjective instability but can show low diagnostic performance in patients that are awake (66). Laxity-detection devices can be helpful to better evaluate knee laxity, but they cannot replace a careful manual evaluation (9). A side-to-side difference greater than 5 mm is widely accepted as evidence of ACL insufficiency (9). Due to the high incidence of missed concomitant injuries, physical evaluation needs to be supplemented by evaluation of the entire ligamentous apparatus of the knee. The presence of a positive posterior drawer or sag sign should be documented as it suggests an associated posterior cruciate ligament (PCL) insufficiency. Valgus and varus tests at 0° and 30° of knee flexion may reveal concomitant medial and lateral collateral ligament insufficiency, respectively. The external rotation recurvatum and dial test at 30° and 90° of knee flexion should be performed to test the PLC. Further diagnostic tests (joint line tenderness, Mc Murray test, Apley test, etc.) should be included to diagnose potential concomitant intra-articular pathologies like meniscal tears or cartilage defects.

Radiologic evaluation

Preoperative imaging is a crucial part of surgical planning in patients who are candidates for ACL revision. Radiographic evaluation represents the first-line test and helps surgeons to evaluate some fundamental parameters like joint narrowing, patellar height, posterior tibial slope (PTS), tunnel placement and widening, and retained hardware (9). An accurate radiological assessment should include the following views:

- Bilateral anteroposterior full-length weight-bearing view: It can be used to define the presence of coronal malalignment and plan concomitant corrective osteotomies if indicated.
- Posteroanterior weight-bearing view at 45° of flexion (Rosenberg view): This view increases the sensitivity of the standard anteroposterior view to document the extent of cartilage wear (9). Additionally, it can be used to evaluate bony morphology and detect predisposing factors to failures such as the femoral notch shape and the lateral femoral condyle width (14, 67).
- Lateral view at 30° of flexion: This view allows for the measurement of the static anterior tibial translation, the patellar height (thus approximately determining the length of the patellar tendon), and the PTS, provided that the first 15 cm of the proximal tibia is visible (9). An increased PTS has been shown to be associated with a greater risk of graft failure following ACL reconstruction (68). A concomitant PTS-reducing osteotomy (tibial deflexion osteotomy) can be indicated in selected cases. Similarly, increased anterior tibial translation is a common finding in multiple ACL reconstruction failures and can be used as red flag in high-risk patients (69, 70).
- Axial weight-bearing radiographic view (Baldini view (71)): It is useful for evaluating patellar tracking and degenerative patellofemoral changes. This is essential when planning to use BPTB or quadriceps tendon as an autograft. This axial weight-bearing view can provide additional information over standard unloaded axial radiographic views (71).

Secondary radiographic views may be requested in the suspicion of multiligament knee injuries. These include varus or valgus stress views to evaluate the integrity of the lateral and medial ligaments, respectively. Kneeling or Telos posterior stress views to quantify posterior laxity due to PCL and accessory ligaments insufficiency may also be called for (72).

Magnetic resonance imaging (MRI) is mandatory to evaluate the integrity of the other knee ligaments and the status of articular cartilage and menisci. Furthermore,

MRIs provide critical information about the primary graft, location and orientation, and diameter of the existing bone tunnels, as well as information about patellar tendon length and quadriceps tendon thickness (9, 73). However, computed tomography (CT) scans are more reliable to evaluate bone tunnels (74, 75). They provide fundamental information when choosing a one-step or a two-step surgical approach (72). Some authors even support three-dimensional CT scan reconstruction to get much more accurate information on tunnel size and location (76).

Surgical management

Surgical management of an ACL failure can be highly demanding for even the most experienced surgeons. Several controversies remain in clinical practice and there are numerous potential pitfalls during surgery. The ideal graft choice, when to perform a one-stage or a two-stage surgery, and the need for concomitant procedures are just some of the open questions with no easy solution. Although there is a growing interest in these main topics, the literature on them is still sparse. An evidence-based approach remains the most appropriate to guide surgeons in this complex topic.

Graft choice

The selection of the optimal graft in ACL revision surgery has always been a matter of debate. It is well known that the ACL graft plays a significant role in clinical outcomes (77), the development of osteoarthritis (78), and the risk of failure after primary reconstruction (79). Hence, the choice of the graft can also have a great influence on ACL revision outcomes.

To date, there is no standard graft for ACL revision. The graft used in primary ACL reconstruction, the presence of severe tunnel widening, and concomitant ligament deficiency are three fundamental determinants when choosing the new graft (9). However, other clinical considerations like patellofemoral joint disorder, anthropometric measures, the surgeons' skills, and which kind of sport the patient plans to resume should be considered.

Autografts remain the most preferred choice even in revision ACL reconstructions (11, 13, 80, 81, 82). Despite its donor site morbidity and the lesser versatility in comparison to allografts, autografts have indisputable advantages. These include faster and more reliable biological integration (83), no risk of disease transmission or immunological rejection, and better objective stability (80, 84). BPTB is used more frequently in revision settings than in primary reconstructions since hamstrings remain the most popular choice in the latter setting (11, 13, 80,

81, 82). Proponents argue that bone-to-bone integration may be particularly convenient in a biologically impaired scenario such as failed ACL reconstruction (85, 86, 87). Ipsilateral BPTB reharvesting has been proposed by some authors, but a higher rate of complications and poorer functional scores have been reported in contrast to contralateral BPTB harvesting (88, 89). The quadriceps tendon with or without a bone block is increasingly being used as an alternative to BPTB. The low complication rate and the good midterm outcomes support this choice, but the long-term benefits are yet to be demonstrated (90, 91). Hamstring tendons remain a valuable option even in revision procedures. One significant advantage to using the hamstring graft is the lower risk of donor site morbidity, especially anterior knee pain and patellar fracture (92). This may be particularly important in patients involved in kneeling or squatting activities or in patients who are predisposed to patellofemoral pain. Some authors even recommend harvesting the contralateral hamstring tendon, but the high risk of contralateral ACL tear should not be disregarded (4). The most reported disadvantage is related to graft size, which may represent a major limitation in challenging cases with severe tunnel enlargement. Furthermore, soft tissue-to-bone healing requires a slower process of fibrovascular scar tissue maturation at the graft-tunnel interface than bone-to-bone healing with direct contact (85, 86, 87). However, there is currently no evidence of the superiority of BPTB over the hamstring tendons graft in revision ACL surgery in terms of knee stability and failure rates (80).

Allografts are another appealing option in ACL revision due to the lack of potential complications related to autograft harvesting. Types of allografts include BPTB, Achilles tendon, the tendons of tibialis anterior or posterior, and tendons of peroneus longus or brevis. All have different biomechanical properties (15, 80, 93). The versatility of allografts can be convenient when facing challenging cases, and customized bone blocks can be used to fill enlarged tunnels during a single-stage procedure (50). On the other hand, allografts have some inherent drawbacks. They include availability, increased cost, and the theoretical risk of disease transmission. Nevertheless, the reported incidence of infection is less than 1% (94) and the risk of viral disease transmission is estimated to be less than 1 in 1,600,000 cases (95). Another source of concern is the biomechanical properties of allografts. Those properties may be affected by several factors like the age of the donor, sterilization process, and preservation methods (93). Donors older than 65 years of age provide allogenic tissue with significantly lower ultimate stress values than younger donors (93). The sterilization process was an important topic in the last decade. Gamma irradiation has been demonstrated, with a dose-dependent effect, to reduce strain energy,

modulus, and maximum stress as well as the maximum force up to 46% (96). This may explain why allografts provide inferior objective outcomes and greater failure rates than autografts in clinical studies (80, 84). Indeed, if an allograft irradiated with higher doses is excluded, there is no difference between autografts and allografts relative to outcomes (80, 97). Various chemical sterilization measures have been proposed as alternatives, but those techniques have also been associated with negative effects on the biomechanical properties of allografts (93). Even prolonged freezing at -80°C has been shown to decrease load to failure, ultimate stress, and ultimate strain (93). In addition to this, some issues persist concerning the healing and biological incorporation of allografts. Although the healing process is the same as in autografts, the replacement of the donor tissue with host synovial cells has proven to be significantly slower (98, 99). It may require 3 years or more for complete incorporation (98). For those reasons, allografts should be used prudently in patients with a high risk of failure, especially pediatric and adolescent athletes, as existing studies have revealed a significantly higher failure rate for the allograft than the autograft in those patient populations (79).

Synthetic grafts represent a further option but should be considered with circumspection because of their inferior middle and long-term results (100). At present, synthetic grafts are indicated as an alternative to the above-mentioned graft options in the older, less active population among whom the risk of graft rupture is comparatively less (14, 100).

One- or two- stage surgery

The decision for a one- or two-stage revision depends on multiple factors that must be considered as there is currently no consensus regarding the indication of one or another procedure (101, 102).

Even though it is not frequent, a two-stage revision is mandatory if an infection is suspected.

Planning a one-stage ACL revision in the case of a significant extension or flexion deficit requires an exhaustive analysis of the causes. When the cause of the deficit in mobility can be resolved at the same time as that of instability, the functional results have proven to be satisfactory. It is mostly true in the case of completely incorrect positioning of the tunnels or displaced meniscal or osteochondral tissues within the tibio-femoral joint (103).

When the cause of the ROM deficit is not detectable or is due to severe arthrofibrosis, a two-stage surgery is recommended.

Rarely does the presence of metallic material interfere with a one-step surgery, but it may. Either way, the presence, position, and bone integration of interferential

screws, plate, or nail should be evaluated properly to decide the surgical approach. In the case of multiple previous surgeries, the scars should also be taken into account. When possible, a skin approach located at previous scars is suggested to avoid vascular impairment and skin necrosis.

The location, dimension, and morphology of the previous bone tunnels is probably the most important factor to be considered for a proper decision as to the technique to be used in the revision ACL reconstruction. When the position of the previous tunnels is correct (anatomic), only the diameter should be considered. A high level of evidence is still lacking, but most authors consider that a diameter around 12 mm is the cut-off to consider a revision in two stages (104, 105). Anyway, no absolute threshold exists for the critical tunnel diameter, and some authors suggest 15 mm as the limit for a one-stage revision (106). Possibly, a universal threshold can be proposed given that it varies when it comes to graft choice, drilling technique, fixation technique, and knee size (104, 105, 106).

Nevertheless, some authors consider that the clinical results at 5–15 years postoperatively are the same in patients with a more or less 12 mm tunnel diameter when a one-stage ACL revision is performed (107).

Even in the case of a diameter larger than 15 mm, some techniques have been described to bypass the problem of a precarious fixation of the new graft in the former tunnel if a one-stage revision is required or suggested for clinical or personal reasons. Haidar *et al.* (108) proposed the use of an out-in technique for femoral tunnel drilling. They stated that this technique makes for a different obliquity of the tunnel and thereby allows for a solid fixation and good integration of the graft even in the case of a previous femoral tunnel of greater diameter.

Pioger *et al.* (109) subsequently presented promising results using this even when a one-stage revision surgery was performed in patients with large femoral tunnel diameter.

Another approach to solve the problem of a dilated femoral tunnel is the over-the-top technique (110). In this case, the graft does not need a femoral tunnel. It is passed behind the lateral femoral condyle (over the top position) and fixed on the posterolateral cortex of the femur by means of staples.

More complex is the analysis of the cases without dilation but with mispositioning of the tunnels. Precise preoperative planning should make clear whether the previous tunnels are completely out of the way (completely non-anatomic) for the creation of the new ones or if any kind of interference is expected (partially anatomic or previous anatomic tunnels). In the first case, a one-stage procedure is an available option. In the latter case, the stability and the integration of the new graft may

be compromised both if the tunnels are partially anatomic and when they are anatomic but present with severe osteolysis (111). (Fig. 1)

For these cases, a two-stage procedure is more recommendable even though some rescue procedures that allow for a one-stage revision have been described. They described the different uses of bone impaction grafting to support the new bone tunnels circumferentially even in the case of mispositioning or severe osteolysis of the former tunnels (112, 113).

Finally, it might be possible to approach complex cases in which both the tibial and femoral tunnels are dilatated or mispositioned using an Achilles tendon allograft. Following the steps of the over-the-top technique or drilling an out-in femoral tunnel, the femoral part of the reconstruction is resolved. Furthermore, the problem of the tibial tunnel is solved by sculpting a truncated cone block of the desired dimension from the calcaneus bone block to fill the gap of the former tunnel (114).

In the case in which there is no collision but the distance between the two tunnels is less than 2 mm, the risk of this bone bridge rupture is high during maneuvers like reaming, impacting, or screwing in the new tunnel. For these reasons, the previous tunnel can be filled with structural bone or an interference screw to improve the resistance of the bone bridge (115). (Fig. 2)

In the case of a two-stage revision, the bone grafting of the previous tunnel can be achieved with an autologous graft (both from the iliac crest and from the proximal tibia) or with an allograft (either preformed cylinders or bone chips or tailored bone blocks) (101).

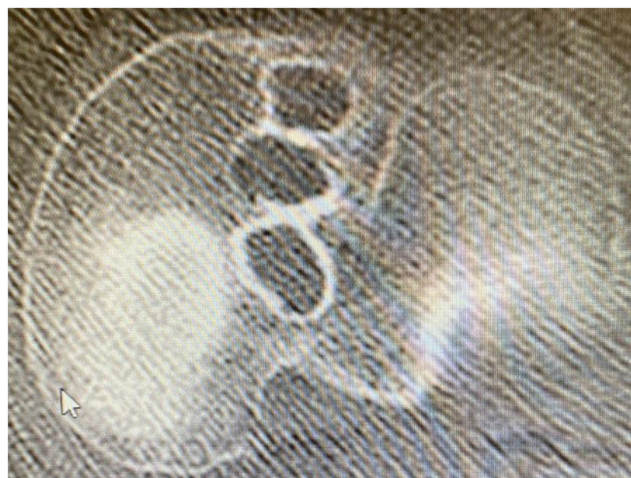

Figure 1

Preoperative CT scan axial view showing three different tunnels for previous ACL reconstruction. In this case, a two-stage revision is recommended.

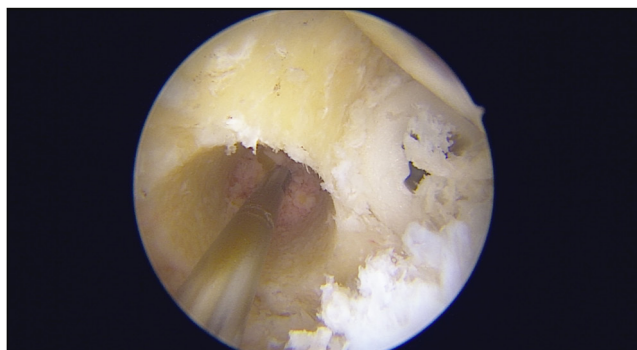


Figure 2

The previous tunnel was filled with an interference screw before the drilling of the new femoral tunnel to avoid the breakage of the bone bridge between the two tunnels.

Allograft bone matrix and calcium phosphate have also been described as useful for tunnel grafting, but solid clinical results for these techniques are lacking (106, 116).

When a two-stage procedure is adopted, the time between the two stages of the revision should be sufficient to allow for the correct integration of the graft. Most of the authors suggest a period of between 3 and 6 months, with there being a difference between autologous or allogenic bone. A CT scan can be used to evaluate bone integration before the second stage of the revision (117, 118).

Concomitant procedures

When a revision ACL surgery is performed, several other procedures may be required to resolve both the anatomical predisposing factor for the ACL failure and other symptoms like compartmental pain.

More than 4° of varus or valgus is considered a coronal deformity suitable for correction. The osteotomy is mostly indicated in the case of symptomatic cartilage or meniscal insufficiency, when a varus or valgus thrust is present or if a meniscal transplantation or cartilage procedure is performed at the same time as the ACL revision (119, 120, 121). Moreover, any sagittal malalignment should be addressed in the setting of an ACL revision, and even more

so when facing multiple failed ACL reconstructions. If the PTS is greater than 12° and the patient does not present preoperative hyperextension, an anterior closing-wedge osteotomy to reduce the tibial slope should be considered (119, 120, 121, 122) (Fig. 3). In the case of medial meniscus insufficiency, the indication for this kind of osteotomy is even more supported from a biomechanical point of view. The goal of the correction is not clearly described since a range of values from 3 to 10° has been described (123, 124).

The use of the anterolateral tenodesis in the setting of an ACL revision has been described as beneficial. Therefore, it should be considered in almost all cases if there are no contraindications for this procedure (e.g. concomitant PLC lesion) (125, 126).

In the case of two-stage revision, an anterolateral tenodesis should be performed in the first stage to reduce subjective and objective stability in the interim between the two stages (127).

Peripheral knee instability can be a cause of failure of the ACL revision or a risk factor for poorer outcomes (128).

Therefore, both medial and lateral clinically evident instability should be addressed at the same time as an ACL revision. Indications for the thresholds of peripheral instability are lacking but the general recommendation is to address grade 2 and 3 instability (129, 130).

Meniscal transplantation is usually reserved only for patients who present with the so-called postmeniscectomy syndrome, pain and swelling associated or not to cartilage lesions after a meniscectomy. Considering the stabilization properties of the menisci in the setting of an ACL revision surgery, meniscal transplantation may be indicated even without pain or repetitive swelling. The reason behind that is that a total or subtotal meniscectomy can contribute to knee instability that, if not addressed, can lead to a failure of the ACL revision (131, 132).

Outcomes

Although evidence on ACL revision outcomes remains sparse, an increasing body of research has been made available over recent years. Several systematic reviews and meta-analyses have focused on this issue and investigated

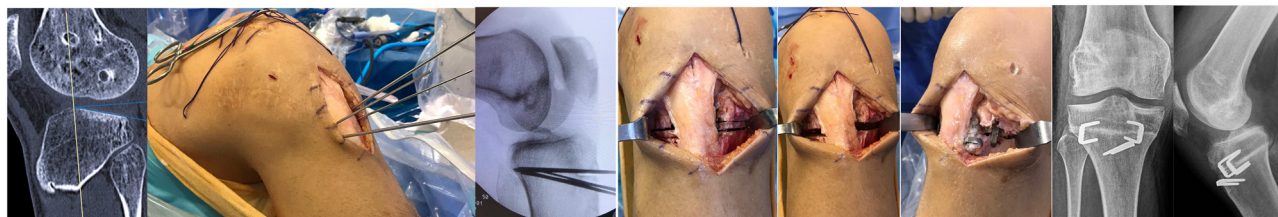


Figure 3

From left to right are described all the phases of a concomitant slope-decreasing osteotomy in the context of an ACL revision surgery.

the different aspects of ACL revision surgery and the related results.

Patient-reported outcome measures (PROMs) have been shown to have increased from their preoperative status in three recent systematic reviews (12, 81, 102). However, ACL revision PROMs were reported significantly inferior to primary ACL reconstruction subjective scores (11). According to the objective International Knee Documentation Committee classification, a normal or nearly normal knee function is reported in between 62 and 91% of cases (11, 12, 13, 133, 134, 135). Again, this finding was significantly inferior to the results after primary ACL reconstruction (11, 12, 13). Conversely, anteroposterior knee laxity evaluated manually by performing the Lachman test or using an arthrometric test does not significantly differentiate between primary and revision ACL reconstruction (11, 12), but a higher rate of abnormal rotatory knee laxity is described in the ACL revision group (11, 12).

Return to sports activity after revision ACL reconstruction was addressed in five meta-analyses, with mixed results (11, 12, 81, 133, 134, 135). In two of them (11, 12), there was no difference between the primary and the revision groups on the Tegner activity scale. In an additional meta-analysis including 59 studies (102), the pooled Tegner score at the last follow-up was found to be significantly lower than the preinjury Tegner score. Three patients out of four were able to return to sport at any level, with no difference in patients who underwent primary ACL reconstruction. However, this finding radically changed when addressing the return to sports at the same level, since only 43% of patients were reported against 63% in the primary ACL reconstruction (102). These results match with those published in another 2 meta-analyses (81, 135), in which almost 8 patients out of 10 were able to return to sports after revision ACL reconstruction, but only half of them returned to the same pre-injury sport level. The average time to return to sports was reported as between 5 and 12 months after surgery (81, 135). The main reason for not returning to sport after ACL revision surgery was knee-related problems in most of the cases, followed by the fear of reinjury and other unrelated reasons (135).

Overall, the cumulative failure rate after ACL revision surgery was estimated to range from 6 to 21.7% (136), which seems to be higher than the cumulative failure rate after primary ACL reconstruction (3, 4). Excluding repeated revisions, subsequent procedures were reported in about 11% of cases (11). The reasons for subsequent surgeries included hardware removals (5–12%), meniscectomies (6–10%), and arthrolysis (2%) (136).

The role of prevention in knee osteoarthritis progression was evaluated in two meta-analyses (11, 137). Radiographic signs of osteoarthritis progression were detected in about 20% of the cases, ranging from 3% after

4 years to 41% after 6 years (105). Patients who underwent ACL revision are exposed to twice the risk of having radiographic evidence of osteoarthritis when compared to patients who had had primary ACL reconstruction (11). The progression of osteoarthritis was more pronounced in the medial tibiofemoral compartment, followed by the patellofemoral compartment and lateral compartment (137). This finding matches with the higher prevalence of concomitant meniscal lesions in the medial compartment at the time of revision surgery (13, 137).

Conclusion

The management of ACL reconstruction failure has become an increasingly common challenge in recent decades. Correct identification of the reasons for failure and accurate preoperative planning are essential for successful ACL revision. Although clinical research has increased over the years, several issues are still debated. They include the ideal graft choice and indications for associated surgical procedures. There remains a great need to perform more high-quality studies with the goal of developing evidence-based knowledge in this field and providing better outcomes to the growing demand for solutions.

ICMJE conflict of interest statement

The authors declare that there is no conflict of interest that could be perceived as prejudicing the impartiality of the research reported.

Funding statement

No funding was received for this manuscript.

References

1. Kessler MA, Behrend H, Henz S, Stutz G, Rukavina A & Kuster MS. Function, osteoarthritis and activity after ACL-rupture: 11 years follow-up results of conservative versus reconstructive treatment. *Knee Surgery, Sports Traumatology, Arthroscopy* 2008 **16** 442–448. (<https://doi.org/10.1007/s00167-008-0498-x>)
2. Hurd WJ, Axe MJ & Snyder-Mackler L. A 10-year prospective trial of a patient management algorithm and screening examination for highly active individuals with anterior cruciate ligament injury: Part 1, outcomes. *American Journal of Sports Medicine* 2008 **36** 40–47. (<https://doi.org/10.1177/0363546507308190>)
3. Magnussen RA, Meschbach NT, Kaeding CC, Wright RW & Spindler KP. ACL graft and contralateral ACL tear risk within ten years following reconstruction: a systematic review. *JBJS Reviews* 2015 **3** e3. (<https://doi.org/10.2106/JBJS.RVW.N.00052>)
4. Wright RW, Magnussen RA, Dunn WR & Spindler KP. Ipsilateral graft and contralateral ACL rupture at five years or more following ACL reconstruction: a systematic review. *Journal of Bone and Joint Surgery. American Volume* 2011 **93** 1159–1165. (<https://doi.org/10.2106/JBJS.J.00898>)
5. Grassi A, Pizza N, Al-Zu'bi BBH, Fabbro GD, Lucidi GA & Zaffagnini S. Clinical outcomes and osteoarthritis at very long-term follow-up after ACL reconstruction:

a systematic review and meta-analysis. *Orthopaedic Journal of Sports Medicine* 2022 **10** 23259671211062238. (<https://doi.org/10.1177/23259671211062238>)

6. Noyes FR & Barber-Westin SD. Revision anterior cruciate surgery with use of bone-patellar tendon-bone autogenous grafts. *Journal of Bone and Joint Surgery. American Volume* 2001 **83** 1131–1143. (<https://doi.org/10.2106/00004623-200108000-00001>)

7. Biau DJ, Tournoux C, Katsahian S, Schranz PJ & Nizard RS. Bone-patellar tendon-bone autografts versus hamstring autografts for reconstruction of anterior cruciate ligament: meta-analysis. *BMJ* 2006 **332** 995–1001. (<https://doi.org/10.1136/bmj.38784.384109.2F>)

8. Johnson DL & Fu FH. Anterior cruciate ligament reconstruction: why do failures occur? *Instructional Course Lectures* 1995 **44** 391–406.

9. Tischer T, Beaufils P, Becker R, Ahmad SS, Bonomo M, Dejour D, Eriksson K, Filardo G, Feucht MJ, Grassi A, et al. Management of anterior cruciate ligament revision in adults: the 2022 ESSKA consensus part I—diagnostics and preoperative planning. *Knee Surgery, Sports Traumatology, Arthroscopy* 2022. (<https://doi.org/10.1007/s00167-022-07214-w>)

10. Leroux T, Wasserstein D, Dwyer T, Ogilvie-Harris DJ, Marks PH, Bach BR, Townley JB, Mahomed N & Chahal J. The epidemiology of revision anterior cruciate ligament reconstruction in Ontario, Canada. *American Journal of Sports Medicine* 2014 **42** 2666–2672. (<https://doi.org/10.1177/0363546514548165>)

11. Grassi A, Ardern CL, Marcheggiani Muccioli GM, Neri MP, Marcacci M & Zaffagnini S. Does revision ACL reconstruction measure up to primary surgery? A meta-analysis comparing patient-reported and clinician-reported outcomes, and radiographic results. *British Journal of Sports Medicine* 2016 **50** 716–724. (<https://doi.org/10.1136/bjsports-2015-094948>)

12. Yan X, Yang XG, Feng JT, Liu B & Hu YC. Does revision anterior cruciate ligament (ACL) reconstruction provide similar clinical outcomes to primary ACL reconstruction? A systematic review and meta-analysis. *Orthopaedic Surgery* 2020 **12** 1534–1546. (<https://doi.org/10.1111/os.12638>)

13. Wright RW, Gill CS, Chen L, Brophy RH, Matava MJ, Smith MV & Mall NA. Outcome of revision anterior cruciate ligament reconstruction: a systematic review. *Journal of Bone and Joint Surgery. American Volume* 2012 **94** 531–536. (<https://doi.org/10.2106/JBJS.K.00733>)

14. Costa GG, Perelli S, Grassi A, Russo A, Zaffagnini S & Monllau JC. Minimizing the risk of graft failure after anterior cruciate ligament reconstruction in athletes. A narrative review of the current evidence. *Journal of Experimental Orthopaedics* 2022 **9** 26. (<https://doi.org/10.1186/s40634-022-00461-3>)

15. MARS Group, Wright RW, Huston LJ, Spindler KP, Dunn WR, Haas AK, Allen CR, Cooper DE, DeBerardino TM, Lantz BB, et al. Descriptive epidemiology of the Multicenter ACL Revision Study (MARS) cohort. *American Journal of Sports Medicine* 2010 **38** 1979–1986. (<https://doi.org/10.1177/0363546510378645>)

16. Kamath GV, Redfern JC, Greis PE & Burks RT. Revision anterior cruciate ligament reconstruction. *American Journal of Sports Medicine* 2011 **39** 199–217. (<https://doi.org/10.1177/0363546510370929>)

17. Fabricant PD, McCarthy MM, Pearle AD, et al. Biomechanics and etiology of ACL graft failure. In *Revision ACL Reconstruction. Indications and Technique*, pp. 33–41. R Marx, Ed.: New York, NY: Springer 2014. (https://doi.org/10.1007/978-1-4614-0766-9_4)

18. Chen JL, Allen CR, Stephens TE, Haas AK, Huston LJ, Wright RW, Feeley BT & Multicenter ACL Revision Study (MARS) Group. Differences in mechanisms

of failure, intraoperative findings, and surgical characteristics between single- and multiple-revision ACL reconstructions: a MARS cohort study. *American Journal of Sports Medicine* 2013 **41** 1571–1578. (doi:10.1177/0363546513487980.)

19. Vermeijden HD, Yang XA, van der List JP, DiFelice GS, Rademakers MV & Kerkhoffs GMMJ. Trauma and femoral tunnel position are the most common failure modes of anterior cruciate ligament reconstruction: a systematic review. *Knee Surgery, Sports Traumatology, Arthroscopy* 2020 **28** 3666–3675. (<https://doi.org/10.1007/s00167-020-06160-9>)

20. Zhao D, Pan JK, Lin FZ, Luo MH, Liang GH, Zeng LF, Huang HT, Han YH, Xu NJ, Yang WY, et al. Risk factors for revision or rerupture after anterior cruciate ligament reconstruction: a systematic review and meta-analysis. *American Journal of Sports Medicine* 2022 3635465221119787. (<https://doi.org/10.1177/03635465221119787>)

21. Steffen K, Myklebust G, Olsen OE, Holme I & Bahr R. Preventing injuries in female youth football—a cluster-randomized controlled trial. *Scandinavian Journal of Medicine and Science in Sports* 2008 **18** 605–614. (<https://doi.org/10.1111/j.1600-0838.2007.00703.x>)

22. Paterno MV, Schmitt LC, Ford KR, Rauh MJ, Myer GD, Huang B & Hewett TE. Biomechanical measures during landing and postural stability predict second anterior cruciate ligament injury after anterior cruciate ligament reconstruction and return to sport. *American Journal of Sports Medicine* 2010 **38** 1968–1978. (<https://doi.org/10.1177/0363546510376053>)

23. Padua DA & Distefano LJ. Sagittal plane knee biomechanics and vertical ground reaction forces are modified following ACL injury prevention programs: a systematic review. *Sports Health* 2009 **1** 165–173. (<https://doi.org/10.1177/194738108330971>)

24. Silvers-Granelli H, Mandelbaum B, Adeniji O, Insler S, Bizzini M, Pohlig R, Junge A, Snyder-Mackler L & Dvorak J. Efficacy of the FIFA 11+ injury prevention program in the collegiate male soccer player. *American Journal of Sports Medicine* 2015 **43** 2628–2637. (<https://doi.org/10.1177/0363546515602009>)

25. Markolf KL, Park S, Jackson SR & McAllister DR. Anterior-posterior and rotatory stability of single and double-bundle anterior cruciate ligament reconstructions. *Journal of Bone and Joint Surgery. American Volume* 2009 **91** 107–118. (<https://doi.org/10.2106/JBJS.G.01215>)

26. Lee MC, Seong SC, Lee S, Chang CB, Park YK, Jo H & Kim CH. Vertical femoral tunnel placement results in rotational knee laxity after anterior cruciate ligament reconstruction. *Arthroscopy* 2007 **23** 771–778. (<https://doi.org/10.1016/j.arthro.2007.04.016>)

27. Abebe ES, Kim JP, Utturkar GM, Taylor DC, Spritzer CE, Moorman CT, Garrett WE & DeFrate LE. The effect of femoral tunnel placement on ACL graft orientation and length during in vivo knee flexion. *Journal of Biomechanics* 2011 **44** 1914–1920. (<https://doi.org/10.1016/j.jbiomech.2011.04.030>)

28. Howell SM & Taylor MA. Failure of reconstruction of the anterior cruciate ligament due to impingement by the intercondylar roof. *Journal of Bone and Joint Surgery. American Volume* 1993 **75** 1044–1055. (<https://doi.org/10.2106/00004623-199307000-00011>)

29. Orsi AD, Canavan PK, Vaziri A, Goebel R, Kapasi OA & Nayeb-Hashemi H. The effects of graft size and insertion site location during anterior cruciate ligament reconstruction on intercondylar notch impingement. *Knee* 2017 **24** 525–535. (<https://doi.org/10.1016/j.knee.2017.02.010>)

30. Morgan JA, Dahm D, Levy B, Stuart MJ & MARS Study Group. Femoral tunnel malposition in ACL revision reconstruction. *Journal of Knee Surgery* 2012 **25** 361–368. (<https://doi.org/10.1055/s-0031-1299662>)

- 31. Bedi A, Maak T, Musahl V, Citak M, O'Loughlin PF, Choi D & Pearle AD.** Effect of tibial tunnel position on stability of the knee after anterior cruciate ligament reconstruction: is the tibial tunnel position most important? *American Journal of Sports Medicine* 2011 **39** 366–373. (<https://doi.org/10.1177/0363546510388157>)
- 32. Howell SM.** Principles for placing the tibial tunnel and avoiding roof impingement during reconstruction of a torn anterior cruciate ligament. *Knee Surgery, Sports Traumatology, Arthroscopy* 1998 **6**(Supplement 1) S49–S55. (<https://doi.org/10.1007/s001670050223>)
- 33. Miller MD & Olszewski AD.** Posterior tibial tunnel placement to avoid anterior cruciate ligament graft impingement by the intercondylar roof. An in vitro and in vivo study. *American Journal of Sports Medicine* 1997 **25** 818–822. (<https://doi.org/10.1177/036354659702500615>)
- 34. Trojani C, Sbihi A, Djan P, Potel JF, Hulet C, Jouve F, Bussière C, Ehkirch FP, Burdin G, Dubrana F, et al.** Causes for failure of ACL reconstruction and influence of meniscectomies after revision. *Knee Surgery, Sports Traumatology, Arthroscopy* 2011 **19** 196–201. (<https://doi.org/10.1007/s00167-010-1201-6>)
- 35. Jomha NM, Raso VJ & Leung P.** Effect of varying angles on the pullout strength of interference screw fixation. *Arthroscopy* 1993 **9** 580–583. ([https://doi.org/10.1016/s0749-8063\(05\)80409-8](https://doi.org/10.1016/s0749-8063(05)80409-8))
- 36. Pierz K, Baltz M & Fulkerson J.** The effect of Kurosaka screw divergence on the holding strength of bone-tendon-bone grafts. *American Journal of Sports Medicine* 1995 **23** 332–335. (<https://doi.org/10.1177/036354659502300314>)
- 37. Dworsky BD, Jewell BF & Bach Jr BR.** Interference screw divergence in endoscopic anterior cruciate ligament reconstruction. *Arthroscopy* 1996 **12** 45–49. ([https://doi.org/10.1016/s0749-8063\(96\)90218-2](https://doi.org/10.1016/s0749-8063(96)90218-2))
- 38. Safran MR & Greene HS.** Avoidance and management of intra-articular complications of anterior cruciate ligament reconstruction. *Instructional Course Lectures* 2006 **55** 475–488.
- 39. Samitier G, Marciano AI, Alentorn-Geli E, Cugat R, Farmer KW & Moser MW.** Failure of anterior cruciate ligament reconstruction. *Archives of Bone and Joint Surgery* 2015 **3** 220–240.
- 40. Zantop T, Schumacher T, Diermann N, Schanz S, Raschke MJ & Petersen W.** Anterolateral rotational knee instability: role of posterolateral structures. Winner of the AGA-DonJoy award 2006. *Archives of Orthopaedic and Trauma Surgery* 2007 **127** 743–752. (<https://doi.org/10.1007/s00402-006-0241-3>)
- 41. LaPrade RF, Resig S, Wentorf F & Lewis JL.** The effects of grade III posterolateral knee complex injuries on anterior cruciate ligament graft force. A biomechanical analysis. *American Journal of Sports Medicine* 1999 **27** 469–475. (<https://doi.org/10.1177/03635465990270041101>)
- 42. Plaweski S, Belvisi B & Moreau-Gaudry A.** Reconstruction of the posterolateral corner after sequential sectioning restores knee kinematics. *Orthopaedic Journal of Sports Medicine* 2015 **3** 2325967115570560. (<https://doi.org/10.1177/2325967115570560>)
- 43. Kang KT, Koh YG, Nam JH, Jung M, Kim SJ & Kim SH.** Biomechanical evaluation of the influence of posterolateral corner structures on cruciate ligaments forces during simulated gait and squatting. *PLoS One* 2019 **14** e0214496. (<https://doi.org/10.1371/journal.pone.0214496>)
- 44. Wierer G, Milinkovic D, Robinson JR, Raschke MJ, Weiler A, Fink C, Herbert M & Kittl C.** The superficial medial collateral ligament is the major restraint to anteromedial instability of the knee. *Knee Surgery, Sports Traumatology, Arthroscopy* 2021 **29** 405–416. (<https://doi.org/10.1007/s00167-020-05947-0>)
- 45. Battaglia MJ 2nd, Lenhoff MW, Ehteshami JR, Lyman S, Provencher MT, Wickiewicz TL & Warren RF.** Medial collateral ligament injuries and subsequent load on the anterior cruciate ligament: a biomechanical evaluation in a cadaveric model. *American Journal of Sports Medicine* 2009 **37** 305–311. (<https://doi.org/10.1177/0363546508324969>)
- 46. Shen X, Qin Y, Zuo J, Liu T & Xiao J.** A systematic review of risk factors for anterior cruciate ligament reconstruction failure. *International Journal of Sports Medicine* 2021 **42** 682–693. (<https://doi.org/10.1055/a-1393-6282>)
- 47. Musahl V, Citak M, O'Loughlin PF, Choi D, Bedi A & Pearle AD.** The effect of medial versus lateral meniscectomy on the stability of the anterior cruciate ligament-deficient knee. *American Journal of Sports Medicine* 2010 **38** 1591–1597. (<https://doi.org/10.1177/0363546510364402>)
- 48. Grassi A, Di Paolo S, Lucidi GA, Macchiarola L, Raggi F & Zaffagnini S.** The contribution of partial meniscectomy to preoperative laxity and laxity after anatomic single-bundle anterior cruciate ligament reconstruction: in vivo kinematics with navigation. *American Journal of Sports Medicine* 2019 **47** 3203–3211. (<https://doi.org/10.1177/0363546519876648>)
- 49. Hoshino Y, Hiroshima Y, Miyaji N, Nagai K, Araki D, Kanzaki N, Kakutani K, Matsushita T & Kuroda R.** Unrepaired lateral meniscus tears lead to remaining pivot-shift in ACL-reconstructed knees. *Knee Surgery, Sports Traumatology, Arthroscopy* 2020 **28** 3504–3510. (<https://doi.org/10.1007/s00167-020-06007-3>)
- 50. Tapasvi S & Shekhar A.** Revision ACL reconstruction: principles and practice. *Indian Journal of Orthopaedics* 2021 **55** 263–275. (<https://doi.org/10.1007/s43465-020-00328-8>)
- 51. Musahl V, Nazzal EM, Lucidi GA, Serrano R, Hughes JD, Margheritini F, Zaffagnini S, Fu FH & Karlsson J.** Current trends in the anterior cruciate ligament part 1: biology and biomechanics. *Knee Surgery, Sports Traumatology, Arthroscopy* 2022 **30** 20–33. (<https://doi.org/10.1007/s00167-021-06826-y>)
- 52. Torres-Claramunt R, Pelfort X, Erquicia J, Gil-González S, Gelber PE, Puig L & Monllau JC.** Knee joint infection after ACL reconstruction: prevalence, management and functional outcomes. *Knee Surgery, Sports Traumatology, Arthroscopy* 2013 **21** 2844–2849. (<https://doi.org/10.1007/s00167-012-2264-3>)
- 53. Costa GG, Grassi A, Lo Presti M, Cialdella S, Zamparini E, Viale P, Filardo G & Zaffagnini S.** White blood cell count is the most reliable test for the diagnosis of septic arthritis after anterior cruciate ligament reconstruction: an observational study of 38 patients. *Arthroscopy* 2021 **37** 1522–1530.e2. (<https://doi.org/10.1016/j.arthro.2020.11.047>)
- 54. Wang C, Lee YH & Siebold R.** Recommendations for the management of septic arthritis after ACL reconstruction. *Knee Surgery, Sports Traumatology, Arthroscopy* 2014 **22** 2136–2144. (<https://doi.org/10.1007/s00167-013-2648-z>)
- 55. Kuršumović K & Charalambous CP.** Graft salvage following infected anterior cruciate ligament reconstruction: a systematic review and meta-analysis. *Bone and Joint Journal* 2016 **98-B** 608–615. (<https://doi.org/10.1302/0301-620X.98B5.35990>)
- 56. Pérez-Prieto D, Torres-Claramunt R, Gelber PE, Shehata TMA, Pelfort X & Monllau JC.** Autograft soaking in vancomycin reduces the risk of infection after anterior cruciate ligament reconstruction. *Knee Surgery, Sports Traumatology, Arthroscopy* 2016 **24** 2724–2728. (<https://doi.org/10.1007/s00167-014-3438-y>)
- 57. Won HH, Chang CB, Je MS, Chang MJ & Kim TK.** Coronal limb alignment and indications for high tibial osteotomy in patients undergoing revision ACL reconstruction. *Clinical Orthopaedics and Related Research* 2013 **471** 3504–3511. (<https://doi.org/10.1007/s11999-013-3185-2>)

- 58. Kendoff D, Koulalis D, Citak M, Voos J & Pearle AD.** Open wedge valgus tibial osteotomies: affecting the distinct ACL bundles. *Knee Surgery, Sports Traumatology, Arthroscopy* 2010 **18** 1501–1507. (<https://doi.org/10.1007/s00167-010-1073-9>)
- 59.** MARS Group, Cooper DE, Dunn WR, Huston LJ, Haas AK, Spindler KP, Allen CR, Anderson AF, DeBerardino TM, Lantz BBA, *et al.* Physiologic preoperative knee hyperextension is a predictor of failure in an anterior cruciate ligament revision cohort: a report from the MARS group. *American Journal of Sports Medicine* 2018 **46** 2836–2841. (<https://doi.org/10.1177/0363546518777732>)
- 60. Guimarães TM, Giglio PN, Sobrado MF, Bonadio MB, Gobbi RG, Pécora JR & Helito CP.** Knee hyperextension greater than 5° is a risk factor for failure in ACL reconstruction using hamstring graft. *Orthopaedic Journal of Sports Medicine* 2021 **9** 23259671211056325. (<https://doi.org/10.1177/23259671211056325>)
- 61. Sundemo D, Hamrin Senorski E, Karlsson L, Horvath A, Juul-Kristensen B, Karlsson J, Ayeni OR & Samuelsson K.** Generalised joint hypermobility increases ACL injury risk and is associated with inferior outcome after ACL reconstruction: a systematic review. *BMJ Open Sport and Exercise Medicine* 2019 **5** e000620. (<https://doi.org/10.1136/bmjsem-2019-000620>)
- 62. Mahmoud A, Torbey S, Honeywill C & Myers P.** Lateral extra-articular tenodesis combined with anterior cruciate ligament reconstruction is effective in knees with additional features of lateral, hyperextension, or increased rotational laxity: a matched cohort study. *Arthroscopy* 2022 **38** 119–124. (<https://doi.org/10.1016/j.arthro.2021.04.068>)
- 63. Benjaminse A, Gokeler A & van der Schans CP.** Clinical diagnosis of an anterior cruciate ligament rupture: a meta-analysis. *Journal of Orthopaedic and Sports Physical Therapy* 2006 **36** 267–288. (<https://doi.org/10.2519/jospt.2006.2011>)
- 64. Mulligan EP, Harwell JL & Robertson WJ.** Reliability and diagnostic accuracy of the Lachman test performed in a prone position. *Journal of Orthopaedic and Sports Physical Therapy* 2011 **41** 749–757. (<https://doi.org/10.2519/jospt.2011.3761>)
- 65. Lelli A, Di Turi RP, Spenciner DB & Dòmini M.** The "Lever Sign": a new clinical test for the diagnosis of anterior cruciate ligament rupture. *Knee Surgery, Sports Traumatology, Arthroscopy* 2016 **24** 2794–2797. (<https://doi.org/10.1007/s00167-014-3490-7>)
- 66. van Eck CF, van den Bekerom MP, Fu FH, Poolman RW & Kerkhoffs GM.** Methods to diagnose acute anterior cruciate ligament rupture: a meta-analysis of physical examinations with and without anaesthesia. *Knee Surgery, Sports Traumatology, Arthroscopy* 2013 **21** 1895–1903. (<https://doi.org/10.1007/s00167-012-2250-9>)
- 67. Lucidi GA, Dunn R, Wagala NN & Musahl V.** Editorial commentary: the importance of bony morphology in the anterior cruciate ligament-injured patient. *Arthroscopy* 2021 **37** 3166–3169. (<https://doi.org/10.1016/j.arthro.2021.05.043>)
- 68. Liu Z, Jiang J, Yi Q, Teng Y, Liu X, He J, Zhang K, Wang L, Teng F, Geng B, et al.** An increased posterior tibial slope is associated with a higher risk of graft failure following ACL reconstruction: a systematic review. *Knee Surgery, Sports Traumatology, Arthroscopy* 2022 **30** 2377–2387. (<https://doi.org/10.1007/s00167-022-06888-6>)
- 69. Grassi A, Macchiarola L, Urrizola-Barrientos F, Zicaro JP, Costa Paz M, Agravanti P, Dini F & Zaffagnini S.** Steep posterior tibial slope, anterior tibial subluxation, deep posterior lateral femoral condyle, and meniscal deficiency are common findings in multiple anterior cruciate ligament failures: an MRI case-control study. *American Journal of Sports Medicine* 2019 **47** 285–295. (<https://doi.org/10.1177/0363546518823544>)
- 70. Ziegler CG, DePhillipo NN, Kennedy MI, Dekker TJ, Dornan GJ & LaPrade RF.** Beighton score, tibial slope, tibial subluxation, quadriceps circumference difference, and family history are risk factors for anterior cruciate ligament graft failure: a retrospective comparison of primary and revision anterior cruciate ligament reconstructions. *Arthroscopy* 2021 **37** 195–205. (<https://doi.org/10.1016/j.arthro.2020.08.031>)
- 71. Baldini A, Anderson JA, Cerulli-Mariani P, Kalyvas J, Pavlov H & Sculco TP.** Patellofemoral evaluation after total knee arthroplasty. Validation of a new weight-bearing axial radiographic view. *Journal of Bone and Joint Surgery. American Volume* 2007 **89** 1810–1817. (<https://doi.org/10.2106/JBJS.E.00432>)
- 72. Osti L, Buda M, Osti R, Massari L & Maffulli N.** Preoperative planning for ACL revision surgery. *Sports Medicine and Arthroscopy Review* 2017 **25** 19–29. (<https://doi.org/10.1097/JSA.0000000000000140>)
- 73. Grassi A, Bailey JR, Signorelli C, Carbone G, Tchonang Wakam A, Lucidi GA & Zaffagnini S.** Magnetic resonance imaging after anterior cruciate ligament reconstruction: a practical guide. *World Journal of Orthopedics* 2016 **7** 638–649. (<https://doi.org/10.5312/wjo.v7.i10.638>)
- 74. Kosy JD & Mandalia VI.** Plain radiographs can be used for routine assessment of ACL reconstruction tunnel position with three-dimensional imaging reserved for research and revision surgery. *Knee Surgery, Sports Traumatology, Arthroscopy* 2018 **26** 534–549. (<https://doi.org/10.1007/s00167-017-4462-5>)
- 75. Marchant MH Jr, Willimon SC, Vinson E, Pietrobon R, Garrett WE & Higgins LD.** Comparison of plain radiography, computed tomography, and magnetic resonance imaging in the evaluation of bone tunnel widening after anterior cruciate ligament reconstruction. *Knee Surgery, Sports Traumatology, Arthroscopy* 2010 **18** 1059–1064. (<https://doi.org/10.1007/s00167-009-0952-4>)
- 76. Meuffels DE, Potters JW, Koning AH, Brown CH, Verhaar JA & Reijman M.** Visualization of postoperative anterior cruciate ligament reconstruction bone tunnels: reliability of standard radiographs, CT scans, and 3D virtual reality images. *Acta Orthopaedica* 2011 **82** 699–703. (<https://doi.org/10.3109/17453674.2011.623566>)
- 77. He X, Yang XG, Feng JT, Wang F, Huang HC, He JQ & Hu YC.** Clinical outcomes of the central third patellar tendon versus four-strand hamstring tendon autograft used for anterior cruciate ligament reconstruction: a systematic review and subgroup meta-analysis of randomized controlled trials. *Injury* 2020 **51** 1714–1725. (doi:10.1016/j.injury.2020.05.025.)
- 78. Xie X, Xiao Z, Li Q, Zhu B, Chen J, Chen H, Yang F, Chen Y, Lai Q & Liu X.** Increased incidence of osteoarthritis of knee joint after ACL reconstruction with bone-patellar tendon-bone autografts than hamstring autografts: a meta-analysis of 1,443 patients at a minimum of 5 years. *European Journal of Orthopaedic Surgery and Traumatology: Orthopédie Traumatologie* 2015 **25** 149–159. (<https://doi.org/10.1007/s00590-014-1459-3>)
- 79. Cruz AI Jr, Beck JJ, Ellington MD, Mayer SW, Pennock AT, Stinson ZS, VandenBerg CD, Barrow B, Gao B & Ellis HB.** Failure rates of autograft and allograft ACL reconstruction in patients 19 years of age and younger: a systematic review and meta-analysis. *JB & JS Open Access* 2020 **5** e20.00106. (<https://doi.org/10.2106/JBJS.OA.20.00106>)
- 80. Grassi A, Nitri M, Moulton SG, Marcheggiani Muccioli GM, Bondi A, Romagnoli M & Zaffagnini S.** Does the type of graft affect the outcome of revision anterior cruciate ligament reconstruction? A meta-analysis of 32 studies. *Bone and Joint Journal* 2017 **99-B** 714–723. (<https://doi.org/10.1302/0301-620X.99B6.BJJ-2016-0929.R2>)
- 81. Glogovac G, Schumaier AP & Grawe BM.** Return to sport following revision anterior cruciate ligament reconstruction in athletes: a systematic review. *Arthroscopy* 2019 **35** 2222–2230. (<https://doi.org/10.1016/j.arthro.2019.01.045>)

- 82. Matassi F, Giabbani N, Arnaldi E, Tripodo A, Bonaspetti G, Bait C, Ronga M, Di Benedetto P, Zaffagnini S, Jannelli E, et al.** Controversies in ACL revision surgery: Italian expert group consensus and state of the art. *Journal of Orthopaedics and Traumatology* 2022 **23** 32. (<https://doi.org/10.1186/s10195-022-00652-9>)
- 83. Bhatia S, Bell R, Frank RM, Rodeo SA, Bach BR, Cole BJ, Chubinskaya S, Wang VM & Verma NN.** Bony incorporation of soft tissue anterior cruciate ligament grafts in an animal model: autograft versus allograft with low-dose gamma irradiation. *American Journal of Sports Medicine* 2012 **40** 1789–1798. (<https://doi.org/10.1177/0363546511435637>)
- 84. Kraeutler MJ, Bravman JT & McCarty EC.** Bone-patellar tendon-bone autograft versus allograft in outcomes of anterior cruciate ligament reconstruction: a meta-analysis of 5182 patients. *American Journal of Sports Medicine* 2013 **41** 2439–2448. (<https://doi.org/10.1177/0363546513484127>)
- 85. Papageorgiou CD, Ma CB, Abramowitch SD, Clineff TD & Woo SL.** A multidisciplinary study of the healing of an intraarticular anterior cruciate ligament graft in a goat model. *American Journal of Sports Medicine* 2001 **29** 620–626. (<https://doi.org/10.1177/03635465010290051501>)
- 86. Tomita F, Yasuda K, Mikami S, Sakai T, Yamazaki S & Tohyama H.** Comparisons of intraosseous graft healing between the doubled flexor tendon graft and the bone-patellar tendon-bone graft in anterior cruciate ligament reconstruction. *Arthroscopy* 2001 **17** 461–476. (<https://doi.org/10.1053/jars.2001.24059>)
- 87. Park MJ, Lee MC & Seong SC.** A comparative study of the healing of tendon autograft and tendon-bone autograft using patellar tendon in rabbits. *International Orthopaedics* 2001 **25** 35–39. (<https://doi.org/10.1007/s002640000199>)
- 88. Kartus J, Stener S, Lindahl S, Eriksson BI & Karlsson J.** Ipsi- or contralateral patellar tendon graft in anterior cruciate ligament revision surgery. A comparison of two methods. *American Journal of Sports Medicine* 1998 **26** 499–504. (<https://doi.org/10.1177/03635465980260040401>)
- 89. Liden M, Ejerhed L, Sernert N, Bovaller A, Karlsson J & Kartus J.** The course of the patellar tendon after reharvesting its central third for ACL revision surgery: a long-term clinical and radiographic study. *Knee Surgery, Sports Traumatology, Arthroscopy* 2006 **14** 1130–1138. (<https://doi.org/10.1007/s00167-006-0167-x>)
- 90. Hunnicutt JL, Haynes WB, Slone HS, Prince JA, Boden SA & Xerogeanes JW.** Revision anterior cruciate ligament reconstruction with the all-soft tissue quadriceps tendon autograft has acceptable early and intermediate-term outcomes. *Arthroscopy* 2021 **37** 2848–2857. (<https://doi.org/10.1016/j.arthro.2021.03.035>)
- 91. Brinkman JC, Tummala SV, Moore ML & Economopoulos KJ.** All-soft tissue quadriceps tendon autograft in Revision Anterior Cruciate Ligament Reconstruction in Athletes: Comparison to Bone-Patellar Tendon-Bone Autograft With at Least a 2-Year Follow-up. In *American Journal of Sports Medicine* 2022 **50** 3770–3777. (<https://doi.org/10.1177/03635465221126523>)
- 92. Chee MY, Chen Y, Pearce CJ, Murphy DP, Krishna L, Hui JH, Wang WE, Tai BC, Salunke AA, Chen X, et al.** Outcome of patellar tendon versus 4-strand hamstring tendon autografts for anterior cruciate ligament reconstruction: a systematic review and meta-analysis of prospective randomized trials. *Arthroscopy* 2017 **33** 450–463. (<https://doi.org/10.1016/j.arthro.2016.09.020>)
- 93. Lansdown DA, Riff AJ, Meadows M, Yanke AB & Bach BR.** What factors influence the biomechanical properties of allograft tissue for ACL reconstruction? A systematic review. *Clinical Orthopaedics and Related Research* 2017 **475** 2412–2426. (<https://doi.org/10.1007/s11999-017-5330-9>)
- 94. Vangsness CT Jr & Dellamaggiora RD.** Current safety sterilization and tissue banking issues for soft tissue allografts. *Clinics in Sports Medicine* 2009 **28** 183–189. (<https://doi.org/10.1016/j.csm.2008.10.008>)
- 95. Buck BE, Malinin TI & Brown MD.** Bone transplantation and human immunodeficiency virus. An estimate of risk of acquired immunodeficiency syndrome (AIDS). *Clinical Orthopaedics and Related Research* 1989 **240** 129–136.
- 96. Fideler BM, Vangsness CT Jr, Lu B, Orlando C & Moore T.** Gamma irradiation: effects on biomechanical properties of human bone-patellar tendon-bone allografts. *American Journal of Sports Medicine* 1995 **23** 643–646. (<https://doi.org/10.1177/036354659502300521>)
- 97. Vopat BG, Gross DJ, Wong J, Golijanin P, Parada S, Tarakemeh A & Provencher MT.** Terminal sterilization of anterior cruciate ligament (ACL) allografts: a systematic review of outcomes. *Kansas Journal of Medicine* 2020 **13** 23–28. (<https://doi.org/10.17161/kjm.v13i1.13486>)
- 98. Malinin TI, Levitt RL, Bashore C, Temple HT & Mnaymneh W.** A study of retrieved allografts used to replace anterior cruciate ligaments. *Arthroscopy* 2002 **18** 163–170. (<https://doi.org/10.1053/jars.2002.30485>)
- 99. Jackson DW, Corsetti J & Simon TM.** Biologic incorporation of allograft anterior cruciate ligament replacements. *Clinical Orthopaedics and Related Research* 1996 **324** 126–133. (<https://doi.org/10.1097/00003086-199603000-00015>)
- 100. Fan D, Ma J & Zhang L.** Patellar tendon versus artificial grafts in anterior cruciate ligament reconstruction: a systematic review and meta-analysis. *Journal of Orthopaedic Surgery and Research* 2021 **16** 478. (<https://doi.org/10.1186/s13018-021-02624-x>)
- 101. Salem HS, Axibal DP, Wolcott ML, Vidal AF, McCarty EC, Bravman JT & Frank RM.** Two-stage revision anterior cruciate ligament reconstruction: a systematic review of bone graft options for tunnel augmentation. *American Journal of Sports Medicine* 2020 **48** 767–777. (<https://doi.org/10.1177/0363546519841583>)
- 102. Colatruglio M, Flanigan DC, Long J, DiBartola AC & Magnussen RA.** Outcomes of 1- versus 2-stage revision anterior cruciate ligament reconstruction: a systematic review and meta-analysis. *American Journal of Sports Medicine* 2021 **49** 798–804. (<https://doi.org/10.1177/0363546520923090>)
- 103. Chang MJ, Jeong JH, Chang CB, Kim YJ, Seo BK, Song MK, Kang T & Kang SB.** Revision surgery for failed anterior cruciate ligament reconstruction with extension deficiency. *Scandinavian Journal of Medicine and Science in Sports* 2018 **28** 2604–2610. (<https://doi.org/10.1111/sms.13274>)
- 104. Prall WC, Kusmenkov T, Fürmetz J, Haasters F, Mayr HO, Böcker W & Grote S.** Outcomes of revision anterior cruciate ligament reconstruction secondary to reamer-irrigator-aspirator harvested bone grafting. *Injury* 2019 **50** 467–475. (<https://doi.org/10.1016/j.injury.2018.12.020>)
- 105. Erickson BJ, Cvetanovich G, Waliullah K, Khair M, Smith P, Bach B & Sherman S.** Two-stage revision anterior cruciate ligament reconstruction. *Orthopedics* 2016 **39** e456–e464. (<https://doi.org/10.3928/01477447-20160324-01>)
- 106. Chahla J, Dean CS, Cram TR, Civitarese D, O'Brien L, Moulton SG & LaPrade RF.** Two-stage revision anterior cruciate ligament reconstruction: bone grafting technique using an allograft bone matrix. *Arthroscopy Techniques* 2016 **5** e189–e195. (<https://doi.org/10.1016/j.eats.2015.10.021>)
- 107. Yoon KH, Kim JS, Park SY & Park SE.** One-stage revision anterior cruciate ligament reconstruction: results according to preoperative bone tunnel diameter: five to

fifteen-year follow-up. *Journal of Bone and Joint Surgery. American Volume* 2018 **100** 993–1000. (<https://doi.org/10.2106/JBJS.17.01044>)

108. Haidar IM, Billières J, Saithna A, Rayes JE, Fradin T, Ngbilo C, Vieira TD, Cavaignac E & Sonnery-Cottet B. R outside-in drilling allows avoidance of two-stage surgery. *Arthroscopy Techniques* 2021 **10** e691–e696. (<https://doi.org/10.1016/j.eats.2020.10.057>)

109. Pioger C, Saithna A, Rayes J, Haidar IM, Fradin T, Ngbilo C, Vieira TD, Cavaignac E & Sonnery-Cottet B. Influence of preoperative tunnel widening on the outcomes of a single stage-only approach to every revision anterior cruciate ligament reconstruction: an analysis of 409 consecutive patients from the SANTI study group. *American Journal of Sports Medicine* 2021 **49** 1431–1440. (<https://doi.org/10.1177/0363546521996389>)

110. Marcacci M, Zaffagnini S, Iacono F, Neri MP, Loreti I & Petitto A. Arthroscopic intra- and extra-articular anterior cruciate ligament reconstruction with gracilis and semitendinosus tendons. *Knee Surgery, Sports Traumatology, Arthroscopy* 1998 **6** 68–75. (<https://doi.org/10.1007/s001670050075>)

111. Pelfort-López X, Gil-González S, Berjaoui-Najib H, et al. Surgical revision of the anterior cruciate ligament. One or two steps surgery? *Revista Española de Artroscopia y Cirugía Articular* 2020 **27** 233–243. (<https://doi.org/10.24129/j.reaca.27369.fs1906027>)

112. Philippe C, Marot V, Courtot L, Mesnier T, Reina N & Cavaignac E. One-stage ACL revision using a bone allograft plug for a semianatomic tibial tunnel that is too anterior. *Arthroscopy Techniques* 2022 **11** e463–e469. (<https://doi.org/10.1016/j.eats.2021.11.019>)

113. Demyttenaere J, Claes S & Bellemans J. One-stage revision anterior cruciate ligament reconstruction in cases with excessive tunnel osteolysis. Results of a new technique using impaction bone grafting. *Knee* 2018 **25** 1308–1317. (<https://doi.org/10.1016/j.knee.2018.08.015>)

114. Buda R, Ruffilli A, Di Caprio F, Ferruzzi A, Faldini C, Cavallo M, Vannini F & Giannini S. Allograft salvage procedure in multiple-revision anterior cruciate ligament reconstruction. *American Journal of Sports Medicine* 2013 **41** 402–410. (<https://doi.org/10.1177/0363546512471025>)

115. Herbenick M & Gambardella R. Revision anterior cruciate ligament reconstruction using a unique bioabsorbable interference screw for malpositioned tunnels. *American Journal of Orthopedics (Belle Mead, NJ)* 2008 **37** 425–428.

116. Schnetzke M, Vetter S, Linden PV, Grützner PA & von Recum J. Two-stage revision anterior cruciate ligament reconstruction using silicate-substituted calcium phosphate. *Arthroscopy Techniques* 2019 **8** e1239–e1246. (<https://doi.org/10.1016/j.eats.2019.06.015>)

117. Franceschi F, Papalia R, Del Buono A, Zampogna B, Diaz Balzani L, Maffulli N & Denaro V. Two-stage procedure in anterior cruciate ligament revision surgery: a five-year follow-up prospective study. *International Orthopaedics* 2013 **37** 1369–1374. (<https://doi.org/10.1007/s00264-013-1886-5>)

118. Uchida R, Toritsuka Y, Mae T, Kusano M & Ohzono K. Healing of tibial bone tunnels after bone grafting for staged revision anterior cruciate ligament surgery: a prospective computed tomography analysis. *Knee* 2016 **23** 830–836. (<https://doi.org/10.1016/j.knee.2016.04.012>)

119. Tischer T, Paul J, Pape D, Hirschmann MT, Imhoff AB, Hinterwimmer S & Feucht MJ. The impact of osseous malalignment and realignment procedures in knee

ligament surgery: a systematic review of the clinical evidence. *Orthopaedic Journal of Sports Medicine* 2017 **5** 2325967117697287. (<https://doi.org/10.1177/2325967117697287>)

120. Dean CS, Liechti DJ, Chahla J, Moatshe G & LaPrade RF. Clinical outcomes of high tibial osteotomy for knee instability: a systematic review. *Orthopaedic Journal of Sports Medicine* 2016 **4** 2325967116633419. (<https://doi.org/10.1177/2325967116633419>)

121. Gupta A, Tejpal T, Shanmugaraj A, Horner NS, Simunovic N, Duong A & Ayeni OR. Surgical techniques, outcomes, indications, and complications of simultaneous high tibial osteotomy and anterior cruciate ligament revision surgery: a systematic review. *HSS Journal* 2019 **15** 176–184. (<https://doi.org/10.1007/s11420-018-9630-8>)

122. Akoto R, Alm L, Drenck TC, Frings J, Krause M & Frosch KH. Slope-correction osteotomy with lateral extra-articular tenodesis and revision anterior cruciate ligament reconstruction is highly effective in treating high-grade anterior knee laxity. *American Journal of Sports Medicine* 2020 **48** 3478–3485. (<https://doi.org/10.1177/0363546520966327>)

123. Sonnery-Cottet B, Mogos S, Thauinat M, Archbold P, Fayard JM, Freychet B, Clechet J & Chambat P. Proximal tibial anterior closing wedge osteotomy in repeat revision of anterior cruciate ligament reconstruction. *American Journal of Sports Medicine* 2014 **42** 1873–1880. (<https://doi.org/10.1177/0363546514534938>)

124. Dejour D, Saffarini M, Demey G & Baverel L. Tibial slope correction combined with second revision ACL produces good knee stability and prevents graft rupture. *Knee Surgery, Sports Traumatology, Arthroscopy* 2015 **23** 2846–2852. (<https://doi.org/10.1007/s00167-015-3758-6>)

125. Grassi A, Zicaro JP, Costa-Paz M, Samuelsson K, Wilson A, Zaffagnini S, Condello V & ESSKA Arthroscopy Committee. Good mid-term outcomes and low rates of residual rotatory laxity, complications and failures after revision anterior cruciate ligament reconstruction (ACL) and lateral extra-articular tenodesis (LET). *Knee Surgery, Sports Traumatology, Arthroscopy* 2020 **28** 418–431. (<https://doi.org/10.1007/s00167-019-05625-w>)

126. Porter MD, Shadbolt B & Pomroy S. The augmentation of revision anterior cruciate ligament reconstruction with modified iliotibial band tenodesis to correct the pivot shift: a computer navigation study. *American Journal of Sports Medicine* 2018 **46** 839–845. (<https://doi.org/10.1177/0363546517750123>)

127. Perelli S, Gelber PE, Morales-Avalos R, Ronco S, Torres-Claramunt R, Espregueira-Mendes J & Monllau JC. Isolated lateral extra-articular tenodesis in ACL-deficient knees: in vivo knee kinematics and clinical outcomes. *Knee Surgery, Sports Traumatology, Arthroscopy* 2023. (<https://doi.org/10.1007/s00167-023-07344-9>)

128. Alm L, Krause M, Frosch KH & Akoto R. Preoperative medial knee instability is an underestimated risk factor for failure of revision ACL reconstruction. *Knee Surgery, Sports Traumatology, Arthroscopy* 2020 **28** 2458–2467. (<https://doi.org/10.1007/s00167-020-06133-y>)

129. Geeslin AG & LaPrade RF. Outcomes of treatment of acute grade-III isolated and combined posterolateral knee injuries: a prospective case series and surgical technique. *Journal of Bone and Joint Surgery. American Volume* 2011 **93** 1672–1683. (<https://doi.org/10.2106/JBJS.J.01639>)

130. Zhang H, Sun Y, Han X, Wang Y, Wang L, Alquhali A & Bai X. Simultaneous reconstruction of the anterior cruciate ligament and medial collateral ligament in patients with chronic ACL-MCL lesions: a minimum 2-year follow-up study. *American Journal of Sports Medicine* 2014 **42** 1675–1681. (<https://doi.org/10.1177/0363546514531394>)

131. Yoon KH, Lee HW, Park SY, Yeak RDK, Kim JS & Park JY. Meniscal allograft transplantation after anterior cruciate ligament reconstruction can improve knee stability: a

comparison of medial and lateral procedures. *American Journal of Sports Medicine* 2020 **48** 2370–2375. (<https://doi.org/10.1177/0363546520938771>)

132. Saltzman BM, Meyer MA, Weber AE, Poland SG, Yanke AB & Cole BJ. Prospective clinical and radiographic outcomes after concomitant anterior cruciate ligament reconstruction and meniscal allograft transplantation at a mean 5-year follow-up. *American Journal of Sports Medicine* 2017 **45** 550–562. (<https://doi.org/10.1177/0363546516669934>)

133. Andriolo L, Filardo G, Kon E, Ricci M, Della Villa F, Della Villa S, Zaffagnini S & Marcacci M. Revision anterior cruciate ligament reconstruction: clinical outcome and evidence for return to sport. *Knee Surgery, Sports Traumatology, Arthroscopy* 2015 **23** 2825–2845. (<https://doi.org/10.1007/s00167-015-3702-9>)

134. Mohan R, Webster KE, Johnson NR, Stuart MJ, Hewett TE & Krych AJ. Clinical outcomes in Revision Anterior Cruciate Ligament Reconstruction: a Meta-analysis. *Arthroscopy* 2018 **34** 289–300. (<https://doi.org/10.1016/j.arthro.2017.06.029>)

135. Grassi A, Zaffagnini S, Marcheggiani Muccioli GM, Neri MP, Della Villa S & Marcacci M. After revision anterior cruciate ligament reconstruction, who returns to sport? A systematic review and meta-analysis. *British Journal of Sports Medicine* 2015 **49** 1295–1304. (<https://doi.org/10.1136/bjsports-2014-094089>)

136. Grassi A, Kim C, Marcheggiani Muccioli GM, Zaffagnini S & Amendola A. What is the mid-term failure rate of revision ACL reconstruction? A systematic review. *Clinical Orthopaedics and Related Research* 2017 **475** 2484–2499. (<https://doi.org/10.1007/s11999-017-5379-5>)

137. Grassi A, Zaffagnini S, Marcheggiani Muccioli GM, Roberti Di Sarsina T, Urrizola Barrientos F & Marcacci M. Revision anterior cruciate ligament reconstruction does not prevent progression in one out of five patients of osteoarthritis: a meta-analysis of prevalence and progression of osteoarthritis. *Journal of ISAKOS* 2016 **1** 16–24. (<https://doi.org/10.1136/jisakos-2015-000029>)