

# The third compartment of the knee: an update from diagnosis to treatment

David Barrett<sup>1,2</sup> and Angela Brivio<sup>2,3</sup>

<sup>1</sup>School of Engineering Science, University of Southampton, United Kingdom

<sup>2</sup>King Edward VII Hospital, London, UK

<sup>3</sup>Instituto Clinico Citta Studi, Milan, Italy

Correspondence  
should be addressed  
to D Barrett

**Email**

[Davidbarrett58@outlook.com](mailto:Davidbarrett58@outlook.com)

- The anterior part (third space) of the knee appears important in the soft tissue functional outcome following knee replacement surgery.
- Native patellofemoral kinematics are complex and variable, and further understanding has led to prosthetic redesign.
- Attention to soft tissue tension anteriorly (balancing the third space) during knee replacement may maximise post-operative function and avoid issues with understuffing and overstuffing.
- Patellofemoral compression forces may now be measured dynamically during knee replacement, allowing an objective approach to balancing the third space.

## Keywords

- ▶ Patellofemoral joint
- ▶ patellofemoral pressure
- ▶ anterior knee pain
- ▶ knee replacement
- ▶ patellofemoral kinematics
- ▶ functional outcome

*EFORT Open Reviews*  
(2023) **8**, 313–318

## Introduction

There is no doubt that total knee replacement has become a successful, reliable and life-changing intervention for many thousands of patients, with established survival figures above 95% over 15 years (1). More recently, however, attention has turned to the quality or functionality patients experience after total knee replacement. It appears that up to 20% of patients experience significant discomfort or pain around their knee that precludes their normal activities of daily living (2). Activities such as stair climbing or descent, kneeling or twisting appear to give soft tissue pain, principally around the anterior portion of the knee (3, 4). The concentration of pain and discomfort around the anterior structures of the knee has led researchers and surgeons to focus primarily on these tissues that make up the extensor mechanism of the joint and the surrounding stabilising structures, collectively called the ‘third space of the knee’.

## The third space

The name third space derives from the historic focus of knee surgeons on the first and second spaces of the joint, namely the flexion and extension gaps of the tibiofemoral joint. Balancing these two spaces is key to achieving

stability and function in a total knee replacement and is accepted as part of the surgical process for total knee implantation. The third space is now becoming established as an important part of knee surgery, particularly in its role in determining the functionality and satisfaction of the patient post-surgery.

Anatomically, the third space consists of the extensor hood, the patellofemoral joint, the medial and lateral retinacula fibres, the surrounding soft tissues and the quadriceps muscle. These tissues and the synovium within the capsule of the joint are highly innervated and provide the patient with significant sensory feedback both for pain and function during the activities of daily life (5), and abnormal tissue tension in the third space following knee replacement has been implicated in the poor functional outcome in some patients (6). It is established that surgeons will routinely balance the first and second spaces (flexion and extension gaps); more recently, it is hoped also they will balance the third space in order to address the significant proportion of patients who have compromised functional results after knee replacement.

## Patellofemoral mechanics

Patellofemoral mechanics are complex and variable depending on the activity undertaken and are a result

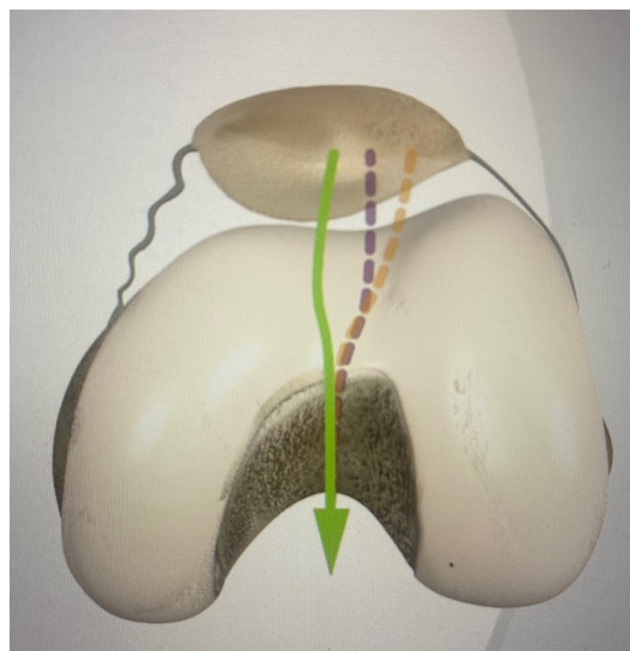
of a combination of anatomical bony structures and the surrounding soft tissue and muscle structures that encircle the mobile patella. As patellofemoral function is a dynamic three-dimensional moving concern, it has only been possible recently to characterise the loading and motion of the third space with instrumented jigs and dynamic computational finite element analysis (7). The patellofemoral joint appears to have varying constraints and loading, dependent on the degree of flexion of the joint. At 0–30° of flexion, the patella is lightly constrained by the relatively flat trochlea and is guided by the medial and lateral retinacular ligaments to the deepening trochlea groove, delivering the patella to the top of the intercondylar notch of the knee at about 30° (8). At this point progressively onwards, the patella becomes more heavily constrained by anatomical bony features of the intercondylar notch and at the same time becomes more heavily loaded as the knee increases in flexion. The medial and lateral retinacular fibres become relatively loose after 30°. The path or track of the patella in early flexion to 30° is often variable, dependent on factors such as the rotation of the foot at heel strike and the force within the quads muscle. It appears the function of the retinacular ligaments is to guide the patella from its variable starting point in extension to the apex of the intercondylar notch where it will become more heavily constrained and heavily loaded (Fig. 1). The variable position the patella must adopt in extension secondary to different quads forces and changing rotation of the leg is facilitated by the relatively flat low constraint of the trochlea at this point.

From 30° onwards as the patella becomes progressively more loaded, it has an increasing requirement for higher constraint, and this is provided by the deepening intercondylar groove and the patella track becomes more regularised and predictable.

Understanding these features and the requirement for low constraint in early flexion has led to a redesign of several total knee replacements with a lower, shallower trochlea and with less prominent trochlea shoulders to avoid impinging on the sensitive extensor hood tissues. This understanding has led to a move away from the concept of ‘capturing the patella’ that led to the designing of deeper, unphysiological trochlea grooves for knee replacements in the past (9) (Fig. 2).

### Balancing the third space

Just as surgeons have realised the importance of balancing the first and second (flexion and extension) spaces to achieve stability and appropriate soft tissue tension, it is increasingly clear that in order to maintain the function of the extensor apparatus and avoid unphysiological soft tissue tension, the third space should also be balanced in total knee replacement. It is important to maintain the



**Figure 1**

Three different possible paths for patellofemoral movement depending on the starting rotation of the foot. The guiding role of the retinacular ligaments is clear.



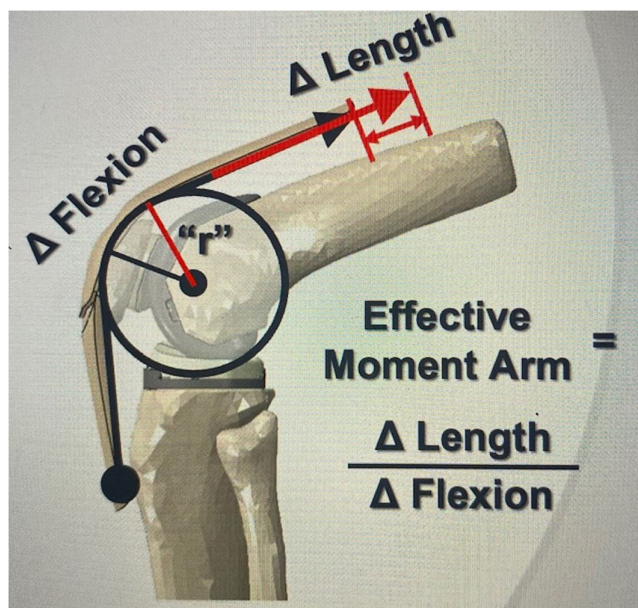
**Figure 2**

Redesign of trochlea to reduce soft tissue impingement (yellow highlights older design).

anterior offset which allows the extensor mechanism to generate appropriate extensor power (Fig. 3).

Surgeons do not routinely measure the thickness of bone they remove in the anterior cut or trochlea resection during the preparation for knee replacement. However, this is vital in balancing the third space and reproducing the function of the anterior offset without over-tightening the sensitive structures around the third space to result in anterior knee pain. The average thickness of the trochlea in a knee replacement is about 6 mm. If surgeons remove 10 mm thickness of host bone from the trochlea and replace it with 6 mm thickness of implanted trochlea, understuffing of the third space has occurred by 4 mm with a reduction of the anterior offset. As a result, the quadriceps mechanism will have to work 2.1 times harder to generate similar force. It is thought these patients report fatigue and lack of power when undertaking functional tasks as the quadriceps mechanism has to work harder to generate similar movement (10) (Fig. 4). If surgeons remove 2 mm of bone and replace it with 6 mm of metal trochlea, they have overstuffed the third space by 4 mm. This results in 1.7 times more soft tissue tension (11) (Fig. 5). It is believed these patients present with tightness and discomfort on functional activities.

In order to avoid overstuffing or understuffing the third space, surgeons must clearly aim to resect the same amount of native host bone as they intend to replace with the thickness of the implant trochlea. The amount of bone to be removed can be estimated prior to resection by using the tibial stylus in the anterior slot of the cutting guide (Fig. 6).

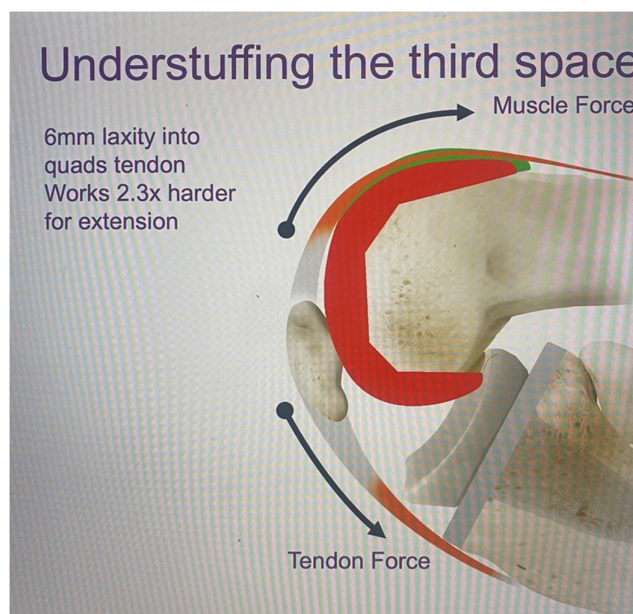

**Figure 3**  
Anterior offset allows effective function of the extensor hood.

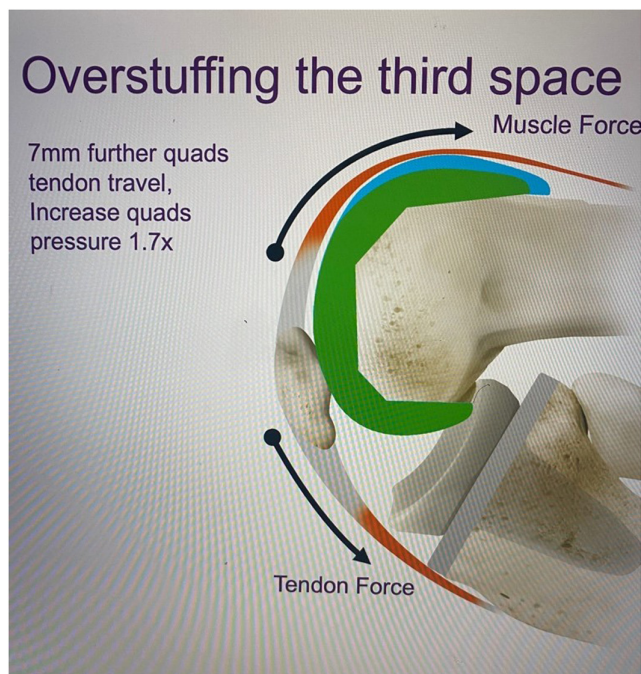The thickness of the trochlea resection is determined by the sizing and positioning of the femoral implant. However, moving the femoral implant anteriorly in order to reduce trochlea resection will also have an undesirable effect by increasing the flexion space. Equally, moving the implant posteriorly in order to increase trochlea resection will decrease and tighten the flexion space. Surgeons may avoid this unwanted complication by using a ‘posterior up’ method of positioning the femoral cutting block.

By using the ‘posterior up’ method of pinning the femoral cutting block, the posterior resection and flexion space remains constant, whilst the trochlea resection can be determined by changing the femoral size (Fig. 7). When the femoral size is decreased to increase trochlea resection, there are no issues; however, if the femoral size is increased to reduce trochlea resection, there is a technical risk of medial to lateral overhang. Therefore, the narrow version of the increased femoral size should be selected.

By this method, surgeons may achieve a balance of the third space without compromising the balance of the first and second spaces. For surgeons who do not resurface the patella, accurate restoration of the trochlea thickness or balancing the third space is achieved with the trochlea resection alone. It appears that within  $\pm 2$  mm of the native trochlear thickness, there is not a discernible effect on the extensor apparatus. However, when the inaccuracy of the resection or failure to balance the third space reaches  $\pm 4$  mm, there is a significant effect on the function and on the soft tissue tension in the third space (11). Accepting  $\pm 2$



**Figure 4**  
Accurate femoral sizing with appropriate trochlea resection in green. Understuffing or over-resection of the trochlea and failure to balance the third space in red.

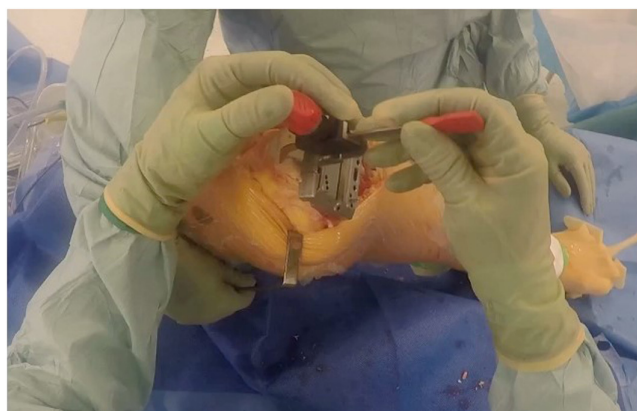

**Figure 5**

Accurate femoral sizing with appropriate trochlea resection in green. Overstuffing or under-resection of the trochlea and failure to balance the third space in blue.

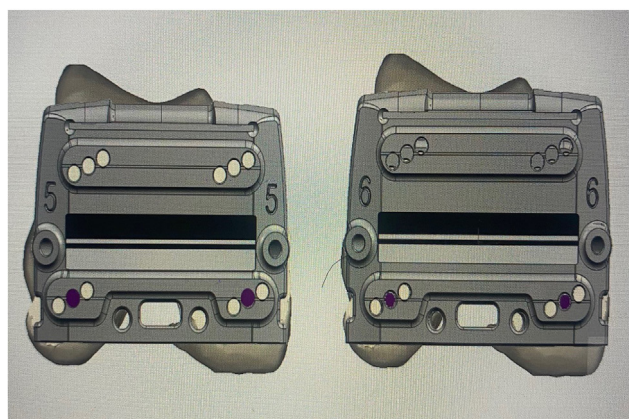
mm for balancing the third space is very similar to the  $\pm 2$ mm accepted for balancing the first and second spaces of the flexion and extension gaps in the knee.

Surgeons who resurface the patella have a second factor to consider in balancing the third space. Most will perform a measured resection of the patella, removing as much patella bone as they intend to replace with the patella prosthesis, i.e. 9-mm resection of the native patella is required for a 9-mm polyethylene button. It is also possible to consider fine-tuning or more accurately balancing the



**Figure 6**

Using the tibial stylus to measure projected anterior resection.



**Figure 7**

Use of posterior pins (purple) to position the femoral cutting guide. Using this method, size changes (i.e. size 5 to 6) directly affect the trochlea resection, without compromising the flexion space.

third space by changing the depth of resection of the patella. For instance, if in choosing a femoral size the surgeon realises the third space is 2 mm understuffed, they would have the option of under-resecting the patella cut by 2 mm, removing 7 mm rather than 9 mm therefore restoring the balance of the third space perfectly. The option of using the patella resection to balance the third space more accurately has led to a developing interest in trying to record the dynamic forces that occur over the implanted trochlea and to modify the patella resection in both depth and angle to try and reproduce the native pressures in the patello femoral joint. By reproducing the native patellofemoral pressures that existed before knee replacement, it follows that the tension in the surrounding tissues of the third space would also be similar to that before surgery. In this way, it is hoped that the anterior knee pain and the loss of function that troubles 20% of knee arthroplasty patients might be addressed.

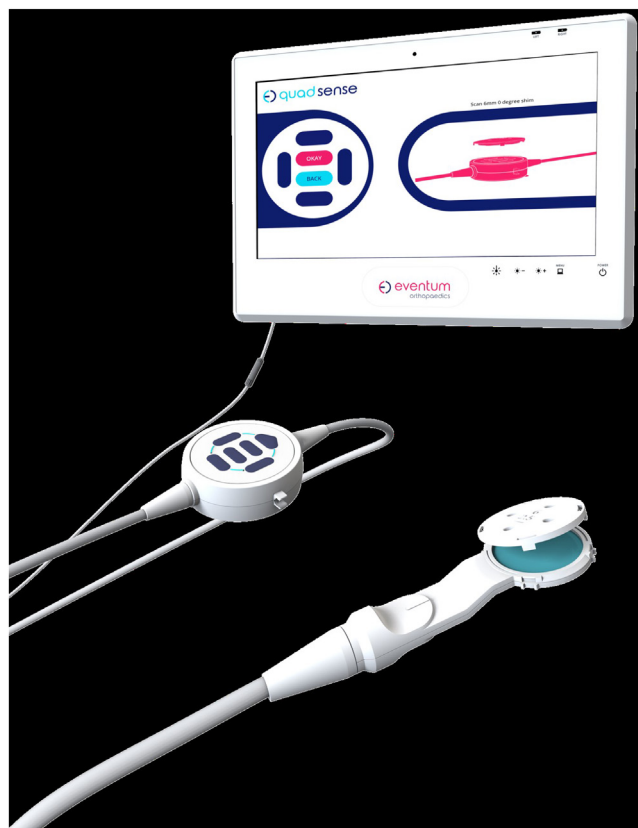### Dynamic measurement of the intraoperative patellofemoral contact forces

It is clear from our recent understanding of the dynamic and variable nature of the patellofemoral mechanics (described earlier) that the loading of the patellofemoral joint is extremely changeable and highly dependent on the flexion angle and the loading of the knee. Contact forces will also vary in the different quadrants of the patella articulation. Unlike other aspects of knee surgery, there is not one single metric that accurately describes the patellofemoral function. In order to accurately reproduce and balance the third space, detailed information is required regarding the patellofemoral loading and the pattern of that loading

as the knee flexes. The third space may be balanced in a similar way to the first and second spaces by ensuring that resected bone is accurately replaced by prosthetic material. However, the dynamic and changing nature of the patellofemoral joint means information regarding the loading of the third space between 0 and 140° would be of benefit if the soft tissue tensions around the third space are to be accurately reproduced throughout the whole range of movements of the knee.

A four-quadrant pressure sensor device for the patella has been developed, which allows accurate recording of patellofemoral pressure throughout the range of movement in the knee (Quadsense, Eventum Orthopaedics Ltd, Ilkley, UK). The sensor is shaped as the patella button and contains four pressure sensors in the superior, inferior, medial and lateral sections. The sensor requires a 6-mm resection of patella bone and is connected to a device outside the operative field to allow the surgeon to study the resultant pressures in each of the quadrants throughout a range of flexion in the knee (Fig. 8).

At the commencement of the procedure, the surgeon first makes a 6-mm resection of the patella and records the pattern, distribution and pressure of patellofemoral forces in the native knee through flexion and extension

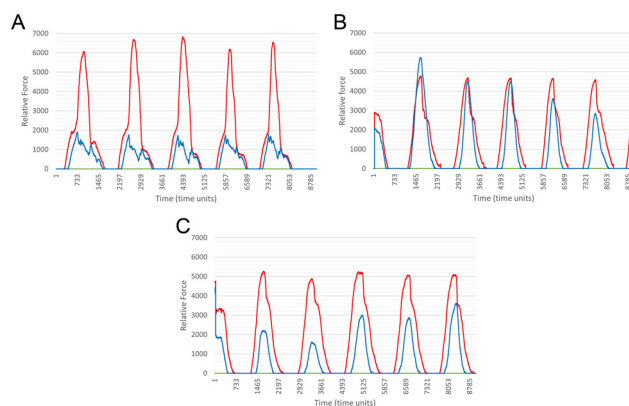


**Figure 8**  
Patella sensor device for four-quadrant monitoring (Quadsense).

prior to operative surgery. Laboratory studies and tests *in vivo* reveal that the patellofemoral forces are very individual and vary between patients but are consistent and reproducible in pattern and amplitude when repeated studies are performed on the same patients (12) (Fig. 9A).

Knee replacement is then undertaken, and the tibia and femur are implanted with the appropriate tibial polyethylene insert. All efforts are made to complete an accurate trochlea resection. The sensor device is then repositioned on the cut surface of the patella and the knee is flexed and extended again to repeat the measurements and now the knee has been replaced. Characteristically, the pattern and the amplitude of the pressure measurements are commonly very different following knee replacement (Fig. 9B). The surgeon now has an opportunity to alter the patella resection in both depth and angle in order to reproduce the pattern and amplitude of the native knee recording taken prior to implantation. The aim therefore is to reproduce what existed before in terms of pressure patterns and pressure distribution in order to replicate as accurately as possible the patients' physiological third space pressures and movements. In this way, it is hoped that the third space function will be maximised, avoiding over-tensioning that is caused by overstuffing or loss of function that follows understuffing.

Real time recordings of patello femoral pressures in an operative case are shown in Fig. 9A, B and C. The initial recording of the native state (Fig. 9A) shows mostly patellofemoral pressure on the lateral facet in red with a much lesser component in the superior section in blue. The graph records several cycles of flexion and extension,



**Figure 9**  
(A) Repeatable pattern of patellofemoral forces through five flexion and extension cycles. Quadrants: yellow – inferior, green – medial, red – lateral, and blue – superior. (B) Patellofemoral pressures measured following TKA through five cycles of flexion and extension. Quadrants: yellow – inferior, green – medial, red – lateral, and blue – superior. (C) Patellofemoral pressures measured after corrective resection of patella to normalise third space pressure. Quadrants: yellow – inferior, green – medial, red – lateral, and blue – superior.

showing that although the patterns are individual, they remain consistent throughout the assessment. **Figure 9B** shows the effect of knee replacement with the patella sensor recording similar lateral pressures in red but now an overpressure of the superior facet (blue) which has risen to equal the pressure in the lateral facet. The surgeon has an opportunity now to address this change and reproduce the patellofemoral pressures that the patient was accustomed to as normal before knee replacement. By taking an extra 2-mm superior angled cut with a special patella cutting guide, the surgeon can address the overpressure on the superior facet (blue) to reduce it to the level which existed in the pre-operative state (**Fig. 9C**). As such, it is hoped that the pressures and tensions of the soft tissues around the third space can be accurately controlled and returned to the preoperative levels perhaps addressing the ongoing feature of anterior knee pain in 20% of knee replacement individuals.

## Conclusion

Currently, whilst knee replacement surgery enjoys longevity, it is accepted that functionality still is challenging. The advent of significant amounts of anterior knee pain in our patients leads us to focus more accurately on the function of the soft tissue envelope and the articular structures that makes up the third space.

It is apparent that balancing the third space may have been relatively neglected until recently and renewed focus on the soft tissue tensions, anterior offset and function of the extensor hood may lead us to adapt the surgical process to ensure the third space is not overstuffed, leading to soft tissue pain, or understuffed, leading to loss of function.

More recently, it has been possible to monitor and record the real-time dynamic patellofemoral forces in each quadrant of the patella during surgery. By altering the patella resection, it is apparent we may address abnormalities in patellofemoral loading that appear to occur after total knee replacement. It is hoped this would offer a genuine way forward in addressing the 20% of patients who feel compromised functionally after total knee replacement.

### ICMJE conflict of interest statement

The authors confirm that there are no conflicting interests in producing the article.

### Funding statement

No funding was received for this manuscript.

### References

- Ben-Shlomo Y, Blom A, Boulton C, Brittain R, Clark E, Dawson-Bowling S, Deere K, Esler C, Espinoza O, et al.** *The National Joint Registry 19th Annual Report 2022* [Internet]: London: National Joint Registry 2022.
- Scott CEH, Howie CR, MacDonald D & Biant LC.** Predicting dissatisfaction following total knee replacement: a prospective study of 1217 patients. *Journal of Bone and Joint Surgery. British Volume* 2010 **92** 1253–1258. (<https://doi.org/10.1302/0301-620X.92B9.24394>)
- Khan M, Osman K, Green G & Haddad FS.** The epidemiology of failure in total knee arthroplasty: avoiding your next revision. *Bone and Joint Journal* 2016 **98–B**(Supplement A) 105–112. (<https://doi.org/10.1302/0301-620X.98B1.36293>)
- Tippett SR, Mang J, Dwyer KA, Lesko J & O'Dell T.** Collecting data with Palm technology: comparing preoperative expectations and postoperative satisfaction in patients undergoing total knee arthroplasty. *Journal of Bone and Joint Surgery. American Volume* 2010 **92**(Supplement 2) 59–67. (<https://doi.org/10.2106/JBJS.J.00827>)
- Dye SF.** The pathophysiology of patellofemoral pain: a tissue homeostasis perspective. *Clinical Orthopaedics and Related Research* 2005 **436** 100–110. (<https://doi.org/10.1097/01.blo.0000172303.74414.7d>)
- Scuderi GR, Insall JN & Scott NW.** Patellofemoral pain after total knee arthroplasty. *Journal of the American Academy of Orthopaedic Surgeons* 1994 **2** 239–246. (<https://doi.org/10.5435/00124635-199409000-00001>)
- Ali AA, Mannen EM, Rullkoetter PJ & Shelburne KB.** In vivo comparison of medialized dome and anatomic patellofemoral geometries using subject-specific computational modeling. *Journal of Orthopaedic Research* 2018 **36** 1910–1918. (<https://doi.org/10.1002/jor.23865>)
- Dejour D & Saggin PRF.** *Disorders of the Patellofemoral Joint. Chapter 61.* (<https://doi.org/10.1016/B978-1-4377-1503-3.00061-5>)
- Mannen EM, Ali AA, Dennis DA, Haas BD, Rullkoetter PJ & Shelburne KB.** Influence of component geometry on patellar mechanics in posterior-stabilized rotating platform total knee arthroplasty. *Journal of Arthroplasty* 2019 **34** 974–980. (<https://doi.org/10.1016/j.arth.2019.01.013>)
- Clary CW, Ali AA, Wright AP, FitzPatrick CK & Rullkoetter PJ.** *The effect of surgical variability and patella geometry on extensor efficiency in total knee replacement.* ORS Annual Meeting, Poster #1959; 2014.
- Shalhoub S, Fitzwater F, Clary C & Maletsky L.** *Patellofemoral thickness influences patellar kinematics and extensor efficiency.* ORS 2016. Annual Meeting Poster No. 0034.
- Brivio A, Barrett D, Gong MF, Watson A, Naybour S & Plate JF.** Dynamic measurement of patellofemoral compression forces: A novel method for patient-specific patella resurfacing in total knee replacement. *Applied Sciences* **12.** (<https://doi.org/10.3390/app122010584>)