

Current understanding of tandem spinal stenosis: epidemiology, diagnosis, and surgical strategy

Qiushi Bai^{1,*}, Yuanyi Wang^{2,*}, Jiliang Zhai¹, Jigong Wu³, Yan Zhang⁴ and Yu Zhao¹

¹Department of Orthopaedics, Peking Union Medical College Hospital, Chinese Academy of Medical Sciences & Peking Union Medical College, Beijing, China

²Department of Spinal Surgery, The First Hospital of Jilin University, Changchun, China

³Chinese People's Liberation Army Strategic Support Force Characteristic Medical Center, Beijing, China

⁴Department of Radiology, Peking Union Medical College Hospital, Chinese Academy of Medical Sciences & Peking Union Medical College, Beijing, China

* (Q Bai, Y Wang contributed equally to this work)

Correspondence should be addressed to Y Zhang or Y Zhao

Email

zypumch@163.com or zhaoyupumch@163.com

- Tandem spinal stenosis (TSS) is defined as the concomitant occurrence of stenosis in at least two or more distinct regions (cervical, thoracic, or lumbar) of the spine and may present with a constellation of signs and symptoms. It has four subtypes, including cervico-lumbar, cervico-thoracic, thoraco-lumbar, and cervico-thoraco-lumbar TSS. The prevalence of TSS varies depending on the different subtypes and cohorts.
- The main aetiologies of TSS are spinal degenerative changes and heterotopic ossification, and patients with developmental spinal stenosis, ligament ossification, and spinal stenosis at any region are at an increased risk of developing TSS.
- The diagnosis of TSS is challenging. The clinical presentation of TSS could be complex, concealed, or severe, and these features may be confusing to clinicians, resulting in an incomplete or delayed diagnosis. Additionally, a consolidated diagnostic criterion for TSS is urgently required to improve consistency across studies and form a basis for establishing treatment guidelines.
- The optimal treatment option for TSS is still under debate; areas of controversies include choice of the decompression range, choice between simultaneous or staged surgical patterns, and the order of the surgeries.
- The present study reviews publications on TSS, consolidates current awareness on prevalence, aetiologies, potential risk factors, diagnostic dilemmas and criteria, and surgical strategies based on TSS subtypes. This is the first review to include thoracic spinal stenosis as a candidate disorder in TSS and aims at providing the readers with a comprehensive overview of TSS.

Keywords

- ▶ tandem spinal stenosis
- ▶ diagnosis criteria
- ▶ surgery

EFORT Open Reviews
(2022) 7, 587–598

Introduction

Spinal stenosis is characterised by a reduction in the cross-sectional area of the spinal canal that leads to upper or lower motor neuron deficits and related neurological symptoms depending on the location of the compression. Spinal stenosis can affect more than one level in any segments (1, 2, 3). Tandem spinal stenosis (TSS) refers to concomitant stenosis that affects at least two regions (4).

TSS was first reported in 1957 by Brain *et al.*, who described a patient with cervical spinal stenosis (CSS) and lumbar spinal stenosis (LSS) (5). Subsequently, cases of seven patients with concomitant CSS and LSS were reported by Teng and Papatheodorou (6). The term ‘tandem spinal stenosis’ was first proposed by Dagi *et al.*

to distinguish patients with concurrent cervicolumbar TSS (CLTSS) (4). In 1962, Koizumi reported a case of CSS and thoracic spinal stenosis (ThSS) (7) that broadened the scope of TSS by adding ThSS to stenotic candidate regions (8, 9). To date, TSS is defined as distinct concomitant stenosis in at least two regions of the cervical, thoracic, and lumbar spine and may present with both upper and lower motor neuron symptoms and neurogenic claudication (10, 11, 12, 13).

TSS is classified into four subtypes according to the stenotic region: cervicothoracic TSS (CTTSS), thoracolumbar TSS (TLTSS), cervico-thoraco-lumbar TSS (CTLTSS), and CLTSS (14) (Fig. 1). It presents with complicated manifestations that cause difficulties in both diagnosis and treatment. Herein, we review the current understanding

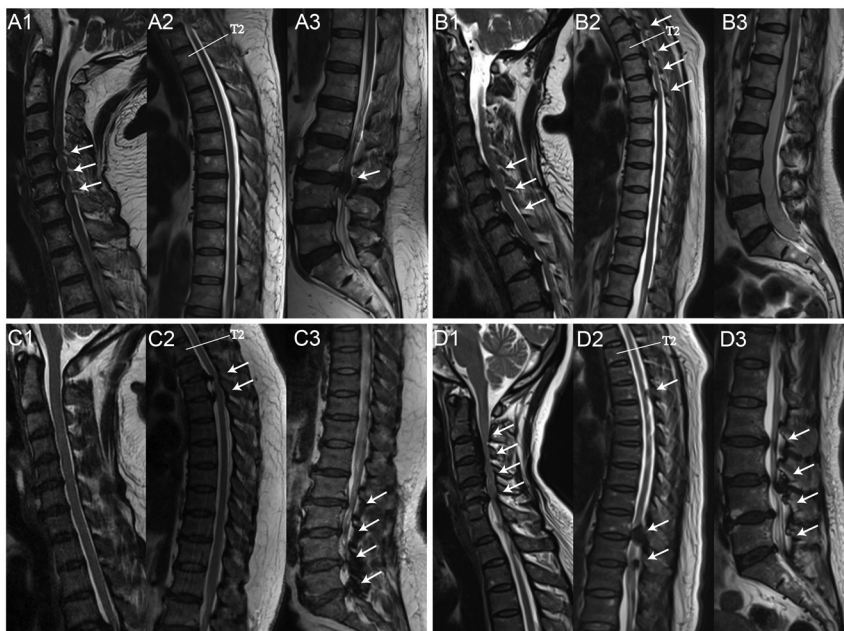


Figure 1

The representative MRI of the subtypes of TSS. The whole spine MRI of a CLTSS patient shows CSS at C4-7 (A1, arrows) and LSS at L3-4 (A3, arrows); In the MRI of a CTTSS patient, extensive hypertrophy of posterior longitudinal ligament causes CSS (B1, arrows) and ThSS (B2, arrows), the stenotic change affects C4-T5 (B1, 2); In the MRI of a TLTSS patient, T3-5 ThSS (C2, arrows) and L2-S1 LSS (C3, arrows) occurs concomitantly; A CTLTSS patient has concurrent C2-6 CSS (D1, arrows), T4-5, T10-12 ThSS (D2, arrows), and L2-S1 LSS (D3, arrows), which are caused by heterotopic ossification and degeneration changes (D1-3). CSS, cervical spinal stenosis; CLTSS, cervico-lumbar tandem spinal stenosis; CTTSS, cervico-thoracic tandem spinal stenosis; CTLTSS, cervico-thoraco-lumbar tandem spinal stenosis; LSS, lumbar spinal stenosis; TSS, tandem spinal stenosis; ThSS, thoracic spinal stenosis; TLTSS, thoraco-lumbar tandem spinal stenosis.

of TSS including the subtypes with ThSS, aimed to clarify the epidemiology and diagnosis of TSS and to discuss surgical strategies for the different subtypes of TSS.

Prevalence of TSS

Many studies have attempted to determine the prevalence of TSS (Table 1). According to previous reports, the incidence of radiological and symptomatic TSS are 8–60% and 5–28%, respectively (2, 4, 12, 15, 16, 17). However, these data do not reflect the precise status. Based on studies of volunteers and unrelated patients, the incidence of CLTSS is 0.12–11% in the general population (16, 17, 18, 19, 20). However, the incidence of other subtypes was not mentioned. In anatomical studies, two research groups examined the prevalence of TSS by measuring the same collection of cadavers. The incidence of CLTSS in the cadavers ranged from 0.9 to 5.4% (21), and the incidence of CTTSS and TLTSS is 1 and 1.42%, respectively (22, 23). Limited by the cadaveric nature, despite the good consistency, the results can merely reflect TSS caused by developmental or acquired narrowing of bony structures (24). Most prevalence studies on TSS are based on patients with spinal stenosis. The radiological CLTSS incidence among patients with CSS or LSS is 32.2–84.6%, and the symptomatic CLTSS incidence was 0.88–33.3% (25, 26, 27, 28, 29, 30, 31, 32). The incidence of radiological CTTSS and TLTSS ranges from 12.2 to 70% among patients with spinal stenosis, and the incidence of radiological CTLTSS among patients with spinal stenosis is 10–25.7% (14, 33, 34).

Aetiology and potential risk factors of TSS

TSS has two main aetiologies that can lead to stenosis in combination or separately. Spondylotic changes caused by degeneration is the main cause of LSS and CSS. CLTSS is caused by degenerative spondylosis due to aging, lifestyle, and other stimuli. The other aetiology is heterotopic ossification, including ossification of the posterior longitudinal ligament (OPLL) and the ligamentum flavum (OLF), which are commonly seen in ThSS and some patients with CSS (7, 35). CTTSS, TLTSS, and CTLTSS are more likely to be caused by heterotopic ossification, which is associated with genetic abnormalities in backgrounds and metabolism (36, 37). Based on the aetiologies, we reviewed the potential risk factors of TSS, which are important to arrive at a timely diagnosis.

Developmental spinal stenosis (DSS) is defined as the reduction of the area of the spinal canal crossing at the pedicle level in multiple or all segments (1). Compared with other patients, the incidence of TSS is higher among patients with DSS (16, 38). Torg-Pavlov rate (TPR) is an index for DSS diagnosis and is the only TSS predictor with statistical significance (39, 40), with a predictive value of less than 0.75–0.78 (16, 29). Although poor reliability of TPR as a cervical anatomical measurement has been reported (41), low TPR in one region is still a predictor of co-existing stenosis in valid cases (42, 43). Thus, TPR assessment should be routinely performed for patient stratification.

Table 1 Prevalence of TSS.

Study design	Sample source	Sample composition			Conclusion	Reference
		n	Sex	Age, years		
TSS prevalence in cadavers						
Cadaveric study	Cadaver specimens	440	N/A	N/A	LSS in 16.8%; CSS in 21.5%; CLTSS in 5.4%; CSS in LSS 32.4%; LSS in CSS 25.3%	Lee <i>et al.</i> (21)
Cadaveric study	Cadaver specimens	1072	M:882; F: 190	15 – 114*	CLTSS in 2% and CTTSS in 1%; A cadaver with a higher number of LSS segments is more likely to have CSS at the same time, and vice versa.	Bajwa <i>et al.</i> (22), Bajwa <i>et al.</i> (23)
CLTSS prevalence						
Retrospective study	Patients receiving surgical decompression for cervical, thoracic, or lumbar stenosis	1603	N/A	N/A	TSS in 2.06%	Bhandutia <i>et al.</i> (11)
Prospective cross-sectional study	Patients with symptomatic LSS	78	M:48; F:30	66 (53–82)	Asymptomatic CSM in 84.6%; Symptomatic CSM in 16.7%; 33.3% CSM patients had symptomatic LSS	Adamova <i>et al.</i> (25)
Retrospective study	Patients who had undergone cervical laminoplasty for CSM	214	M:153; F:61	62.8 (29–85)	LSS in 32% (symptomatic 13%, asymptomatic 19%)	Tsutsumimoto <i>et al.</i> (26)
Retrospective study	Patients who had undergone cervical surgery for CSM	297	M:201; F: 96	65.6 (27–93)	CLTSS in 57.9% (15% underwent a lumbar operation)	Yamada <i>et al.</i> (27)
Retrospective study	Patients who had undergone lumbar surgery for symptomatic LSS	565	M:279; F:286	70.7 (32–92)	CLTSS in 35.8% (5% underwent a cervical operation)	Yamada <i>et al.</i> (28)
Retrospective study	Patients with symptomatic LSS	237	M:117; F: 120	68.8 (45–87)	CSM in 8.86%; Men have a significantly higher incidence of CSM.	Iizuka <i>et al.</i> (29)
Retrospective study	Elderly patients with symptomatic LSS	101	M:39; F: 62	71 (65–86)	CSS in 77 (76.2%); ThSS in 30 (29.7%); CTTSS in 26 (25.7%); There was a correlation between the symptom duration of LSS and the prevalence of both ThSS and CSS.	Lee <i>et al.</i> (30)
Retrospective study	Patients received surgery for symptomatic spinal stenosis	1023	N/A	N/A	TSS in 0.88%	Molinari <i>et al.</i> (32)
Retrospective study	Patients received surgery for symptomatic spinal stenosis	230	N/A	N/A	CLTSS in 3.4%	Aydogan <i>et al.</i> (70)
Retrospective study	Patients received surgery for symptomatic spinal stenosis	158	N/A	N/A	CLTSS in 7.6%	Hsieh <i>et al.</i> (71)
CTLTSS and TSS with ThSS prevalence						
Retrospective study	Patients who had undergone thoracic surgery for ThSS	50	M:32; F:18	68.4 (40–86)	Concurrent LSS or CSS in 70%; CTLTSS in 10%	Uehara <i>et al.</i> (14)
Retrospective study	Elderly patients with LSS	460	M:101; F:359	83.3 (80–98)	CSS in 110 (23.9%); ThSS in 112 (24.3%); CLTSS in 26 (11.7%); CTTSS in 56 (12.2%); CTLTSS in 56 (12.2%)	Park <i>et al.</i> (33)
Retrospective study	Elderly patients with symptomatic LSS	101	M:39; F:62	71 (65–86)	CSS in 77 (76.2%); ThSS in 30 (29.7%); CTTSS in 26 (25.7%); There was a correlation between the symptom duration of LSS and the prevalence of both ThSS and CSS.	Kim <i>et al.</i> (34)
TSS prevalence in specific population						
Retrospective study	Japanese residents	931	M:627; F:304	68.2 (40–93)	Radiographic CLTSS in 11.0%; Radiographic CLTSS more prevalent in those with developmental canal stenosis; Symptomatic LSS in radiographic CLTSS was 18.6%; CSM in radiographic CLTSS was 9.8%; Symptomatic CLTSS in LSS was 6.1%	Nagata <i>et al.</i> (16)
MRI study	Asymptomatic patients who have undergone cervical and lumbar MRI	94	M:48; F:46	48.0 ± 13.4	CSS in 13.8%; LSS in 12.8%; CLTSS in 4%	Matsumoto <i>et al.</i> (17)
Retrospective study	Patients diagnosed with acoustic tumor by myelography	300	M:159; F:141	51 (18–76)	LSS in 24%; CSS in 21%; CLTSS in 8%	Hitselberger <i>et al.</i> (18)
Retrospective study	Hospital admissions	460964	N/A	N/A	CLTSS in 0.12%	LaBan <i>et al.</i> (19)
MRI study	Patients underwent lumbar spine MRI	2113	N/A	N/A	CLTSS in 1.9%	Seo <i>et al.</i> (20)

*Age of death.

CSM, cervical spondylotic myelopathy; CSS, cervical spinal stenosis; CLTSS, cervico-lumbar tandem spinal stenosis; CTTSS, cervico-thoracic tandem spinal stenosis; CTLTSS, cervico-thoraco-lumbar tandem spinal stenosis; LSS, lumbar spinal stenosis; N/A, not available; TSS, tandem spinal stenosis; ThSS, thoracic spinal stenosis; TLTSS, thoraco-lumbar tandem spinal stenosis.

Patients with stenosis in one region are likely to develop TSS (29, 44). Several studies have shown that patients who already have CSS or LSS are likely to have stenosis in other regions (21, 30, 38, 45). The presence of CSS positively predicts LSS in 16.7% of cases, and the presence of LSS predicts CSS in 15.3% of cases (21). Additionally, the incidence of coexisting stenosis correlates with the severity and morphology of pre-existing stenosis (30, 43).

OPLL and OLF can cause extensive stenosis, leading to TSS (9). Cervical OPLL frequently extends to the upper thoracic spine and leads to CTTSS, and the incidence of CLTSS is significantly higher among patients with cervical OPLL than among non-OPLL patients (9, 27, 46, 47). OPLL and OLF often occur simultaneously. In the Japanese population, 64.6% of patients with cervical OPLL also have a coexisting OLF (36), over 50% of those with thoracic OPLL have a coexisting cervical OPLL, and 46% of individuals with thoracic OPLL also have thoracic OLF (46). Furthermore, Liang *et al.* showed that nearly 50% of Chinese patients with OPLL have thoracic OPLL (47). Patients with OPLL or OLF in the lumbar region have a high rate (60%) of coexisting stenosis in other regions, and the rate of concurrent stenosis could increase to 75% when patients have both OPLL and OLF in their lumbar region (47, 48). The extensive and skipping occurrence of OPLL and OLF and their close association with spinal stenosis might play a critical role and have predictive significance in the development of CTLTSS.

Diagnosis dilemmas of TSS

Clinical features and diagnostic difficulties

TSS symptoms are composites of cord compression with or without LSS (Table 2). TSS manifests as features of complexity, concealment, and severity. It usually presents as a mixture of upper and lower motor neuron deficit symptoms and signs. In TSS, upper motor neuron symptoms and long track signs can be blunted or even masked by lower motor neuron symptoms. Hyperreflexia caused by CSS or ThSS may be obscured by compression of the cauda equina, and lower-limb pain induced by conus compression can be covered by radiculopathy (14, 49). Until the aggravation of concomitant compressions, referable findings may gradually emerge, composing the symptom constellation of typical TSS.

In patients with TSS who mainly present with lower-limb symptoms, cord compression is concealed. When symptoms caused by different lesions occur at adjacent or the same region(s), clinicians might lose sight of more distant stenosis (19, 32). For example, ThSS is often ignored in patients with TLTSS because of its nonspecific symptoms and slow progression (50, 51, 52, 53). It should be noted that ‘asymptomatic’ patients may develop or have changes that merged with the predominant symptoms (30); however, careful physical examination, such as evaluation of pathological gaits and lower-extremity weakness, can provide solid evidence of myelopathy and avoid misdiagnosis of TSS (34, 54). Furthermore, a thorough

Table 2 The subtypes and the clinical manifestation of TSS.

Subtype	Definition	Clinical presentation	Characteristic
CTTSS	TSS involves CSS and ThSS	Neck and back pain; Neurological symptoms: muscle weakness on upper and lower extremities, radiculopathy and hypoesthesia on upper extremities, hypoesthesia on lower extremities, gait disturbance, tendon hyperreflexia or hyporeflexia on upper extremity, tendon hyperreflexia on lower extremity, Hoffmann’s sign and Babinski’s sign positive; girdle feeling and sensory disturbance level on trunk.	CTTSS is mainly caused by heterotopic ossification. Cervical and thoracic lesion is usually close to each other at the cervico-thoracic junction. The symptoms are caused by cord compression, the responsible segment needs to be determined by careful examination. ThSS is usually underdiagnosed due to its low incidence and slower progression.
CLTSS	TSS involves CSS and LSS	Neck and low back pain; Neurological symptoms: muscle weakness on upper and lower extremities, radiculopathy and hypoesthesia on upper and lower extremities, neurogenic claudication, gait disturbance, tendon hyperreflexia or hyporeflexia on upper extremity, tendon hyporeflexia on lower extremity, Hoffmann’s sign and Babinski’s sign positive; sensory disturbance level on trunk.	CLTSS is the most common subtype of TSS. The manifestations caused by upper motor neuron deficit such as tendon hyperreflexia can be masked by those caused by lower motor neuron deficit. Additionally, CSS can also cause lower extremity symptoms, which may confuse and mislead clinicians to the diagnosis of LSS.
TLTSS	TSS involves ThSS and LSS	Back and low back pain; Neurological symptoms: muscle weakness on upper and lower extremities, radiculopathy and hypoesthesia on lower extremities, neurogenic claudication, tendon hyporeflexia on lower extremity, Babinski’s sign positive; girdle feeling and sensory disturbance level on trunk.	OLF at the lower thoracic spine combined with LSS is a common cause of TLTSS. ThSS is usually underdiagnosed due to its low incidence and slower progression.
CTLTSS	Concomitant occurrence of CSS, ThSS and LSS	Neck, back and low back pain; Serious neurological symptoms: muscle weakness on upper and lower extremities, radiculopathy and hypoesthesia on upper and lower extremities, hypoesthesia on lower extremities, neurogenic claudication, gait disturbance, tendon hyperreflexia or hyporeflexia on upper extremity, tendon hyperreflexia on lower extremity, Hoffmann’s sign and Babinski’s sign positive; girdle feeling and sensory disturbance level on trunk.	The most uncommon and severe TSS subtype. It is caused by defused heterotopic ossification and degeneration changes. The clinical presentation is complicated, the neural deficit can affect adjacent effector region and aggravate the symptoms. The surgical strategy should be designed on individual basis.

CSS, cervical spinal stenosis; CLTSS, cervico-lumbar tandem spinal stenosis; CTTSS, cervico-thoracic tandem spinal stenosis; CTLTSS, cervico-thoraco-lumbar tandem spinal stenosis; LSS, lumbar spinal stenosis; OLF, ossification of ligamentum flavum; TSS, tandem spinal stenosis; ThSS, thoracic spinal stenosis; TLTSS, thoraco-lumbar tandem spinal stenosis.

neurological examination that reflects possible diseases along the extent of the spinal column is recommended to avoid underdiagnosed concomitant stenosis (1, 20, 36, 49). Clinicians are also expected to maintain a high index of suspicion of TSS in the management of patients with spinal stenosis (19, 55, 56).

Patients with TSS may present with more severe preoperative symptoms owing to multiregional compression. The symptoms of one compression can be aggravated by neurological deficits caused by coexisting lesions, and the neurological response to single regional decompression is also lower in patients with TSS (57). Some studies used ‘double crush syndrome’ to explain the severity of TSS, in which proximal lesions, although sometimes asymptomatic, may increase susceptibility to compression at distal lesions (58, 59).

Diagnosis criteria of radiological TSS

In addition to the clinical manifestations, radiological evidence is essential to diagnose TSS. The diagnostic criteria for radiological TSS are based on the criteria for isolated spinal stenosis (60, 61, 62). The diagnostic criteria for TSS are not uniform in the literature, and this has led to variations in the reported prevalence of TSS and heterogeneity of clinical trials. Moreover, surgeons diagnose TSS using varied radiological examinations according to the routine practice in different centres and eras, including digital radiography (DR) (4), discography (63), CT (64), myelography (2, 26),

and MRI (16), and this also leads to inconsistencies in the diagnostic criteria used in studies.

Previously, surgeons used DR to diagnose TSS, and most studies within this period used a diameter of <10–12 mm to define radiological TSS (15, 21, 65, 66). In myelography assessment, Tsutsumimoto *et al.* used dura sac narrowing >50% to diagnose LSS in radiological TSS (26). In CT, a midsagittal diameter of <12 mm was used to diagnose radiological TSS (64). With the emerging applications of MRI, a large variety of diagnostic criteria and grading systems for spinal stenosis have been proposed (Table 3). In recent studies, the spinal stenosis grading systems proposed by Kang and Lee are often combined or applied to diagnose radiological TSS, since they are proposed in similar patterns consistently (61, 62, 67, 68, 69). However, the diagnostic criteria for radiological TSS with ThSS are yet to be clarified, and a comprehensive grading system with a treatment algorithm is urgently required.

Treatment of TSS

Patients with TSS who are not well managed conservatively require surgical intervention. The operative rate of two or more regions is as low as 0.88–7.6% among patients with spinal stenosis (11, 32, 70, 71). Under the basic goal of TSS surgery, which is strategic decompression, maintenance of nerve function, and spinal stability and alignment reconstruction (72), the optimal surgical strategy for TSS

Table 3 Useful radiographic diagnosis and grading criteria of partial spinal stenosis in TSS research.

Classification	Radiographic diagnosis criteria	Radiographic grading criteria	Reference
CSS	Based on CT or T2-weighted image of MRI: Dorsal-ventral diameter of the spinal canal : < 12 mm or 10 mm	Based on T2-weighted image of MRI: Grade 0: the absence of central canal stenosis Grade 1: nearly complete obliteration of subarachnoid space, including obliteration of the arbitrary subarachnoid space exceeding 50%, without signs of cord deformity. Grade 2: central canal stenosis with cord deformity but without spinal cord signal change. Grade 3: the presence of spinal cord signal change near the compressed level on T2-weighted images.	4, 61
ThSS	There are no quantitative diagnostic criteria, and the diagnosis is often made through clinical experience.	No radiographic grading system	N/A
LSS	Based on CT or T2-weighted image of MRI: 1. Antero-posterior diameter of spinal canal: relative LSS: 10–12 mm absolute LSS: <10 mm 2. Cross-sectional area of dural tube or sac: relative LSS: < 100 mm ² absolute LSS: <75 mm ² or 70 mm ² 3. Ligamentous interfacet distance: < 10 mm (L2 - L3) < 10 mm (L3 - L4) < 12 mm (L4 - L5) < 13 mm (L5 - S1) 4. Transverse diameter of spinal canal: < 15 mm or 16 mm	Criteria one (based on T2-weighted image of MRI) : No or minor stenosis: there is clearly CSF visible inside the dural sac, but its distribution is inhomogeneous Moderate stenosis: the rootlets occupy the whole of the dural sac, but they can still be individualized. Some CSF is still present giving a grainy appearance to the sac. Severe stenosis: no rootlets can be recognized, the dural sac demonstrating a homogeneous grey signal with no CSF signal visible. There is epidural fat present posteriorly. Extreme stenosis: in addition to no rootlets being recognizable there is no epidural fat posteriorly. Criteria two (Based on T2-weighted image of MRI) : Grade 0: no lumbar stenosis without obliteration of anterior CSF space; Grade 1: mild stenosis with separation of all cauda equina; Grade 2: moderate stenosis with some cauda equina aggregated; Grade 3: severe stenosis with none of the cauda equina separated	59, 61, 67

CSF, cerebrospinal fluid; CSS, cervical spinal stenosis; LSS, lumbar spinal stenosis; TSS, tandem spinal stenosis; ThSS, thoracic spinal stenosis.

is still debatable. Controversies include region selection, surgical patterns, and order.

Does asymptomatic lesions require surgery?

Although some studies have demonstrated that coexisting asymptomatic stenosis does not interfere with postoperative improvement (26, 28, 73), clinicians have observed that latent LSS does not interfere with the recovery of CSM, while asymptomatic CSS can negatively affect patients' improvement after lumbar surgery (1, 30, 74, 75, 76). After selective surgery, some patients with TSS have incomplete recovery or develop new symptoms that might be masked preoperatively or aggravated postoperatively (12). Another consideration is that asymptomatic lesions may cause intra-operative position-related complications. In the prone position, the area of the stenotic spinal canal decreases by up to 67%, which could aggravate neural compression and decrease blood supply (77). It has been reported that some patients with radiological TSS develop myelopathic symptoms and cauda equina symptoms after long-term surgery in other regions or even after sleeping (11, 78, 79, 80, 81). Thus, the surgical strategy for TSS requires a comprehensive vision for development, as the symptoms cannot completely reflect the neurological vulnerability and deficit (34, 82). Surgeons should pay close attention to latent CSS and ThSS in patients with TSS and consider secondary decompression for those with incomplete resolution or new symptoms after the initial lumbar surgery.

Surgical pattern for CLTSS

Previous studies have demonstrated similar efficacy and risks of staged and simultaneous surgery in patients with CLTSS (27, 83). For nuances, simultaneous surgery could lead to significant short-term improvement, whereas slower recovery or deterioration has been observed during long-term follow-up (57, 69). Staged surgery could lead to better early outcomes than simultaneous surgery; however, the results of simultaneous surgeries in later follow-up were superior (70). For surgical complications, Eskander *et al.* found that the complication rate was higher among cases in patients with CLTSS who were above 68 years of age, estimated blood loss >400 mL, or combined operation time >150 min (83). Interestingly, Molinari *et al.* performed simultaneous surgery in a group of patients with TSS whose average age was 67 years, mean operative time was 159 min, and mean intraoperative blood loss was 558 mL; they reported no major complications, and all patients had a high degree of satisfaction (32), indicating a rather non-absolute boundary that influenced the complication rate. Thus, surgeons should consider intrinsic advantages when planning surgeries. Simultaneous surgery can improve operative length, blood loss, and position-related

complication rate in patients with severe stenosis (12). On the other hand, staged surgery may be preferred for its ability to lower one-time invasiveness, target more symptomatic regions, and avoid unnecessary surgery by allowing time to recover (72).

These results indicate a comparable outcome between the two strategies when properly selected. In the CLTSS treatment algorithm, patients with CSS and LSS with similar severity, high motivation, high percentage of developing neurological complications in prone positioning, and good general condition are eligible for simultaneous surgery, while patients with poor status, or those who predominantly manifest with CSS and minor presentation of LSS, with corresponding radiological evidence, or vice versa, are suitable for staged surgery (72).

Surgical order of CLTSS

Most patients with CLTSS are elderly with poor general condition and unequal CSS and LSS (31, 34), and these patients are inclined to undergo staged surgery. Thus, the discussion of the surgical order has come alive.

In clinical practice, the priority resolution of cervical compression with or without myelopathy is supported (13). Cervical procedures do not only resolve typical CSS symptoms but can also improve lumbar symptoms, including radiculopathy and low back pain (84, 85, 86, 87), which decreases the necessity of subsequent lumbar surgery (26, 84). Compared with starting from the lumbar region, initial cervical surgery results in a higher complete resolution rate, lower rates of developing new symptoms and secondary surgery, and longer surgical intervals (11, 67, 72). This is because cervical decompression may induce functional recovery of the spinothalamic tract and corticospinal tract, resulting in neurological improvement (85, 88), while initial lumbar surgery may alter the pressure at other lesions, which could worsen the pressure on neural tissues and causes new symptoms (89).

Despite the improvement in lumbar symptoms after the cervical procedure, the effect of cervical surgery cannot be overclaimed. Some lumbar symptoms, such as intermittent claudication, cannot be relieved by cervical decompression (2), and most lumbar symptoms were temporarily relieved; only 14% of patients with CLTSS experience improvements in long-term follow-ups, while the rest would need to undergo secondary surgery (87). Sometimes, lumbar surgery alone provides better outcomes than cervical surgery or both procedures in patients with CLTSS who predominantly present with lumbar symptoms (15). Therefore, instead of starting from the cervical spine, several surgeons and our group have proposed individualised strategies. In the algorithm, after evaluating clinical manifestation and radiological and electrophysiological examinations, patients receive cervical surgery first if they predominantly present with

upper motor neuron signs or upper extremity symptoms, and lumbar surgery is performed initially if the patients present with lower extremity symptoms without upper motor neuron signs (1, 2, 50, 71) (Fig. 2). This strategy has resulted in excellent outcomes in several studies (15, 70, 71), and can be used to stratify patients with TSS to avoid unnecessary interventions (12).

Surgical strategy for TSS with ThSS

Due to extensive spinal cord violation in TSS with ThSS, the treatment does not share the same strategy and prognosis as CLTSS. In CT/TLTSS treatment, simultaneous and staged surgery can lead to comparable clinical outcomes (7, 90), and the strategy is largely determined by patient factors, such as general condition, location and distance of the lesion, predominant compression, and complication rate. When ThSS occurs adjacent to concurrent CSS or LSS, simultaneous surgery is more feasible by performing a single incision under one-time anaesthesia and hospitalisation. In the treatment of CTTSS, simultaneous surgery for adjacent lesions (lesion departing less than three levels) results in good outcomes and high cost-effectiveness (90, 91) (Fig. 2). However, safety concerns associated with simultaneous surgeries, such as deterioration, complications, and secondary surgery rate, impede its application, in addition to the adjacent type (7,

35, 90). Staged surgery is more reasonable for skipped CT/TLTSS. The principle of staged surgery is to resolve the predominant symptom first, which is evaluated via imaging, electrophysiological examinations, neurological status, and medical comorbidities, and subsequently decompress the remaining stenosis (10, 55). The prognosis of CT/TLTSS is poorer than that of CLTSS because of its severe nature, including its prolonged course, extensive cord compression, severe invasion, and dural adhesion (8, 92, 93, 94). Consequently, any intervention may induce unfavourable outcomes, and neither simultaneous nor staged surgery can decrease the complication rate (55).

Recently, treatment with CTLTSS has been reported (95). Some surgeons have applied simultaneous surgery to all lesions and reported improvement without complications (95). However, this strategy is not suitable for all patients because of its invasiveness, long surgical time, high skill dependency, and multiple technical variables, which lead to difficulty in tracing back. Staged surgery is less challenging and more acceptable to both surgeons and patients. By decompressing several adjacent lesions together in separate stages or resolving one region per stage, patients significantly improve the attenuated risk (93, 96). In the algorithm of our group, if the thoracic stenosis is adjacent to the cervical or lumbar lesion, initial cervicothoracic or thoracolumbar combined surgery

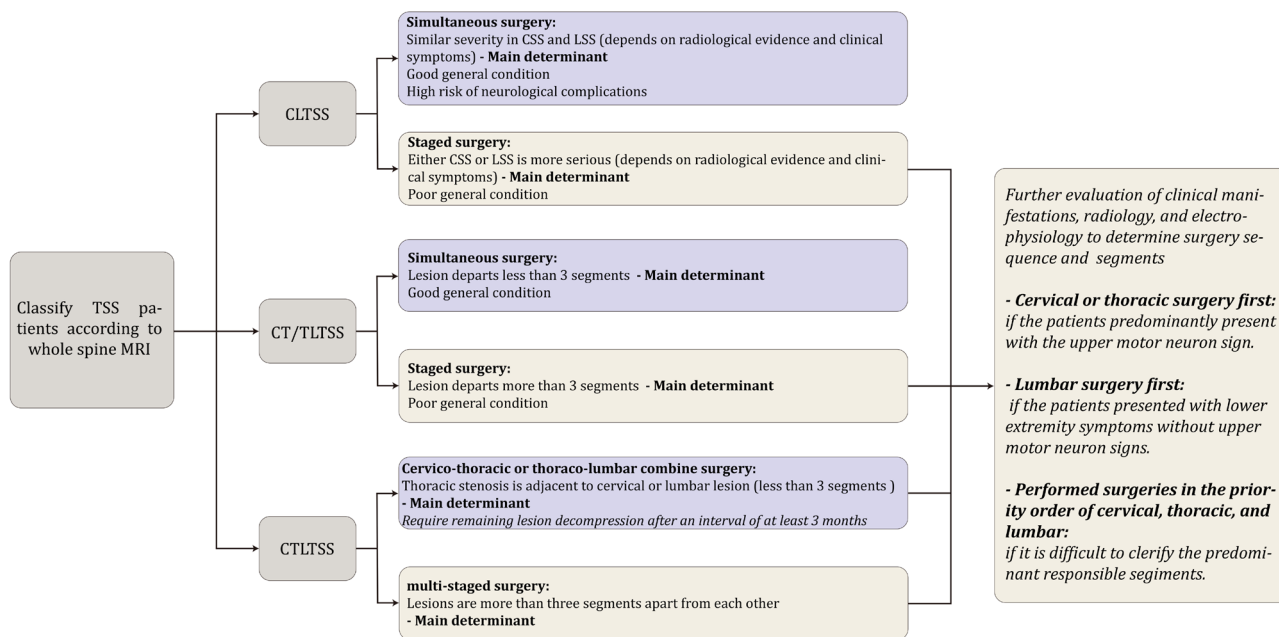


Figure 2

The treatment algorithm of the subtypes of TSS. For CLTSS, the main determinants of surgical pattern are predominant symptoms, complication rate, and general condition; while lesion distance alters the surgical pattern greatly in the other TSS subtypes with ThSS. The surgical sequence is determined by the predominant symptoms and subjective examination results. CSS, cervical spinal stenosis; CLTSS, cervico-lumbar tandem spinal stenosis; CTTSS, cervico-thoracic tandem spinal stenosis; CTLTSS, cervico-thoracolumbar tandem spinal stenosis; LSS, lumbar spinal stenosis; TSS, tandem spinal stenosis; ThSS, thoracic spinal stenosis; TLTSS, thoraco-lumbar tandem spinal stenosis.

should be performed to resolve the most severe lesion, and decompression of the other site should be performed after an interval of at least 3 months; if the lesion sites are three levels apart from each other, multi-staged surgery ought to be initialised from the most myelopathic site, if it exists, or from the cervical spine (Fig. 2).

In addition to the predominant symptoms, compression location, and cord priority, non-spinal factors also determine the surgical strategy of TSS. With the exacerbation of the aging society, the elderly account for a large proportion of patients who undergo spinal surgery (97). The high surgical risk due to poor general condition, anaesthesia risk, high revision surgery rate, and complicated underlying diseases make it challenging for elderly patients to undergo surgeries. Although some studies reported similar complication rates in elderly and young patients who underwent lumbar surgeries (98), complication rates, morbidity, and mortality were significantly increased among patients >80 years of age (97, 99). Some common spinal surgical complications, such as cerebrospinal fluid leakage and delayed wound healing, can cause severe consequences in elderly patients owing to their frailty (100). Thus, overall consideration is necessary for elderly patients with TSS. Underlying diseases can also alter treatment strategies. For instance, diabetes mellitus (DM) increases the risk of complications of spinal surgery. Patients with DM are also more likely to develop postoperative infection and deep venous thrombosis, which may lead to prolonged hospitalisation or even death (101). Therefore, the treatment strategy of TSS is also largely determined by non-spinal aspects, and staged surgery or selective surgery might be alternatives for TSS patients with such conditions.

Conclusions

TSS refers to concomitant stenosis in at least two regions of the spine that results in associated symptoms and signs. Clinicians should be aware of the incidence of TSS among patients with relevant aetiologies and risk factors and make a complete and timely diagnosis via comprehensive evaluations. However, the current diagnostic criteria for TSS must be unified and standardised. For treatment, both simultaneous and staged surgeries are effective strategies, and surgeons should design the optimal treatment by analysing the general condition, subtypes, predominant symptoms, cord decompression priority, lesion factors, and prognosis. The concept of TSS has evolved from stenosis that occurs only in the cervical and lumbar spine to stenotic changes that affect any level of the entire spine. In this process, the clinical perception of TSS is largely altered. Stenotic regions are no longer pathologies that accidentally occur concurrently; instead, they are related to certain mechanisms to some extent. Similarly,

the treatment of TSS requires a more delicate design with the overall situation. However, among the documented studies, optimal strategies with solid evidence have not been proposed, and more high-level clinical trials are required to determine the suitable surgical pattern for TSS.

ICMJE Conflict of Interest Statement

The authors declare that there is no conflict of interest that could be perceived as prejudicing the impartiality of the research reported.

Funding statement

This work was supported by Jilin Provincial Natural Science Foundation (no. 20200201531JC) and National Natural Science Foundation of China (NO. 82072508).

Author contribution statement

All authors listed have made a substantial, direct, and intellectual contribution to the work, and approved it for publication. Bai Q and Wang Y drafted the manuscript; Zhai J and Wu J collected the reference and data; Zhang Y extracted and visualized the figures; Zhao Y designed the study.

References

1. Baker JF. Evaluation and treatment of tandem spinal stenosis. *Journal of the American Academy of Orthopaedic Surgeons* 2020 **28** 229–239. (<https://doi.org/10.5435/JAAOS-D-18-00726>)
2. Epstein NE, Epstein JA, Carras R, Murthy VS & Hyman RA. Coexisting cervical and lumbar spinal stenosis: diagnosis and management. *Neurosurgery* 1984 **15** 489–496. (<https://doi.org/10.1227/00006123-198410000-00003>)
3. OSCI investigators, Chikuda H, Koyama Y, Matsubayashi Y, Ogata T, Ohtsu H, Sugita S, Sumitani M, Kadono Y, Miura T, et al. Effect of early vs delayed surgical treatment on motor recovery in incomplete cervical spinal cord injury with preexisting cervical stenosis: a randomized clinical trial. *JAMA Network Open* 2021 **4** e2133604. (<https://doi.org/10.1001/jamanetworkopen.2021.33604>)
4. Dagi TF, Tarkington MA & Leech JJ. Tandem lumbar and cervical spinal stenosis. Natural history, prognostic indices, and results after surgical decompression. *Journal of Neurosurgery* 1987 **66** 842–849. (<https://doi.org/10.3171/jns.1987.66.6.0842>)
5. Brain R & Wilkinson M. The association of cervical spondylosis and disseminated sclerosis. *Brain* 1957 **80** 456–478. (<https://doi.org/10.1093/brain/80.4.456>)
6. Teng P & Papatheodorou C. Combined cervical and lumbar spondylosis. *Archives of Neurology* 1964 **10** 298–307. (<https://doi.org/10.1001/archneur.1964.00460150068007>)
7. Chen Y, Chen DY, Wang XW, Lu XH, Yang HS & Miao JH. Single-stage combined decompression for patients with tandem ossification in the cervical and thoracic spine. *Archives of Orthopaedic and Trauma Surgery* 2012 **132** 1219–1226. (<https://doi.org/10.1007/s00402-012-1540-5>)
8. Matsumoto Y, Harimaya K, Doi T, Kawaguchi K, Okada S, Inoguchi A, Fujiwara M & Iwamoto Y. Clinical characteristics and surgical outcome of the symptomatic ossification of ligamentum flavum at the thoracic level with combined lumbar spinal stenosis. *Archives of Orthopaedic and Trauma Surgery* 2012 **132** 465–470. (<https://doi.org/10.1007/s00402-011-1438-7>)
9. Park JY, Chin DK, Kim KS & Cho YE. Thoracic ligament ossification in patients with cervical ossification of the posterior longitudinal ligaments: tandem ossification in

the cervical and thoracic spine. *Spine* 2008 **33** E407–E410. (<https://doi.org/10.1097/BRS.0b013e318175c276>)

10. Wang C, Wang QZ, Gao JH, Zhang L, Zhang L & Chen BH. Clinical comparison of selective versus nonselective decompression for symptomatic tandem stenosis of the cervical and thoracic spine: a retrospective cohort study. *Orthopaedic Surgery* 2021 **13** 537–545. (<https://doi.org/10.1111/os.12889>)

11. Bhandutia A, Brown L, Nash A, Bussey I, Shasti M, Koh E, Banagan K, Ludwig S & Gelb D. Delayed diagnosis of tandem spinal stenosis: a retrospective institutional review. *International Journal of Spine Surgery* 2019 **13** 283–288. (<https://doi.org/10.14444/6038>)

12. Overley SC, Kim JS, Gogel BA, Merrill RK & Hecht AC. Tandem spinal stenosis: a systematic review. *JBJS Reviews* 2017 **5** e2. (<https://doi.org/10.2106/JBJS.RVW.17.00007>)

13. Dowlati E, Mualem W, Black J, Nuñez J, Girish A, Fayed I, McGrail KM & Voyadzis JM. Should asymptomatic cervical stenosis be treated in the setting of progressive thoracic myelopathy? A systematic review of the literature. *European Spine Journal* 2022 **31** 275–287. (<https://doi.org/10.1007/s00586-021-07046-1>)

14. Uehara M, Tsutsumimoto T, Yui M, Ohta H, Ohba H & Misawa H. Single-stage surgery for compressive thoracic myelopathy associated with compressive cervical myelopathy and/or lumbar spinal canal stenosis. *European Spine Journal* 2016 **25** 1904–1911. (<https://doi.org/10.1007/s00586-015-4133-5>)

15. Pennington Z, Alentado VJ, Lubelski D, Alvin MD, Levin JM, Benzel EC & Mroz TE. Quality of life changes after lumbar decompression in patients with tandem spinal stenosis. *Clinical Neurology and Neurosurgery* 2019 **184** 105455. (<https://doi.org/10.1016/j.clineuro.2019.105455>)

16. Nagata K, Yoshimura N, Hashizume H, Ishimoto Y, Muraki S, Yamada H, Oka H, Kawaguchi H, Akune T, Tanaka S, et al. The prevalence of tandem spinal stenosis and its characteristics in a population-based MRI study: the Wakayama Spine Study. *European Spine Journal* 2017 **26** 2529–2535. (<https://doi.org/10.1007/s00586-017-5072-0>)

17. Matsumoto M, Okada E, Toyama Y, Fujiwara H, Momoshima S & Takahata T. Tandem age-related lumbar and cervical intervertebral disc changes in asymptomatic subjects. *European Spine Journal* 2013 **22** 708–713. (<https://doi.org/10.1007/s00586-012-2500-z>)

18. Hitselberger WE & Witten RM. Abnormal myelograms in asymptomatic patients. *Journal of Neurosurgery* 1968 **28** 204–206. (<https://doi.org/10.3171/jns.1968.28.3.0204>)

19. LaBan MM, Green ML & Concurrent. Concurrent (tandem) cervical and lumbar spinal stenosis: a 10-yr review of 54 hospitalized patients. *American Journal of Physical Medicine and Rehabilitation* 2004 **83** 187–190. (<https://doi.org/10.1097/01.phm.0000113405.48879.45>)

20. Seo J, Park SY, Lee JW, Lee GY & Kang HS. The value of additional cervicothoracic spine sagittal T2-weighted images included in routine lumbar Spine MR imaging. *Journal of the Korean Society of Magnetic Resonance in Medicine* 2013 **17** 91. (<https://doi.org/10.13104/jksmrm.2013.17.2.91>)

21. Lee MJ, Garcia R, Cassinelli EH, Furey C & Riew KD. Tandem stenosis: a cadaveric study in osseous morphology. *Spine Journal* 2008 **8** 1003–1006. (<https://doi.org/10.1016/j.spinee.2007.12.005>)

22. Bajwa NS, Toy JO & Ahn NU. Is lumbar stenosis associated with thoracic stenosis? A study of 1,072 human cadaveric specimens. *Spine Journal* 2012 **12** 1142–1146. (<https://doi.org/10.1016/j.spinee.2012.10.029>)

23. Bajwa NS, Toy JO & Ahn NU. Is congenital bony stenosis of the cervical spine associated with congenital bony stenosis of the thoracic spine? An anatomic study of 1072 human cadaveric specimens. *Journal of Spinal Disorders and Techniques* 2013 **26** E1–E5. (<https://doi.org/10.1097/BSD.0b013e3182694320>)

24. Jane JA, Sr, Jane Jr. JA, Helm GA, Kallmes DF, Shaffrey CI, Chaddock JB & DiPiero CG. Acquired lumbar spinal stenosis. *Clinical Neurosurgery* 1996 **43** 275–299.

25. Adamova B, Bednarik J, Andrasinova T, Kovalova I, Kopicak R, Jabornik M, Kerkovsky M, Jakubcova B & Jarkovsky J. Does lumbar spinal stenosis increase the risk of spondylotic cervical spinal cord compression? *European Spine Journal* 2015 **24** 2946–2953. (<https://doi.org/10.1007/s00586-015-4049-0>)

26. Tsutsumimoto T, Shimogata M, Yui M, Ohta H & Misawa H. The natural history of asymptomatic lumbar canal stenosis in patients undergoing surgery for cervical myelopathy. *Journal of Bone and Joint Surgery: British Volume* 2012 **94** 378–384. (<https://doi.org/10.1302/0301-620X.94B3.27867>)

27. Yamada T, Yoshii T, Yamamoto N, Hirai T, Inose H, Kato T, et al. Clinical outcomes of cervical spinal surgery for cervical myelopathic patients with coexisting lumbar spinal canal stenosis (tandem spinal stenosis): a retrospective analysis of 297 cases. *Spine* 2018 **43** E234–E241. (<https://doi.org/10.1097/BRS.0000000000002289>)

28. Yamada T, Yoshii T, Yamamoto N, Hirai T, Inose H & Okawa A. Surgical outcomes for lumbar spinal canal stenosis with coexisting cervical stenosis (tandem spinal stenosis): a retrospective analysis of 565 cases. *Journal of Orthopaedic Surgery and Research* 2018 **13** 60. (<https://doi.org/10.1186/s13018-018-0765-6>)

29. Iizuka H, Takahashi K, Tanaka S, Kawamura K, Okano Y & Oda H. Predictive factors of cervical spondylotic myelopathy in patients with lumbar spinal stenosis. *Archives of Orthopaedic and Trauma Surgery* 2012 **132** 607–611. (<https://doi.org/10.1007/s00402-012-1465-z>)

30. Lee SH, Kim KT, Suk KS, Lee JH, Shin JH, So DH & Kwack YH. Asymptomatic cervical cord compression in lumbar spinal stenosis patients: a whole spine magnetic resonance imaging study. *Spine* 2010 **35** 2057–2063. (<https://doi.org/10.1097/BRS.0b013e3181f4588a>)

31. Park SH, Ahn JM, Lee JW, Lee GY & Kang HS. Value of additional cervicothoracic sagittal T2-weighted images in elderly patients with symptoms suggestive of lumbar spinal stenosis. *Journal of the Korean Society of Radiology* 2015 **73** 18–25. (<https://doi.org/10.3348/jksr.2015.73.1.18>)

32. Molinari RW. Tandem spinal stenosis (TSS): literature review and report of patients treated with simultaneous decompression. *Current Orthopaedic Practice* 2012 **23** 356–363. (<https://doi.org/10.4172/2165-7939.1000200>)

33. Park MS, Moon SH, Kim TH, Oh JK, Lyu HD, Lee JH & Riew KD. Asymptomatic stenosis in the cervical and thoracic spines of patients with symptomatic lumbar stenosis. *Global Spine Journal* 2015 **5** 366–371. (<https://doi.org/10.1055/s-0035-1549031>)

34. Kim BS, Kim J, Koh HS, Han SY, Lee DY & Kim KH. Asymptomatic cervical or thoracic lesions in elderly patients who have undergone decompressive lumbar surgery for stenosis. *Asian Spine Journal* 2010 **4** 65–70. (<https://doi.org/10.4184/asj.2010.4.2.65>)

35. Hu P, Yu M, Liu X, Liu Z, Jiang L & Chen Z. One-staged combined decompression for the patients with cervico-thoracic tandem spinal stenosis. *European Spine Journal* 2017 **26** 374–381. (<https://doi.org/10.1007/s00586-016-4497-1>)

36. Kawaguchi Y, Nakano M, Yasuda T, Seki S, Hori T, Suzuki K, Makino H & Kimura T. Characteristics of ossification of the spinal ligament; incidence of ossification of

the ligamentum flavum in patients with cervical ossification of the posterior longitudinal ligament – Analysis of the whole spine using multidetector CT. *Journal of Orthopaedic Science* 2016 **21** 439–445. (<https://doi.org/10.1016/j.jos.2016.04.009>)

37. Matsunaga S & Sakou T. Overview of epidemiology and genetics. In: *Ossification of the Posterior Longitudinal Ligament (OPLL)*. pp. 7–9. K Yonenobu, K Nakamura, Y Toyama (Eds) Springer, 2006. (https://doi.org/10.1007/978-4-431-32563-5_2)

38. Miyazaki M, Koderu R, Yoshiiwa T, Kawano M, Kaku N & Tsumura H. Prevalence and distribution of thoracic and lumbar compressive lesions in cervical spondylotic myelopathy. *Asian Spine Journal* 2015 **9** 218–224. (<https://doi.org/10.4184/asj.2015.9.2.218>)

39. Torg JS, Pavlov H, Genuario SE, Sennett B, Wisneski RJ, Robie BH & Jahre C. Neurapraxia of the cervical spinal cord with transient quadriplegia. *Journal of Bone and Joint Surgery: American Volume* 1986 **68** 1354–1370. (<https://doi.org/10.2106/00004623-198668090-00008>)

40. Edwards WC & LaRocca SH. The developmental segmental sagittal diameter in combined cervical and lumbar spondylosis. *Spine* 1985 **10** 42–49. (<https://doi.org/10.1097/00007632-198501000-00007>)

41. Blackley HR, Plank LD & Robertson PA. Determining the sagittal dimensions of the canal of the cervical spine. The reliability of ratios of anatomical measurements. *Journal of Bone and Joint Surgery: British Volume* 1999 **81** 110–112. (<https://doi.org/10.1302/0301-620x.81b1.9001>)

42. Singh A, Tetreault L, Fehlings MG, Fischer DJ & Skelly AC. Risk factors for development of cervical spondylotic myelopathy: results of a systematic review. *Evidence-Based Spine-Care Journal* 2012 **3** 35–42. (<https://doi.org/10.1055/s-0032-1327808>)

43. van Eck CF, Spina Iii NT & Lee JY. A novel MRI classification system for congenital functional lumbar spinal stenosis predicts the risk for tandem cervical spinal stenosis. *European Spine Journal* 2017 **26** 368–373. (<https://doi.org/10.1007/s00586-016-4657-3>)

44. Kawaguchi Y, Oya T, Abe Y, Kanamori M, Ishihara H, Yasuda T, Nogami S, Hori T & Kimura T. Spinal stenosis due to ossified lumbar lesions. *Journal of Neurosurgery: Spine* 2005 **3** 262–270. (<https://doi.org/10.3171/spi.2005.3.4.0262>)

45. Okada E, Matsumoto M, Fujiwara H & Toyama Y. Disc degeneration of cervical spine on MRI in patients with lumbar disc herniation: comparison study with asymptomatic volunteers. *European Spine Journal* 2011 **20** 585–591. (<https://doi.org/10.1007/s00586-010-1644-y>)

46. Fujimori T, Watabe T, Iwamoto Y, Hamada S, Iwasaki M & Oda T. Prevalence, concomitance, and distribution of ossification of the spinal ligaments: results of whole spine CT scans in 1500 Japanese patients. *Spine* 2016 **41** 1668–1676. (<https://doi.org/10.1097/BRS.0000000000001643>)

47. Liang H, Liu G, Lu S, Chen S, Jiang D, Shi H & Fei Q. Epidemiology of ossification of the spinal ligaments and associated factors in the Chinese population: a cross-sectional study of 2000 consecutive individuals. *BMC Musculoskeletal Disorders* 2019 **20** 253. (<https://doi.org/10.1186/s12891-019-2569-1>)

48. Inamasu J, Guiot BH & Sachs DC. Ossification of the posterior longitudinal ligament: an update on its biology, epidemiology, and natural history. *Neurosurgery* 2006 **58** 1027–1039; discussion 1039. (<https://doi.org/10.1227/01.NEU.0000215867.87770.73>)

49. Fushimi K, Miyamoto K, Hioki A, Hosoe H, Takeuchi A & Shimizu K. Neurological deterioration due to missed thoracic spinal stenosis after decompressive lumbar surgery: a report of six cases of tandem thoracic and lumbar spinal stenosis. *Bone and Joint Journal* 2013 **95–B** 1388–1391. (<https://doi.org/10.1302/0301-620X.95B10.31222>)

50. Jannelli G, Baticam NS, Tizi K, Truffert A, Lascano AM & Tessitore E. Symptomatic tandem spinal stenosis: a clinical, diagnostic, and surgical challenge. *Neurosurgical Review* 2020 **43** 1289–1295. (<https://doi.org/10.1007/s10143-019-01154-9>)

51. Epstein NE. Patients with "lumbar stenosis" and unrecognized distal thoracic cord compression. *Spinal Surgery* 2007 **21** 101–105. (<https://doi.org/10.2531/spinalurg.21.101>)

52. Sasai K, Adachi T, Togano K, Wakabayashi E, Ohnari H & Iida H. Two-level disc herniation in the cervical and thoracic spine presenting with spastic paresis in the lower extremities without clinical symptoms or signs in the upper extremities. *Spine Journal* 2006 **6** 464–467. (<https://doi.org/10.1016/j.spinee.2005.10.018>)

53. Chen G, Fan T, Yang X, Sun C, Fan D & Chen Z. The prevalence and clinical characteristics of thoracic spinal stenosis: a systematic review. *European Spine Journal* 2020 **29** 2164–2172. (<https://doi.org/10.1007/s00586-020-06520-6>)

54. Luo CA, Lu ML, Kaliya-Perumal AK, Chen LH, Chen WJ & Niu CC. Degenerative cervical myelopathy presenting as subjective lower limb weakness could be a trap towards misdiagnosis. *Scientific Reports* 2020 **10** 21188. (<https://doi.org/10.1038/s41598-020-78139-y>)

55. Li WJ, Guo SG, Sun ZJ & Zhao Y. Multilevel thoracic ossification of ligamentum flavum coexisted with/without lumbar spinal stenosis: staged surgical strategy and clinical outcomes. *BMC Musculoskeletal Disorders* 2015 **16** 206. (<https://doi.org/10.1186/s12891-015-0672-5>)

56. Gupta A, Dave B, Nanda A & Modi H. Concomitant noncontiguous level (thoracic & lumbar) spinal stenosis. *International Orthopaedics* 2009 **33** 483–488. (<https://doi.org/10.1007/s00264-008-0545-8>)

57. Kikuike K, Miyamoto K, Hosoe H & Shimizu K. One-staged combined cervical and lumbar decompression for patients with tandem spinal stenosis on cervical and lumbar spine: analyses of clinical outcomes with minimum 3 years follow-up. *Journal of Spinal Disorders and Techniques* 2009 **22** 593–601. (<https://doi.org/10.1097/BSD.0b013e3181929cbd>)

58. Upton AR & McComas AJ. The double crush in nerve entrapment syndromes. *Lancet* 1973 **2** 359–362. ([https://doi.org/10.1016/s0140-6736\(73\)93196-6](https://doi.org/10.1016/s0140-6736(73)93196-6))

59. Kane PM, Daniels AH & Akelman E. Double crush syndrome. *Journal of the American Academy of Orthopaedic Surgeons* 2015 **23** 558–562. (<https://doi.org/10.5435/JAAOS-D-14-00176>)

60. Steurer J, Roner S, Gnannt R, Hodler J & LumbSten Research Collaboration. Quantitative radiologic criteria for the diagnosis of lumbar spinal stenosis: a systematic literature review. *BMC Musculoskeletal Disorders* 2011 **12** 175. (<https://doi.org/10.1186/1471-2474-12-175>)

61. Lee GY, Lee JW, Choi HS, Oh KJ & Kang HS. A new grading system of lumbar central canal stenosis on MRI: an easy and reliable method. *Skeletal Radiology* 2011 **40** 1033–1039. (<https://doi.org/10.1007/s00256-011-1102-x>)

62. Kang Y, Lee JW, Koh YH, Hur S, Kim SJ, Chai JW & Kang HS. New MRI grading system for the cervical canal stenosis. *AJR. American Journal of Roentgenology* 2011 **197** W134–W140. (<https://doi.org/10.2214/AJR.10.5560>)

63. Holt Ejr. EP. The question of lumbar discography. *Journal of Bone and Joint Surgery: American Volume* 1968 **50** 720–726. (<https://doi.org/10.2106/00004623-196850040-00007>)

64. Laroche M, Moulinier L, Arlet J, Arrue P, Rousseau H, Cantagrel A & Mazieres B. Lumbar and cervical stenosis. Frequency of the association, role of the ankylosing hyperostosis. *Clinical Rheumatology* 1992 **11** 533–535. (<https://doi.org/10.1007/BF02283114>)

65. Verbiest H. Results of surgical treatment of idiopathic developmental stenosis of the lumbar vertebral canal. A review of twenty-seven years' experience. *Journal of Bone and Joint Surgery: British Volume* 1977 **59** 181–188. (<https://doi.org/10.1302/0301-620X.59B2.141452>)

- 66. Bolender NF, Schönström NS, Spengler DM.** Role of computed tomography and myelography in the diagnosis of central spinal stenosis. *The Journal of Bone and Joint Surgery: American Volume* 1985 **67** 240–246.
- 67. Luo CA, Kaliya-Perumal AK, Lu ML, Chen LH, Chen WJ & Niu CC.** Staged surgery for tandem cervical and lumbar spinal stenosis: which should be treated first? *European Spine Journal* 2019 **28** 61–68. (<https://doi.org/10.1007/s00586-018-5795-6>)
- 68. Schizas C, Theumann N, Burn A, Tansey R, Wardlaw D, Smith FW & Kulik G.** Qualitative grading of severity of lumbar spinal stenosis based on the morphology of the dural sac on magnetic resonance images. *Spine* 2010 **35** 1919–1924. (<https://doi.org/10.1097/BRS.0b013e3181d359bd>)
- 69. Krishnan A, Dave BR, Kambur AK & Ram H.** Coexisting lumbar and cervical stenosis (tandem spinal stenosis): an infrequent presentation. Retrospective analysis of single-stage surgery (53 cases). *European Spine Journal* 2014 **23** 64–73. (<https://doi.org/10.1007/s00586-013-2868-4>)
- 70. Aydogan M, Ozturk C, Mirzanli C, Karatoprak O, Tezer M & Hamzaoglu A.** Treatment approach in tandem (concurrent) cervical and lumbar spinal stenosis. *Acta Orthopaedica Belgica* 2007 **73** 234–237.
- 71. Hsieh CH, Huang TJ & Hsu RW.** Tandem spinal stenosis: clinical diagnosis and surgical treatment. *Changcheng yi xue za zhi* 1998 **21** 429–435.
- 72. Cao J, Gao X, Yang Y, Lei T, Shen Y, Wang L & Tian Z.** Simultaneous or staged operation for tandem spinal stenosis: surgical strategy and efficacy comparison. *Journal of Orthopaedic Surgery and Research* 2021 **16** 214. (<https://doi.org/10.1186/s13018-021-02357-x>)
- 73. Naderi S & Mertol T.** Simultaneous cervical and lumbar surgery for combined symptomatic cervical and lumbar spinal stenoses. *Journal of Spinal Disorders and Techniques* 2002 **15** 229–231; discussion 31–32. (<https://doi.org/10.1097/00024720-200206000-00011>)
- 74. Okada E, Matsumoto M, Ichihara D, Chiba K, Toyama Y, Fujiwara H, Momoshima S, Nishiwaki Y, Hashimoto T, Ogawa J, et al.** Aging of the cervical spine in healthy volunteers: a 10-year longitudinal magnetic resonance imaging study. *Spine* 2009 **34** 706–712. (<https://doi.org/10.1097/BRS.0b013e31819c2003>)
- 75. Bednarik J, Kadanka Z, Dusek L, Novotny O, Surelova D, Urbanek I & Prokes B.** Presymptomatic spondylotic cervical cord compression. *Spine* 2004 **29** 2260–2269. (<https://doi.org/10.1097/01.brs.0000142434.02579.84>)
- 76. Karadimas SK, Erwin WM, Ely CG, Dettori JR & Fehlings MG.** Pathophysiology and natural history of cervical spondylotic myelopathy. *Spine* 2013 **38** (Supplement 1) S21–S36. (<https://doi.org/10.1097/BRS.0b013e3182a7f2c3>)
- 77. Swanson BT.** Tandem spinal stenosis: a case of stenotic cauda equina syndrome following cervical decompression and fusion for spondylotic cervical myelopathy. *Journal of Manual and Manipulative Therapy* 2012 **20** 50–56. (<https://doi.org/10.1179/2042618611Y.0000000010>)
- 78. Chen SH, Hui YL, Yu CM, Niu CC & Lui PW.** Paraplegia by acute cervical disc protrusion after lumbar spine surgery. *Chang Gung Medical Journal* 2005 **28** 254–257.
- 79. Deem S, Shapiro HM & Marshall LF.** Quadriplegia in a patient with cervical spondylosis after thoracolumbar surgery in the prone position. *Anesthesiology* 1991 **75** 527–528. (<https://doi.org/10.1097/0000542-199109000-00022>)
- 80. Young IA, Burns SP & Little JW.** Sudden onset of cervical spondylotic myelopathy during sleep: a case report. *Archives of Physical Medicine and Rehabilitation* 2002 **83** 427–429. (<https://doi.org/10.1053/apmr.2002.29621>)
- 81. Langmayr JJ, Ortler M, Obwegeser A & Felber S.** Quadriplegia after lumbar disc surgery. A case report. *Spine* 1996 **21** 1932–1935. (<https://doi.org/10.1097/00007632-199608150-00021>)
- 82. Ghobrial GM, Oppenlander ME, Maulucci CM, Viereck M, Prasad S, Sharan AD & Harrop JS.** Management of asymptomatic cervical spinal stenosis in the setting of symptomatic tandem lumbar stenosis: a review. *Clinical Neurology and Neurosurgery* 2014 **124** 114–118. (<https://doi.org/10.1016/j.clineuro.2014.06.012>)
- 83. Eskander MS, Aubin ME, Drew JM, Eskander JP, Balsis SM, Eck J, Lapinsky AS & Connolly PJ.** Is there a difference between simultaneous or staged decompressions for combined cervical and lumbar stenosis? *Journal of Spinal Disorders and Techniques* 2011 **24** 409–413. (<https://doi.org/10.1097/BSD.0b013e318201bf94>)
- 84. Alvin MD, Alentado VJ, Lubelski D, Benzel EC & Mroz TE.** Cervical spine surgery for tandem spinal stenosis: the impact on low back pain. *Clinical Neurology and Neurosurgery* 2018 **166** 50–53. (<https://doi.org/10.1016/j.clineuro.2018.01.024>)
- 85. Felbaum DR, Fayed I, Stewart JJ & Sandhu FA.** Relief of lumbar symptoms After cervical decompression in patients with tandem spinal stenosis presenting with primarily lumbar pain. *Cureus* 2016 **8** e940. (<https://doi.org/10.7759/cureus.940>)
- 86. Kawakita E, Kasai Y & Uchida A.** Low back pain and cervical spondylotic myelopathy. *Journal of Orthopaedic Surgery* 2009 **17** 187–189. (<https://doi.org/10.1177/230949900901700213>)
- 87. Inoue T, Ando K, Kobayashi K, Nakashima H, Ito K, Katayama Y, Machino M, Kanbara S, Ito S, Yamaguchi H, et al.** Primary cervical decompression surgery may improve lumbar symptoms in patients with tandem spinal stenosis. *European Spine Journal* 2021 **30** 899–906. (<https://doi.org/10.1007/s00586-020-06693-0>)
- 88. Langfitt TW & Elliott FA.** Pain in the back and legs caused by cervical spinal cord compression. *JAMA* 1967 **200** 382–385.
- 89. Boccanera L & Laus M.** Cauda equina syndrome following lumbar spinal stenosis surgery. *Spine* 1987 **12** 712–715. (<https://doi.org/10.1097/00007632-198709000-00014>)
- 90. Hu PP, Yu M, Liu XG, Liu ZJ & Jiang L.** Surgeries for patients with tandem spinal stenosis in cervical and thoracic spine: combined or staged surgeries? *World Neurosurgery* 2017 **107** 115–123. (<https://doi.org/10.1016/j.wneu.2017.07.129>)
- 91. Zhao BL, Ji C, Jiang JJ & Yin RF.** Clinical effectiveness of treatment of combined upper thoracic spinal stenosis and multilevel cervical spinal stenosis with different posterior decompression surgeries. *International Journal of Surgery* 2018 **55** 220–223. (<https://doi.org/10.1016/j.ijsu.2018.02.060>)
- 92. Miyakoshi N, Shimada Y, Suzuki T, Hongo M, Kasukawa Y, Okada K & Itoi E.** Factors related to long-term outcome after decompressive surgery for ossification of the ligamentum flavum of the thoracic spine. *Journal of Neurosurgery* 2003 **99** (Supplement 3) 251–256. (<https://doi.org/10.3171/spi.2003.99.3.0251>)
- 93. Shepard NA, Shenoy K, Cho W & D Sharan A.** Extensive ossification of the ligamentum flavum treated with triple stage decompression: a case report. *Spine Journal* 2015 **15** e9–e14. (<https://doi.org/10.1016/j.spinee.2014.12.011>)
- 94. Yu L, Li B, Yu Y, Li W, Qiu G & Zhao Y.** The relationship Between dural ossification and spinal stenosis in thoracic ossification of the ligamentum flavum. *Journal of Bone and Joint Surgery: American Volume* 2019 **101** 606–612. (<https://doi.org/10.2106/JBJS.17.01484>)
- 95. Schaffer JC, Raudenbush BL, Molinari C & Molinari RW.** Symptomatic triple-region spinal stenosis treated with simultaneous surgery: case report and review of the literature. *Global Spine Journal* 2015 **5** 513–521. (<https://doi.org/10.1055/s-0035-1566226>)

- 96. Hong CC & Liu KP.** A rare case of multiregional spinal stenosis: clinical description, surgical complication, and management concept review. *Global Spine Journal* 2015 **5** 49–54. (<https://doi.org/10.1055/s-0034-1378139>)
- 97. Cloyd JM, Acosta FL, Jr & Ames CP.** Complications and outcomes of lumbar spine surgery in elderly people: a review of the literature. *Journal of the American Geriatrics Society* 2008 **56** 1318–1327. (<https://doi.org/10.1111/j.1532-5415.2008.01771.x>)
- 98. Best NM & Sasso RC.** Outpatient lumbar spine decompression in 233 patients 65 years of age or older. *Spine* 2007 **32** 1135–1139; discussion 1140. (<https://doi.org/10.1097/01.brs.0000261486.51019.4a>)
- 99. Raffo CS & Lauerman WC.** Predicting morbidity and mortality of lumbar spine arthrodesis in patients in their ninth decade. *Spine* 2006 **31** 99–103. (<https://doi.org/10.1097/01.brs.0000192678.25586.e5>)
- 100. Xu F, Tian Z, Qu Z, Yao L, Zou C, Han W, Zhang C, Fu C & Wang Y.** Completely ossified thoracic intradural meningioma in an elderly patient: a case report and literature review. *Medicine* 2020 **99** e20814. (<https://doi.org/10.1097/MD.00000000000020814>)
- 101. Luo W, Sun RX, Jiang H & Ma XL.** The effect of diabetes on perioperative complications following spinal surgery: a meta-analysis. *Therapeutics and Clinical Risk Management* 2018 **14** 2415–2423. (<https://doi.org/10.2147/TCRM.S185221>)