

Evidence for operative treatment of talar osteochondral lesions: a systematic review

Helen Anwander¹, Philipp Vetter¹, Christophe Kurze¹, Chui J Farn^{1,2} and Fabian G Krause¹

¹Department of Orthopaedic Surgery and Traumatology, Inselspital, Bern University Hospital, University of Bern, Bern, Switzerland

²Department of Orthopedic Surgery, National Taiwan University Hospital, Taiwan, Republic of China

Correspondence should be addressed to H Anwander

Email
Helen.anwander@insel.ch

- **Purpose:** Operative treatment of talar osteochondral lesions is challenging with various treatment options. The aims were (i) to compare patient populations between the different treatment options in terms of demographic data and lesion size and (ii) to correlate the outcome with demographic parameters and preoperative scores.
- **Methods:** A systemic review was conducted according to the PRISMA guidelines. The electronic databases Pubmed (MEDLINE) and Embase were screened for reports with the following inclusion criteria: minimum 2-year follow-up after operative treatment of a talar osteochondral lesion in at least ten adult patients and published between 2000 and 2020.
- **Results:** Forty-five papers were included. Small lesions were treated using BMS, while large lesions with ACI. There was no difference in age between the treatment groups. There was a correlation between preoperative American Orthopaedic Foot and Ankle Society (AOFAS) score and change in AOFAS score ($R = -0.849$, $P < 0.001$) as well as AOFAS score at follow-up ($R = 0.421$, $P = 0.008$). Preoperative size of the cartilage lesion correlates with preoperative AOFAS scores ($R = -0.634$, $P = 0.001$) and with change in AOFAS score ($R = 0.656$, $P < 0.001$) but not with AOFAS score at follow-up. Due to the heterogeneity of the studies, a comparison of the outcome between the different operative techniques was not possible.
- **Conclusion:** Patient groups with bigger lesions and inferior preoperative scores did improve the most after surgery.
- **Level of evidence:** IV.

Keywords

- ▶ osteochondral lesion
- ▶ talus
- ▶ operative treatment
- ▶ systematic review

EFORT Open Reviews
(2022) 7, 460–469

Introduction

An osteochondral lesion of the talus (OLT) is defined as damage to the talar cartilage with pathological changes in the underlying bone. OLTs are associated with residual pain following an acute ankle sprain or in patients with chronic ankle instability. It has been shown that mainly the physical component of patients' quality of life is impacted by an OLT (1). Untreated, an ankle with OLT may predispose to progressive degeneration of the entire joint. Primary management of OLT is conservative treatment including restriction of physical activity, weight-bearing, physiotherapy and orthopedic insoles to distribute the load in the ankle joint properly. The conservative treatment of symptomatic OLT achieves a success rate of 50% (2, 3). Numerous invasive therapies have been described; however, consensus particularly for bigger lesions has yet to be found (4).

The first operative treatment introduced was the sole debridement of unstable cartilage. Today, bone marrow stimulation (5) (BMS) (i.e. microfracture and drilling) is the most common technique to stimulate fibrocartilage differentiation in the ankle with OLT up to 1–1.5 cm² in size. BMS can be supported by applying additional material such as hyaluronic acid. The sealing of the defect with a collagen matrix after BMS describes the technique of autologous matrix-induced chondrogenesis (AMIC) (6).

Autologous chondrocyte implantation (ACI) (7) is a two-step procedure. Initially, healthy cartilage is sampled from a non-weight-bearing area, mainly in the knee joint. Chondrocytes are grown *in vitro* for several weeks and, in a second surgery, implanted into the talar defect and covered with periosteum or a biomembrane. In matrix-induced ACI (MACI), the chondrocytes are placed on a membrane in the laboratory and this membrane with the chondrocytes attached to it is placed into the

defect. In contrast to fibrocartilage after BMS, the ACI and MACI techniques lead to the growth of hyaline-like cartilage. Bone marrow contains mesenchymal stem cells; subsequently, application of bone marrow aspirate has been proposed to provide hyaline-like cartilage.

In OLT with a cyst or too big for BMS, osteochondral autologous transplantation surgery (OATS) (8) has been introduced. OATS describes the transplantation of osteochondral cylinders (mainly from the knee) into the talar lesion. However, ACI, MACI and OATS come with a donor site morbidity in a before healthy knee joint. To minimize this disadvantage, osteo-periosteal autograft and allograft have been introduced for the treatment of big OLTs. As gold standard treatment of OLT has yet to be found, the experimental techniques are constantly introduced.

The objective of this review is to compare the indications and effectiveness of all reported operative treatment options for OLTs in the adult population.

The first aim was to compare patient populations between the different treatment options in terms of demographic data and lesion size. The second aim was to correlate the outcome with demographic parameters and preoperative scores.

Our first hypothesis is that BMS was used for smaller lesions and OATS for bigger lesions compared to other treatment options. Our second hypothesis is that young patients with small lesions have a superior outcome than older patients with bigger lesions.

Methods

This is a systematic review conducted according to the Preferred Reporting Items for Systematic Reviews and Meta-Analyses (PRISMA) guidelines. The checklist as published by Page *et al.* was used (9). There was no funding for this study.

Literature research

The systematic review was conducted as follows: Electronic databases Pubmed (MEDLINE) and Embase were screened for reports published between January 2000 to December 2020. Additionally, a backward citation chaining strategy was applied.

The following keywords were included for the search: (Talus OR talus OR talar* OR ankle) AND (Osteochondritis Dissecans OR Osteochondritis dissecans OR osteochondrosis dissecans OR osteochondrolysis OR OCL OR OCD OR OLT OR osteochondral OR chondral OR transchondral OR cartilage*) AND (defect* OR lesion*). After the removal of duplications, this search resulted in 1653 records.

Selection criteria

Inclusion criteria were a randomized controlled trial (RCT) or an observational study assessing the outcome

after operative treatment for OLT in a study group of at least ten patients aged 16 years and older. Twenty-four months represent the minimum maturation time for the newly formed cartilage tissue (10); subsequently, we chose 2 years as minimum follow-up. Operative treatment included arthroscopic as well as open cartilage treatment. One rationale to exclude case series with less than ten patients and studies with only a short-time follow-up was to exclude papers of low quality.

However, we did include studies with level of evidence I–IV and low methodological quality. The rationale to not conduct a level I meta-analysis is based on the available research around OLT with only sparse high-level evidence. Exclusion criteria were the following: text in a language other than English, no full text available and any other publication status than published.

Independent search and evaluation of the articles was conducted by two reviewers (HA and PV). In case of disagreement, the senior author made the decision which paper can be included. Studies were not blinded for author, affiliation or source. The literature selection algorithm is presented according to the preferred reporting items for systematic reviews and meta-analyses (PRISMA) (Fig. 1) (11).

PRISMA flow diagram

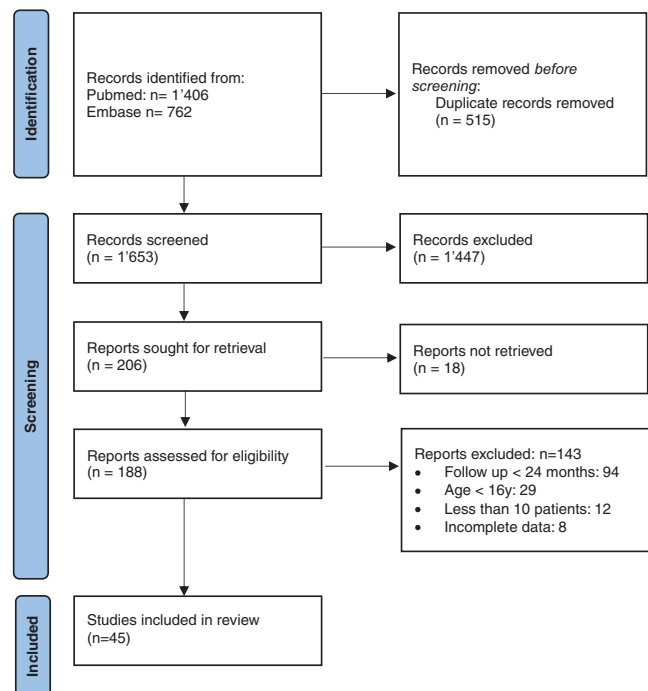


Figure 1

Flowchart of the literature research according to the preferred reporting items for systematic reviews and meta-analyses (PRISMA).

After application of the inclusion and exclusion criteria, 45 studies were finalized.

Data extraction

The following paper characteristics were retrieved: year of publication, journal, type of study and level of evidence. The following patient data were retrieved: number of patients, mean age, gender, previous surgery, time to follow-up, size of OLT, treatment method, concomitant surgery and clinical scoring system used. Preoperative clinical scores and results at last follow-up were extracted.

The most often reported outcome score was the American Orthopaedic Foot and Ankle Society (AOFAS) score (33 papers out of 45). Twenty-six of these 33 papers also included the s.d., the 95% CI or reported the scores for each included patient; subsequently, these studies could be used for quantitative analysis. The second most often reported score was the Visual Analogue Scale (VAS) for pain. Twenty-five papers included the VAS for pain, therefrom 20 papers included the s.d. As less than 50% of all 45 papers included the VAS with s.d., VAS was not included in the quantitative analysis.

Operative techniques

Treatment strategies were divided into the following three main groups: BMS, cartilage implantation and grafts. BMS was further subdivided into three subgroups: (i) BMS alone, (ii) BMS with additional therapies such as the application of bone marrow aspirate, hyaluronic acid or

special scaffolds and (iii) AMIC. Cartilage implantation was subdivided into (i) ACI and (ii) MACI. The grafts were subdivided into (i) OATS, (ii) autograft of bone such as iliac crest and (iii) allograft (Fig. 2).

Statistical analysis

Clinical scores preoperative and at latest follow-up, age and gender of patients as well as size of the lesion were analyzed for each included study. Additionally, data from different studies describing the results of similar treatment groups using analogous scores were pooled. 95% CI was calculated using the following formula: mean value ± 1.96 × s.d./√(number of patients). The age of patients was compared between the treatment groups using one-way Anova. The size of lesions in patients was compared between the treatment groups using Student's t-test. Pearson's chi square was used to compare gender between the treatment groups.

Clinical scores, age and size of the lesion were correlated using Pearson's correlation. A value of R > 0.7 is considered a strong correlation, 0.4–0.7 a moderate correlation and < 0.4 a weak correlation. Twenty-six papers included the AOFAS score preoperative and at follow-up and s.d. at both time points. Of these 26 papers, 4 papers presented the scores for 2 different treatment methods, leading to a total of 30 patient groups available for analysis. A forest plot including the AOFAS score preoperative and at follow-up per separate study as well as the pooled results of each treatment group was conducted.

Flowchart of surgical techniques

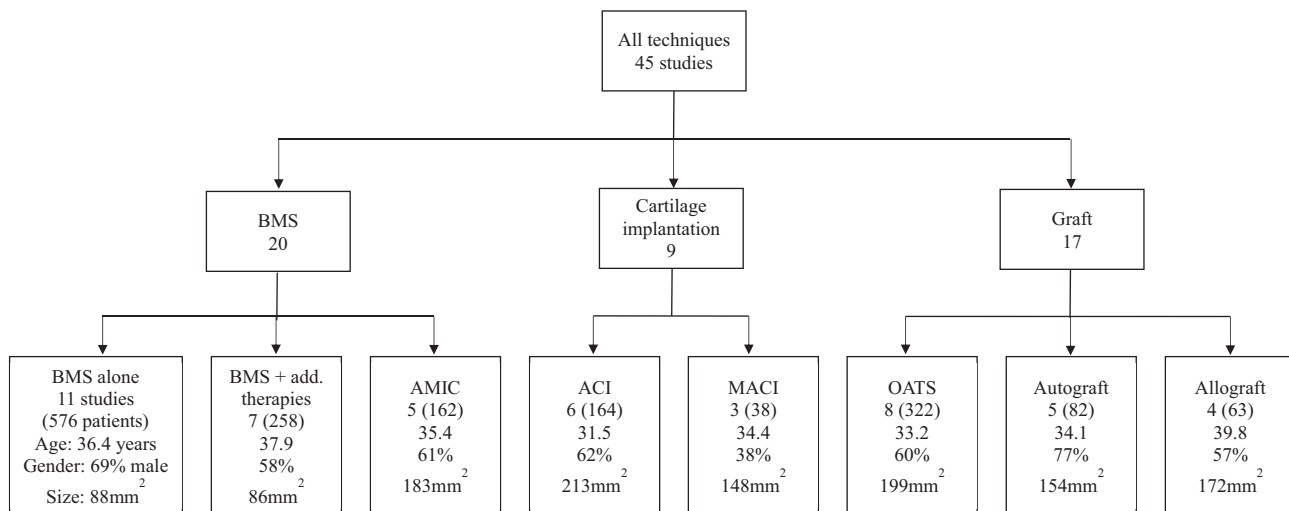


Figure 2

Flowchart of the operative techniques described in the included papers. Four papers included ≥10 patients in more than one treatment group. BMS, bone marrow stimulation; AMIC, autologous matrix-induced chondrogenesis; ACI, autologous chondrocyte implantation; MACI, matrix-induced ACI; OATS, osteochondral autologous transplantation surgery; + add. therapies, with additional therapies.

Table 1 Studies included in this systematic review with a follow up of at least 24 months after an operative treatment of OLT.

Operation technique/ reference	Patients, n	Age, years	OLT size, cm ²	FUP, months	AOFAS score		VAS pain		Other scores
					Before FUP	At FUP	Before FUP	At FUP	
Bone marrow stimulation									
Saxena & Eakin (13)	26	36.2		32	54.6 ± 8.4	94.4 ± 6.2	6.5 ± 2.3	2.4 ± 2.8	VAS function, VAS satisfaction
Becher et al. (14)	45	40.0		70	73.6 ± 12.5	96.1 ± 6.0			Karlsson-Peterson score, Tegner score, Sefton scale
De Lima et al. (15)	24	35.3		27	60.2 ± 7.8	89.4 ± 7.1			Ankle activity score
Ventura et al. (16)	38	39.0	1.00	60					Foot and ankle outcome score complete
Van Eekeren et al. (17)	93	32.6		118	52.3 ± 12.1	79.1 ± 10.6	7.3 ± 1.5	4.3 ± 2.0	Foot function index
Gao et al. (18)	28	47.4	1.10	49			6.3 ± 1.1	1.6 ± 1.0	Foot and ankle outcome score complete, Short form -36, Short form-12
Murphy et al. (19)	52	39.7		58	71.1 ± 11.5	91.8 ± 8.1	6.2	1.7	Foot and ankle outcome score complete
Wang et al. (20)	31	23.0	1.10	28	71.0	89.5			Foot and ankle outcome score complete
Choi et al. (21)	156	35.4	0.73	80			2.7	1.0	Hannover scoring system for the ankle
Lambers et al. (22)	60	39.0		77	69.3 ± 18	86.9 ± 10.7	5.9 ± 2.0	1.9 ± 1.9	
Lee et al. (23)	23	39.0	1.09	24			5.6 ± 1.0	1.8 ± 0.9	
Bone marrow stimulation with additional therapy									
Sadlik et al. (24)	10	37.0	1.32	46	58.3 ± 8.5	81.8 ± 15.5	6.9 ± 1.4	1.2 ± 1.1	
Di Cave et al. (27)	12	38.6		90	47.2 ± 10.7	84.4 ± 8.0			
Gao et al. (18)	41	43.1	1.10	49	51.9 ± 11.9	89.5 ± 11.7			
Shimozono et al. (25)	43	38.4	0.46	52			6.8 ± 1.7	3.4 ± 1.8	Foot and ankle outcome score pain
Murphy et al. (19)	49	34.6		40	72.2 ± 12	91 ± 8.6	5.2 ± 2.0	1.7 ± 2.0	Foot and ankle outcome score complete
Lee et al. (23)	22	35.0	0.97	24	55 ± 16.2	83 ± 10.1	7.4 ± 1.3	2.5 ± 1.6	Hannover scoring system for the ankle
Akmes et al. (26)	42			24	53 ± 17.6	80 ± 11.6	7.8 ± 1.4	2.9 ± 1.6	
Akmes et al. (26)	39			24					
Autologous matrix-induced chondrogenesis									
Wiewiorski et al. (28)	60	34.9		47	43 ± 15	76 ± 17	6.9 ± 1.6	2.3 ± 1.9	Short form -36
D' Ambrosi et al. (29)	31	35.0	1.54	27	53 ± 15.6	89 ± 10.8	7.8 ± 1.4	1.8 ± 1.5	
Kanaili et al. (32)	32	38.0	2.50	34	52.8 ± 13.9	87.1 ± 11.1			VAS function, VAS satisfaction, Hannover scoring system for the ankle
Becher et al. (30)	16	32.4	1.06	68			8.7 ± 2.1	3.3 ± 2.3	Foot function index
Galla et al. (31)	23	35.6		34			7.6 ± 1.1	1.4 ± 2.2	
Autologous chondrocyte implantation									
Baums et al. (33)	12	29.7	2.30	63	43.5	88.4	7.8	1.3	Hannover scoring system for the ankle
Giannini et al. (34)	48	28.5	2.07	29	64.4 ± 14.5	91.4 ± 7.7			
Giannini et al. (35)	56	30.0	2.55	60	53.6 ± 14.7	89.9 ± 12.1			
Lee et al. (36)	38	35.0	1.94	24	71 ± 14	91 ± 12	5.8 ± 2.2	2.1 ± 2.3	Hannover scoring system for the ankle
Kwak et al. (37)	29	34.0	1.98	70	50.1	85.9			Tegner score, Finsen score
Puddu et al. (38)	11	36.0	1.04	47	62 ± 12	94 ± 8			
Matrix-induced autologous chondrocyte implantation									
Giza et al. (43)	10	40.2	1.29	24	61.2 ± 13.8	73.3 ± 20.8			Cincinnati rating, subjective ankle-hindfoot score
Nehrer et al. (45)	13	28.0	1.50	61	55.6 ± 18.8	86.2 ± 8.6			
Lenz et al. (44)	15	36.0	1.60	144	60 ± 15	84 ± 8			Hannover scoring system
Osteochondral autologous transplantation surgery									
Hangody et al. (46)	36	27.0	1.00	50					
Kreuz et al. (47)	35	30.9		49	54.5	89.9			
Gobbli et al. (48)	12	27.8	3.70	24	31.1	85.4			
Imhoff et al. (49)	25	33.0		84	50 ± 17.8	78 ± 20	7.8 ± 2.0	1.5 ± 2.3	Tegner score
Georgiannos et al. (50)	46	36.2		66	55 ± 4.2	90 ± 5.8	4.8 ± 0.7	0.9 ± 0.8	
Gül et al. (51)	28	34.6	1.31	30	58	91.3	7.5	2.2	Roles and Maudsly score
Park et al. (52)	46	34.1	1.95	72			6.2 ± 1.3	1.8 ± 1.0	Foot and ankle outcome score pain, Short form -12
Shimozono et al. (53)	94	35.0		45					

(Continued)

Table 1 Continued.

Operation technique/ reference	Patients, n	Age, years	OLT size, cm ²	FUP, months	AOFAS score		VAS pain		Other scores
					Before FUP	At FUP	Before FUP	At FUP	
Autograft									
Saxena et al. (13)	20	36.8		32	46.1 ± 14.6	93.4 ± 10.2			
Leumann et al. (54)	13	39.6	1.73	25	47.0 ± 11.0	81 ± 14	6.6 ± 1.3	1.4 ± 1.9	
Hu et al. (55)	16	37.3		33	75 ± 2.4	90 ± 6.3	5.5 ± 0.8	1.0 ± 1.0	
Hintermann et al. (56)	14	34.8	1.36	49	65	81	5.8	1.8	
Bai et al. (57)	19	24.3		24	73 ± 4.8	95 ± 4.1	4.7 ± 0.7	0.5 ± 0.6	
Allograft									
Raikin et al. (39)	15	41.9		54	38	83	8.5	3.3	Olerud-Molander ankle score
Görtz et al. (40)	11	35.5		38					Short form -36
Berlet et al. (41)	12	39.9	1.50	40	61 ± 9	79 ± 6			Short form -12
Chu et al. (42)	25	40.4	1.82	66	75 ± 11.5	94 ± 5	4.4 ± 1.4	1.2 ± 0.4	

Results

Characteristics of the patients

The 45 assessed studies reported the outcome of total 1695 patients (Table 1). The mean age at time of surgery was 35.4 years old, and 63% were male. Thirty-two studies reported the size of the lesion with a mean size of 1.4 cm². Fifteen studies assessed only patients with no previous surgery of the OLT, 6 studies assessed only revisions and 22 studies included both or did not declare it.

Quality of evidence

This review included one RCT, 12 prospective and 32 retrospective cohort studies. Thirty-four studies were classified as level 4 based on the criteria for level of evidence published by the Center for Evidence-Based Medicine (12). In recent years, the number of published studies meeting the inclusion criteria rose (Fig. 3).

Operative techniques

The most often reported operative technique was BMS alone with 11 papers including 576 patients (13, 14, 15, 16, 17, 18, 19, 20, 21, 22, 23). More than half of the patients (996/total 1695 patients) received BMS alone, BMS with an additional therapy (18, 19, 23, 24, 25, 26, 27) or AMIC (28, 29, 30, 31, 32).

BMS alone and BMS with an additional therapy were used in smaller lesions (0.88 cm² and 0.86 cm², respectively) than the other therapies (1.86 cm², P < 0.001). Figure 2 The biggest lesions (mean 2.13 cm²) were treated with ACI (33, 34, 35, 36, 37, 38). ACI was also used in youngest patient group (mean 31.5 years old), and allograft (39, 40, 41, 42) was implanted in the oldest patients with an average age of nearly 40 years. However, there was no statistical difference in age between the treatment groups (P=0.092). Three studies reported the outcome of 38 patients after MACI (43, 44, 45), 8 studies included 322 patients with OATS (46, 47, 48, 49, 50, 51, 52, 53) and 5 studies used autograft in 82 patients (13, 54, 55, 56, 57).

BMS was mostly used on primary OLT. Cartilage implantation techniques and grafts were mainly published in revision cases or mixed groups.

In 15 studies (33%), concomitant surgeries addressing an instability or deformity were conducted if necessary. In six studies, patients with additional surgeries other than the procedure for the OLT were excluded. In ten studies, patients with an instability were excluded; however, it is not specified if all patients with additional surgeries were excluded. The remaining 14 papers did not mention if additional surgeries were conducted and the authors did not reply to repeated inquiries.

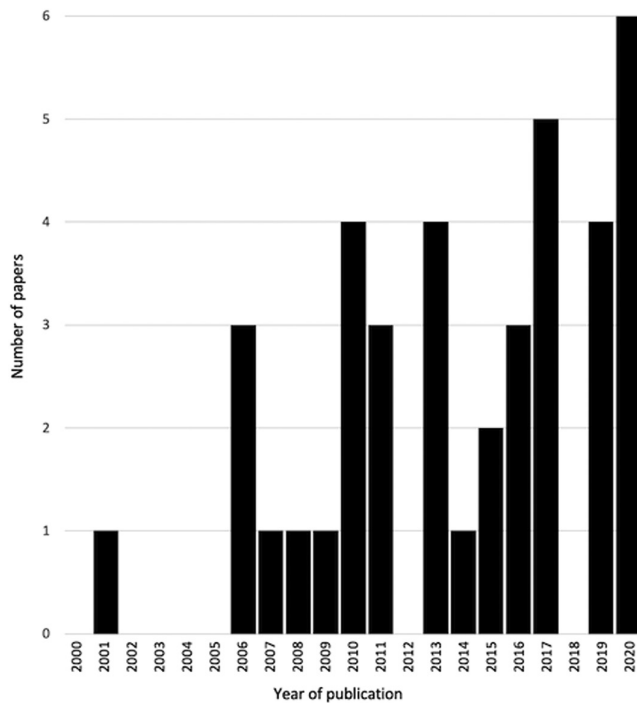


Figure 3 Diagram of the quantity of papers published between 2000 and 2020.

Outcome scores

The most often reported outcome score was the AOFAS score. In Figure 4A and B, a total of 16 clinical scores have been published (Table 1).

There is a strong inverse correlation between the preoperative AOFAS score and the change in the AOFAS score ($R = -0.849, P < 0.001$) (Figure 5). There is a moderate correlation between the preoperative AOFAS score and AOFAS score at follow-up ($R = 0.421, P = 0.008$). Preoperative size of the cartilage lesion correlates with preoperative AOFAS scores ($R = -0.634, P = 0.001$) and with change in AOFAS score ($R = 0.656, P < 0.001$) but not with AOFAS score at follow-up.

Age of the patients at the time of surgery did not correlate with preoperative AOFAS score or change of AOFAS score, but there was a weak inverse correlation with AOFAS score at the time of follow-up ($R = -0.335, P = 0.046$).

Discussion

This systematic review showed a correlation of the preoperative AOFAS score with the increase of the score as well as with the outcome score. This indicates that a group of patients with inferior preoperative scores will profit more by having a bigger increase in clinical scores

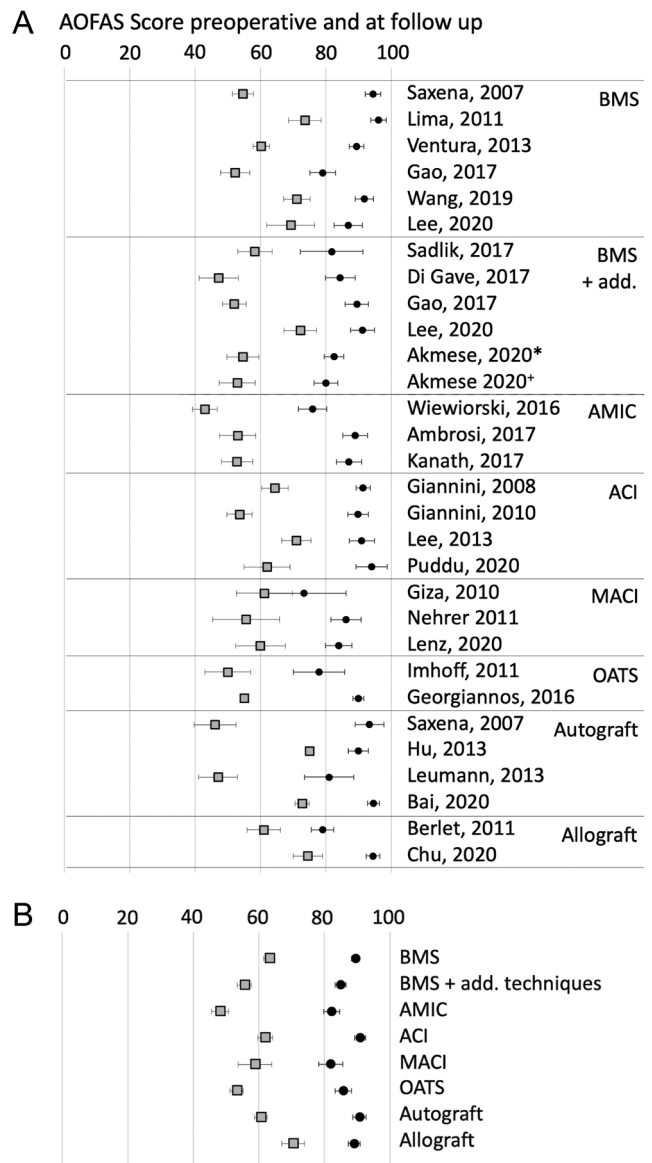


Figure 4 (A) Forest plot of AOFAS score preoperative and at follow-up per separate study. x-axis: AOFAS score from 0 to 100, the squares display the mean AOFAS score with error bar displaying the 95% CI, *chiton-based scaffold, +hyaluron based scaffold, AOFAS, American Orthopaedic Foot and Ankle Society; BMS, bone marrow stimulation; +add., with additional therapies; AMIC, autologous matrix-induced chondrogenesis; ACI, autologous chondrocyte implantation; MACI, matrix-induced ACI; OATS, osteochondral autologous transplantation surgery. (B) Forest plot of AOFAS score preoperative and at follow-up for pooled studies. x-axis: AOFAS score from 0 to 100, the squares display the mean AOFAS score with error bar displaying the 95% CI, AOFAS, American Orthopaedic Foot and Ankle Society; BMS, bone marrow stimulation; +add., with additional therapies; AMIC, autologous matrix-induced chondrogenesis; ACI, autologous chondrocyte implantation; MACI, matrix-induced ACI; OATS, osteochondral autologous transplantation surgery.

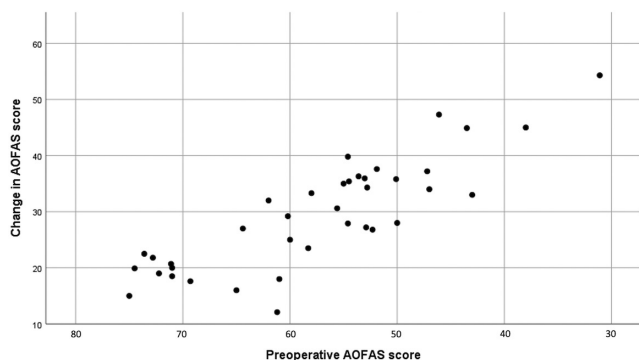


Figure 5 Diagram displaying preoperative AOFAS score and change of AOFAS score after surgery for OCL on the talus. x-axis: preoperative AOFAS score from 80 to 30 (best: 100, worst: 0), y-axis: change of AOFAS score between preoperative and last follow-up. AOFAS, American Orthopaedic Foot and Ankle Society.

but will not reach the same level 2 years postoperatively as a group of patients with higher preoperative scores.

When focusing on the size of the lesion, patients with a bigger lesion had inferior preoperative AOFAS scores, profited more and reached similar levels at follow-up as patients with a smaller lesion.

In the literature, inferior outcome in bigger lesions was found after BMS. The proposed cut off point was set at 1.07–1.5 cm² for the indication of BMS in OLT (58, 59). In the papers included in this review, BMS was used for smaller, mainly primary lesions with a mean size below 1 cm². Considering all the papers, we found no correlation between lesion size and outcome. However, patients with a bigger lesion did suffer more preoperatively and did profit more from the operation. This implies that patients with bigger and more symptomatic lesions are not too late for treatment but will show the most improvement after surgery, at least not up to a size of 200 mm² as reported in the literature included in this review. While BMS is proposed to be reserved for smaller lesions, other surgical techniques have been proven successful also in bigger lesions. The future however will show which technique will become the most accepted for OLTs over 1–1.5 cm².

The inferior outcome in older patients after BMS and AMIC was published corresponding to the findings in this review with a weak inverse correlation between age and outcome scores (14, 29). In one-third of the studies, concomitant surgeries addressing an instability or deformity were conducted. In our opinion, in patients with an underlying cause for the OLT, the therapy of this cause is essential for the successful treatment of the OLT.

The limitations of a systematic review include publication bias and selective reporting. Most papers in this review were of low methodological quality, underlining once more the necessity for more sufficiently

powered randomized studies with extended follow-up times in future research. To diminish poorly conducted studies, strict inclusion criteria were applied, such as a minimum follow-up of 24 months, minimum age of 16 years old and a minimal count of ten patients included in the follow-up. A second limitation is that only papers in English were included. Further, complication ratios and revision rate were rarely stated and subsequently could not be analyzed.

Due to the observed heterogeneity of the patient population (e.g. level of the preoperative scores and size of the lesion), variety in the outcome assessment and incomplete data publication, the conduction of a meta-analysis regarding the outcome after different treatment options was not possible. In future research, a validated score for the OLT needs to be established in order to increase the homogeneity and uniformity in outcome assessment and evaluation of the results. The increase in publications on OLT in recent years shows the current importance of the topic.

Conclusion

In this systematic review, we found that patients with bigger and more symptomatic OLTs profited the most from surgery. BMS was the most often reported operative technique and was used for smaller, mainly primary lesions with a mean lesion size below 1 cm². Direct comparison of the outcome between the different treatment groups was not possible due to the heterogeneity of the patient population.

ICMJE Conflict of Interest Statement

The authors declare that there is no conflict of interest that could be perceived as prejudicing the impartiality of the work reported here.

Funding Statement

The funding for this research was from the Department of Orthopaedic Surgery and Traumatology, Inselspital, Bern University Hospital, University of Bern, Switzerland.

References

1. D'Ambrosi R, Maccario C, Serra N, Ursino C & Uselli FG. Relationship between symptomatic osteochondral lesions of the talus and quality of life, body mass index, age, size and anatomic location. *Foot and Ankle Surgery* 2018 **24** 365–372. (<https://doi.org/10.1016/j.fas.2017.04.011>)
2. Verhagen RA, Struijs PA, Bossuyt PM & van Dijk CN. Systematic review of treatment strategies for osteochondral defects of the talar dome. *Foot and Ankle Clinics* 2003 **8** 233–242, viii–ix. ([https://doi.org/10.1016/s1083-7515\(02\)00064-5](https://doi.org/10.1016/s1083-7515(02)00064-5))
3. Shearer C, Loomer R & Clement D. Nonoperatively managed stage 5 osteochondral talar lesions. *Foot and Ankle International* 2002 **23** 651–654. (<https://doi.org/10.1177/107110070202300712>)

- 4. Dahmen J, Lambers KTA, Reilingh ML, van Bergen CJA, Stufkens SAS & Kerkhoffs GMMJ.** No superior treatment for primary osteochondral defects of the talus. *Knee Surgery, Sports Traumatology, Arthroscopy* 2018 **26** 2142–2157. (<https://doi.org/10.1007/s00167-017-4616-5>)
- 5. Pridie K.** A method of resurfacing osteoarthritic knee joint. *Journal of Bone and Joint Surgery: British Volume* 1959 **41** 618–619.
- 6. Behrens P.** Matrixgekoppelte Mikrofrakturierung Ein neues Konzept zur Knorpeldefektbehandlung. *Arthroscopie* 2005 **18** 193–197. (<https://doi.org/10.1007/s00142-005-0316-0>)
- 7. Brittberg M, Lindahl A, Nilsson A, Ohlsson C, Isaksson O & Peterson L.** Treatment of deep cartilage defects in the knee with autologous chondrocyte transplantation. *New England Journal of Medicine* 1994 **331** 889–895. (<https://doi.org/10.1056/NEJM199410063311401>)
- 8. Outerbridge HK, Outerbridge AR & Outerbridge RE.** The use of a lateral patellar autologous graft for the repair of a large osteochondral defect in the knee. *Journal of Bone and Joint Surgery: American Volume* 1995 **77** 65–72. (<https://doi.org/10.2106/00004623-199501000-00009>)
- 9. Page MJ, McKenzie JE, Bossuyt PM, Boutron I, Hoffmann TC, Mulrow CD, Shamseer L, Tetzlaff JM, Akl EA, Brennan SE, et al.** The PRISMA 2020 statement: an updated guideline for reporting systematic reviews. *International Journal of Surgery* 2021 **88** 105906. (<https://doi.org/10.1016/j.ijsu.2021.105906>)
- 10. Goebel L, Orth P, Muller A, Zurakowski D, Buckner A, Cucchiari M, Pape D & Madry H.** Experimental scoring systems for macroscopic articular cartilage repair correlate with the MOCART score assessed by a high-field MRI at 9.4 T – comparative evaluation of five macroscopic scoring systems in a large animal cartilage defect model. *Osteoarthritis and Cartilage* 2012 **20** 1046–1055. (<https://doi.org/10.1016/j.joca.2012.05.010>)
- 11. Liberati A, Altman DG, Tetzlaff J, Mulrow C, Gotzsche PC, Ioannidis JP, Clarke M, Devereaux PJ, Kleijnen J & Moher D.** The PRISMA statement for reporting systematic reviews and meta-analyses of studies that evaluate health care interventions: explanation and elaboration. *Journal of Clinical Epidemiology* 2009 **62** e1–e34. (<https://doi.org/10.1016/j.jclinepi.2009.06.006>)
- 12. Burns PB, Rohrich RJ & Chung KC.** The levels of evidence and their role in evidence-based medicine. *Plastic and Reconstructive Surgery* 2011 **128** 305–310 (<https://doi.org/10.1097/PRS.0b013e318219c171>)
- 13. Saxena A & Eakin C.** Articular talar injuries in athletes: results of microfracture and autogenous bone graft. *American Journal of Sports Medicine* 2007 **35** 1680–1687. (<https://doi.org/10.1177/0363546507303561>)
- 14. Becher C, Driessen A, Hess T, Longo UG, Maffulli N & Thermann H.** Microfracture for chondral defects of the talus: maintenance of early results at midterm follow-up. *Knee Surgery, Sports Traumatology, Arthroscopy* 2010 **18** 656–663. (<https://doi.org/10.1007/s00167-009-1036-1>)
- 15. de Lima E, de Queiroz F, Lopes OV, Jr & Spinelli Lde Lde F.** Treatment of osteochondral lesions of the talus by means of thearthroscopy-assisted microperforation technique. *Revista Brasileira de Ortopedia* 2011 **46** 702–708. ([https://doi.org/10.1016/S2255-4971\(15\)30328-1](https://doi.org/10.1016/S2255-4971(15)30328-1))
- 16. Ventura A, Terzaghi C, Legnani C & Borgo E.** Treatment of post-traumatic osteochondral lesions of the talus: a four-step approach. *Knee Surgery, Sports Traumatology, Arthroscopy* 2013 **21** 1245–1250. (<https://doi.org/10.1007/s00167-012-2028-0>)
- 17. van Eekeren IC, van Bergen CJ, Sierevelt IN, Reilingh ML & van Dijk CN.** Return to sports after arthroscopic debridement and bone marrow stimulation of osteochondral talar defects: a 5- to 24-year follow-up study. *Knee Surgery, Sports Traumatology, Arthroscopy* 2016 **24** 1311–1315. (<https://doi.org/10.1007/s00167-016-3992-6>)
- 18. Gao F, Chen N, Sun W, Wang B, Shi Z, Cheng L, Li Z & Guo W.** Combined therapy with shock wave and retrograde bone marrow-derived cell transplantation for osteochondral lesions of the talus. *Scientific Reports* 2017 **7** 2106. (<https://doi.org/10.1038/s41598-017-02378-9>)
- 19. Murphy EP, McGoldrick NP, Curtin M & Kearns SR.** A prospective evaluation of bone marrow aspirate concentrate and microfracture in the treatment of osteochondral lesions of the talus. *Foot and Ankle Surgery* 2019 **25** 441–448. (<https://doi.org/10.1016/j.fas.2018.02.011>)
- 20. Wang C, Kang MW & Kim HN.** Arthroscopic treatment of osteochondral lesions of the talus in a suspended position with the patient in a prone position. *Foot and Ankle International* 2019 **40** 811–817. (<https://doi.org/10.1177/1071100719839697>)
- 21. Choi SW, Lee GW & Lee KB.** Arthroscopic microfracture for osteochondral lesions of the talus: functional outcomes at a mean of 6.7 years in 165 consecutive ankles. *American Journal of Sports Medicine* 2020 **48** 153–158 (<https://doi.org/10.1177/0363546519887957>)
- 22. Lambers KTA, Dahmen J, Altink JN, Reilingh ML, van Bergen CJA & Kerkhoffs GMMJ.** Bone marrow stimulation for talar osteochondral lesions at long-term follow-up shows a high sports participation though a decrease in clinical outcomes over time. *Knee Surgery, Sports Traumatology, Arthroscopy* 2021 **29** 1562–1569. (<https://doi.org/10.1007/s00167-020-06250-8>)
- 23. Lee YK, Young KW, Kim JS, Lee HS, Cho WJ & Kim HN.** Arthroscopic microfracture with atelocollagen augmentation for osteochondral lesion of the talus: a multicenter randomized controlled trial. *BMC Musculoskeletal Disorders* 2020 **21** 716. (<https://doi.org/10.1186/s12891-020-03730-3>)
- 24. Sadlik B, Kolodziej L, Blasiak A, Szymczak M & Warchal B.** Biological reconstruction of large osteochondral lesions of the talar dome with a modified ‘sandwich’ technique–midterm results. *Foot and Ankle Surgery* 2017 **23** 290–295. (<https://doi.org/10.1016/j.fas.2016.09.001>)
- 25. Shimozono Y, Hurley ET, Yasui Y, Deyer TW & Kennedy JG.** The presence and degree of bone marrow edema influence midterm clinical outcomes after microfracture for osteochondral lesions of the talus. *American Journal of Sports Medicine* 2018 **46** 2503–2508. (<https://doi.org/10.1177/0363546518782701>)
- 26. Akmeser R, Ertan MB & Kocaoglu H.** Comparison of chitosan-based liquid scaffold and hyaluronic acid-based soft scaffold for treatment of talus osteochondral lesions. *Foot and Ankle International* 2020 **41** 1240–1248. (<https://doi.org/10.1177/1071100720937662>)
- 27. Di Cave E, Versari P, Sciarretta F, Luzon D & Marcellini L.** Biphasic bioresorbable scaffold (TruFit Plug(R)) for the treatment of osteochondral lesions of talus: 6- to 8-year follow-up. *Foot* 2017 **33** 48–52. (<https://doi.org/10.1016/j.foot.2017.05.005>)
- 28. Wiewiorski M, Werner L, Paul J, Anderson AE, Barg A & Valderrabano V.** Sports activity after reconstruction of osteochondral lesions of the talus with autologous spongiosa grafts and autologous matrix-induced chondrogenesis. *American Journal of Sports Medicine* 2016 **44** 2651–2658. (<https://doi.org/10.1177/0363546516659643>)
- 29. D’Ambrosi R, Maccario C, Serra N, Liuni F & Uselli FG.** Osteochondral lesions of the talus and autologous matrix-induced chondrogenesis: is age a negative predictor outcome? *Arthroscopy: The Journal of Arthroscopic and Related Surgery* 2017 **33** 428–435. (<https://doi.org/10.1016/j.arthro.2016.09.030>)
- 30. Becher C, Malahias MA, Ali MM, Maffulli N & Thermann H.** Arthroscopic microfracture vs. arthroscopic autologous matrix-induced chondrogenesis for the treatment

of articular cartilage defects of the talus. *Knee Surgery, Sports Traumatology, Arthroscopy* 2019 **27** 2731–2736. (<https://doi.org/10.1007/s00167-018-5278-7>)

31. Galla M, Duensing I, Kahn TL & Barg A. Open reconstruction with autologous spongiosa grafts and matrix-induced chondrogenesis for osteochondral lesions of the talus can be performed without medial malleolar osteotomy. *Knee Surgery, Sports Traumatology, Arthroscopy* 2019 **27** 2789–2795. (<https://doi.org/10.1007/s00167-018-5063-7>)

32. Kanatli U, Eren A, Eren TK, Vural A, Geylan DE & Oner AY. Single-step arthroscopic repair with cell-free polymer-based scaffold in osteochondral lesions of the talus: clinical and radiological results. *Arthroscopy: The Journal of Arthroscopic and Related Surgery* 2017 **33** 1718–1726. (<https://doi.org/10.1016/j.arthro.2017.06.011>)

33. Baums MH, Heidrich G, Schultz W, Steckel H, Kahl E & Klinger HM. Autologous chondrocyte transplantation for treating cartilage defects of the talus. *Journal of Bone and Joint Surgery: American Volume* 2006 **88** 303–308. (<https://doi.org/10.2106/JBJS.E.00033>)

34. Giannini S, Buda R, Vannini F, Cavallo M & Grigolo B. One-step bone marrow-derived cell transplantation in talar osteochondral lesions. *Clinical Orthopaedics and Related Research* 2009 **467** 3307–3320. (<https://doi.org/10.1007/s11999-009-0885-8>)

35. Giannini S, Buda R, Cavallo M, Ruffilli A, Cenacchi A, Cavallo C & Vannini F. Cartilage repair evolution in post-traumatic osteochondral lesions of the talus: from open field autologous chondrocyte to bone-marrow-derived cells transplantation. *Injury* 2010 **41** 1196–1203. (<https://doi.org/10.1016/j.injury.2010.09.028>)

36. Lee DH, Lee KB, Jung ST, Seon JK, Kim MS & Sung IH. Comparison of early versus delayed weightbearing outcomes after microfracture for small to mid-sized osteochondral lesions of the talus. *American Journal of Sports Medicine* 2012 **40** 2023–2028. (<https://doi.org/10.1177/0363546512455316>)

37. Kwak SK, Kern BS, Ferkel RD, Chan KW, Kasraeian S & Applegate GR. Autologous chondrocyte implantation of the ankle: 2- to 10-year results. *American Journal of Sports Medicine* 2014 **42** 2156–2164. (<https://doi.org/10.1177/0363546514540587>)

38. Puddu L, Altamore F, Santandrea A, Mercurio D, Caggiari G, Della Sala S, Marinetti A, Tassarolo F, Rigoni M, Manunta AF, et al. Surgical treatment of talar osteochondral lesions with micro-fractures, mesenchymal cells grafting on membrane, or allograft: mid-term clinical and magnetic resonance assessment. *Journal of Orthopaedics* 2020 **21** 416–420. (<https://doi.org/10.1016/j.jor.2020.08.012>)

39. Raikin SM. Fresh osteochondral allografts for large-volume cystic osteochondral defects of the talus. *Journal of Bone and Joint Surgery: American Volume* 2009 **91** 2818–2826. (<https://doi.org/10.2106/JBJS.I.00398>)

40. Gortz S, De Young AJ & Bugbee WD. Fresh osteochondral allografting for osteochondral lesions of the talus. *Foot and Ankle International* 2010 **31** 283–290. (<https://doi.org/10.3113/FAI.2010.0283>)

41. Berlet GC, Hyer CF, Philbin TM, Hartman JF & Wright ML. Does fresh osteochondral allograft transplantation of talar osteochondral defects improve function? *Clinical Orthopaedics and Related Research* 2011 **469** 2356–2366. (<https://doi.org/10.1007/s11999-011-1813-2>)

42. Chu CH, Chen IH, Yang KC & Wang CC. Midterm results of fresh-frozen osteochondral allografting for osteochondral lesions of the talus. *Foot and Ankle International* 2021 **42** 8–16. (<https://doi.org/10.1177/1071100720949861>)

43. Giza E, Sullivan M, Ocel D, Lundeen G, Mitchell ME, Veris L & Walton J. Matrix-induced autologous chondrocyte implantation of talus articular defects. *Foot and Ankle International* 2010 **31** 747–753. (<https://doi.org/10.3113/FAI.2010.0747>)

44. Lenz CG, Tan S, Carey AL, Ang K & Schneider T. Matrix-induced autologous chondrocyte implantation (MACI) grafting for osteochondral lesions of the talus. *Foot and Ankle International* 2020 **41** 1099–1105. (<https://doi.org/10.1177/1071100720935110>)

45. Nehrer S, Domayer SE, Hirschfeld C, Stelzeneder D, Trattning S & Dorotka R. Matrix-associated and autologous chondrocyte transplantation in the ankle: clinical and MRI follow-up after 2 to 11 years. *Cartilage* 2011 **2** 81–91. (<https://doi.org/10.1177/1947603510381095>)

46. Hangody L, Kish G, Modis L, Szerb I, Gaspar L, Dioszegi Z & Kendik Z. Mosaicplasty for the treatment of osteochondritis dissecans of the talus: two to seven year results in 36 patients. *Foot and Ankle International* 2001 **22** 552–558. (<https://doi.org/10.1177/107110070102200704>)

47. Kreuz PC, Steinwachs M, Erggelet C, Lahm A, Henle P & Niemeyer P. Mosaicplasty with autogenous talar autograft for osteochondral lesions of the talus after failed primary arthroscopic management: a prospective study with a 4-year follow-up. *American Journal of Sports Medicine* 2006 **34** 55–63. (<https://doi.org/10.1177/0363546505278299>)

48. Gobbi A, Francisco RA, Lubowitz JH, Allegra F & Canata G. Osteochondral lesions of the talus: randomized controlled trial comparing chondroplasty, microfracture, and osteochondral autograft transplantation. *Arthroscopy: The Journal of Arthroscopic and Related Surgery* 2006 **22** 1085–1092. (<https://doi.org/10.1016/j.arthro.2006.05.016>)

49. Imhoff AB, Paul J, Ottinger B, Wortler K, Lammler L, Spang J & Hinterwimmer S. Osteochondral transplantation of the talus: long-term clinical and magnetic resonance imaging evaluation. *American Journal of Sports Medicine* 2011 **39** 1487–1493. (<https://doi.org/10.1177/0363546510397726>)

50. Georgiannos D, Bisbinas I & Badekas A. Osteochondral transplantation of autologous graft for the treatment of osteochondral lesions of talus: 5- to 7-year follow-up. *Knee Surgery, Sports Traumatology, Arthroscopy* 2016 **24** 3722–3729. (<https://doi.org/10.1007/s00167-014-3389-3>)

51. Gul M, Cetinkaya E, Aykut ÜS, Ozkul B, Saygili MS, Akman YE & Kabukcuoglu YS. Effect of the presence of subchondral cysts on treatment results of autologous osteochondral graft transfer in osteochondral lesions of the talus. *Journal of Foot and Ankle Surgery* 2016 **55** 1003–1006. (<https://doi.org/10.1053/j.jfas.2016.05.012>)

52. Park KH, Hwang Y, Han SH, Park YJ, Shim DW, Choi WJ & Lee JW. Primary versus secondary osteochondral autograft transplantation for the treatment of large osteochondral lesions of the talus. *American Journal of Sports Medicine* 2018 **46** 1389–1396. (<https://doi.org/10.1177/0363546518758014>)

53. Shimozono Y, Donders JCE, Yasui Y, Hurley ET, Deyer TW, Nguyen JT & Kennedy JG. Effect of the containment type on clinical outcomes in osteochondral lesions of the talus treated with autologous osteochondral transplantation. *American Journal of Sports Medicine* 2018 **46** 2096–2102. (<https://doi.org/10.1177/0363546518776659>)

54. Leumann A, Valderrabano V, Wiewiorski M, Barg A, Hintermann B & Pagenstert G. Bony periosteum-covered iliac crest plug transplantation for severe osteochondral lesions of the talus: a modified mosaicplasty procedure. *Knee Surgery, Sports Traumatology, Arthroscopy* 2014 **22** 1304–1310. (<https://doi.org/10.1007/s00167-013-2604-y>)

55. Hu Y, Guo Q, Jiao C, Mei Y, Jiang D, Wang J & Zheng Z. Treatment of large cystic medial osteochondral lesions of the talus with autologous osteoperiosteal cylinder grafts. *Arthroscopy: The Journal of Arthroscopic and Related Surgery* 2013 **29** 1372–1379. (<https://doi.org/10.1016/j.arthro.2013.05.014>)

56. Hintermann B, Wagener J, Knupp M, Schweizer C & Schaefer DJ. Treatment of extended osteochondral lesions of the talus with a free vascularised bone graft from the medial condyle of the femur. *Bone and Joint Journal* 2015 **97-B** 1242–1249. (<https://doi.org/10.1302/0301-620X.97B9.35292>)

57. Bai L, Guan S, Liu S, You T, Xie X, Chen P & Zhang W. Clinical outcomes of osteochondral lesions of the talus with large subchondral cysts treated with osteotomy and autologous chondral grafts: minimum 2-year follow-up and second-look evaluation. *Orthopaedic Journal of Sports Medicine* 2020 **8** 2325967120937798. (<https://doi.org/10.1177/2325967120937798>)

58. Ramponi L, Yasui Y, Murawski CD, Ferkel RD, DiGiovanni CW, Kerkhoffs GMMJ, Calder JDF, Takao M, Vannini F, Choi WJ, et al. Lesion size is a predictor of clinical outcomes after bone marrow stimulation for osteochondral lesions of the talus: a systematic review. *American Journal of Sports Medicine* 2017 **45** 1698–1705. (<https://doi.org/10.1177/0363546516668292>)

59. Choi WJ, Park KK, Kim BS & Lee JW. Osteochondral lesion of the talus: is there a critical defect size for poor outcome? *American Journal of Sports Medicine* 2009 **37** 1974–1980. (<https://doi.org/10.1177/0363546509335765>)