

Total joint replacement for osteoarthritis of the carpometacarpal joint of the thumb: why and how?

Joris Duerinckx¹ and Frederik Verstreken²

¹Ziekenhuis Oost-Limburg, Genk, Belgium

²Monica Hospital, Antwerp, Belgium

Correspondence
should be addressed
to J Duerinckx
Email
joris.duerinckx@zol.be

- Total joint replacement has certain advantages over other surgical treatment methods for osteoarthritis of the thumb carpometacarpal joint, including restoration of thumb length and alignment, good cosmetrical result, fast recovery of hand function and prevention of iatrogenic complications at neighbouring joints.
- Disadvantages include the technical difficulty to perform this surgery and a possible higher complication rate.
- A meticulous surgical technique is mandatory.
- Combined with a cementless and modular ball-in-socket implant with a metal-on-polyethylene friction couple, a 10-year survival rate higher than 90% can be expected.
- Revision surgery is possible with implant exchange or conversion to trapeziectomy.

Keywords

- ▶ thumb
- ▶ CMC
- ▶ total joint replacement

EFORT Open Reviews
(2022) 7, 349–355

Introduction

Osteoarthritis of the carpometacarpal joint of the thumb (CMC-1) is a common problem and surgical treatment is indicated when conservative measures fail to provide sufficient relief. Of the many surgical treatment options, no technique has yet been established as superior (Table 1). The latest Cochrane systematic review about ‘Surgery for thumb (trapeziometacarpal (TM) joint) osteoarthritis’ was withdrawn, due to the lack of good quality clinical studies to provide strong conclusive evidence (1). Trapeziectomy, often combined with some sort of ligament reconstruction and tendon interposition is globally most often recommended to patients. The goal of these popular resection arthroplasty procedures is to create a sufficiently stable and functional pseudarthrosis. One can argue that, as long as this is achieved, further surgical interventions such as the implantation of a prosthesis may be considered superfluous (2). However, the recovery time of resection arthroplasties is long and a significant number of patients remain dissatisfied. Knowing that total joint replacement is one of the most successful achievements of orthopedic surgery, many attempts have been made to produce a replacement for the thumb CMC joint that would provide a better outcome. Some of the newer generation implants have stood the test of time, and successful clinical results have been published, making them a valid treatment alternative (3). This has provoked a growing interest in these procedures, although joint replacement surgery is currently only preferred by 13% of European surgeons and

1.3% of North-American surgeons (4). In this paper, we will further focus on the rationale for total joint arthroplasty (TJA) and highlight important steps in the surgical technique to improve outcomes and avoid complications.

Rationale for total joint replacement

Advantages

Faster recovery

Following TJA, the thumb is not or only shortly immobilized, normal activities are encouraged as soon as possible and there is no need for physiotherapy (5). Several studies have shown that functional recovery after total joint replacement is significantly faster compared to trapeziectomy (6, 7). Registry data from Sweden demonstrate that sick leave was significantly shorter following implant arthroplasty; a mean of 94 days in men and 109 days in women (8). After trapeziectomy, most patients take a year to achieve a good outcome (9).

Restoration of thumb length, alignment and cosmesis

Degenerative disease of the CMC-1 joint often leads to dorsal subluxation of the base of the first metacarpal relative to the trapezium, adduction contracture and shortening of the thumb column. This causes a flexion-adduction posture of the CMC-1 joint and leads to secondary hyperextension of the metacarpophalangeal joint and a Z-deformity of the thumb. This is present in more than two-third of advanced cases of thumb CMC osteoarthritis (10). Surgery

Table 1 Advantages and disadvantages of different surgical treatment options for degenerative trapeziometacarpal joint disease.

	Pros	Cons
Osteotomy	Joint preserving Does not compromise further procedures	Limited indications
Arthrodesis	Good pain relief Allows heavy loading	Long immobilization Impact on motion and function High non-union rate May develop STT or MCP osteoarthritis
Total joint arthroplasty	Good pain relief Early return to function Restoration of thumb length Correction of MCP hyperextension	Technically demanding High complication rate More expensive
Trapeziectomy	Straightforward procedure Long term results available	Longer recovery time Shortening May develop midcarpal instability Remaining symptoms

for the arthritic basal joint of the thumb is less likely to be successful when this Z-collapse is not addressed (11, 12). Realignment of the thumb metacarpal with the trapezium and thumb length is better corrected after CMC-1 total joint replacement than after trapeziectomy (6, 13). The trapezium has a mean height of 15.2 mm (14). Resection of the trapezium causes subsidence of the thumb metacarpal into the resection space and is associated with further shortening of the thumb (15). Ligament reconstruction and interposition procedures do not prevent this (6, 13). Thumb length can only be restored with preservation of the trapezium and insertion of an implant. As a result, additional surgery to correct MCP hyperextension deformity can often be avoided by TJA (16). This also results in a better cosmetic outcome. At 6 months after surgery, patient satisfaction with the clinical appearance of the thumb is significantly better after thumb CMC total joint replacement compared to trapeziectomy and interposition arthroplasty (6). This can probably be contributed to the correction of thumb length, metacarpal base subluxation and MCP hyperextension.

Prevention of midcarpal wrist instability

Although there is no consensus on the impact of resection of the trapezium on carpal stability (17, 18), recent publications concluded that trapeziectomy can lead to a loss of carpal height with extension of both the lunate and scaphoid and a non-dissociative pattern of dorsal intercalated segment instability (DISI) (19, 20). This explains why patients with preoperative DISI deformity of the carpus have a significantly higher chance to be dissatisfied after trapeziectomy than patients without preoperative DISI (21). By replacing the thumb CMC joint with an implant and preserving the trapezium, the stability of the carpus is not placed at risk.

Prevention of further degeneration of the STT joint

Removal of the trapezium can lead to progressive arthrosis in the remaining articulation between the scaphoid and the trapezoid (19, 20, 21).

No need to harvest a donor tendon

Most surgeons prefer to combine trapeziectomy with a soft tissue procedure to stabilize the base of the thumb (4). This is performed with a tendon that is harvested from the forearm. It is demonstrated that tendon harvesting increases the number of complications. In procedures that use the flexor carpi radialis, a sensation of pulling in the forearm with wrist motion is present in almost half of patients at 3 months (22). Harvest of the entire flexor carpi radialis tendon also decreases wrist flexion strength and fatigue resistance (23).

Higher patient satisfaction

Although long-term pain relief and acceptable restoration of thumb function can be expected in 85% of trapeziectomy patients (22), it often takes a long recovery time and only 76% of patients would opt to have this treatment again under similar conditions. This indicates that a significant number of patients are not really satisfied following resection arthroplasty. By contrast, 89% of patients that had thumb CMC total joint replacement with an ARPE prosthesis would recommend this (24).

Total joint replacement preserves the option for secondary trapeziectomy

In case of a failed thumb CMC prosthesis, revision with a new implant and preservation of the trapezium is possible in selected cases. If this cannot be achieved, salvage surgery consists of removing the trapezium and conversion to a resection arthroplasty. Postoperative results have been reported to be similar to those following primary trapeziectomy (25, 26).

Disadvantages

Technically demanding procedure

Replacement of the CMC-1 joint is a technically demanding procedure with a learning curve and little room for error. Appropriate training is essential before embarking on this procedure. Patient selection, precise preparation of the

procedure and positioning of the components is essential to avoid complications (3). The learning curve of thumb CMC total joint replacement is estimated to be 30 cases. Dumartinet-Gibaud *et al.* observed that the number of complications and revisions due to technical errors was high in their initial series, but decreased markedly after this period (27). The excellent clinical results that have been published (5, 28, 29) were all achieved by surgeons with at least level III experience according to Tang and Giddins (30).

Higher complication rate

Compared to resection arthroplasty, the complication rate of TJA is higher. Most complications are the consequence of poor planning or poor surgical technique and can be avoided.

Insufficient height of the trapezium or poor bone quality can lead to fixation problems and early loosening of the cup implant. Fracture of the trapezium is a possible intraoperative complication and is most often caused by malpositioning of the cup. This can be the consequence of insufficient exposure to the trapezium, which is to be avoided. When good access to the trapezium is not obtained, further capsular and muscular release around the first metacarpal base is necessary. Fluoroscopy is mandatory to confirm the central positioning of the cup, and avoid eccentric placement, as this may lead to a fracture of the trapezium when inserting the press-fit cup. Eccentric cup placement can also jeopardize peripheral bone coverage and lead to early loosening of the cup.

The most common early complication following CMC-1 arthroplasty is dislocation, which is attributed to technical errors when it occurs in the early postoperative period. The main reasons are incomplete resection of osteophytes and poor positioning and orientation of the cup. The advent of dual mobility implants with an inherent bigger head size has significantly increased stability and decreased the

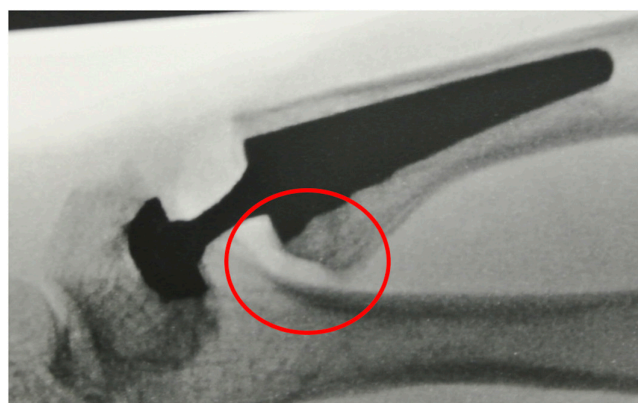


Figure 1
Resection of the volar beak at the base of the thumb metacarpal.

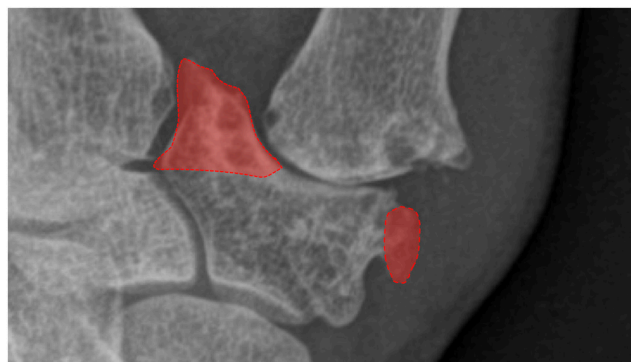

Figure 2
Removal of the medial and lateral osteophytes at the distal articular surface of the trapezium.

risk of early dislocations (31). Late dislocations are usually caused by advanced polyethylene wear or trauma and can be treated by revision of the cup or conversion to a trapeziectomy.

Although restoration of the length of the first ray is a major benefit of TJA replacement and is essential to obtain a well-aligned and stable situation, overlengthening needs to be avoided. Overlengthening may cause restricted motion, tendon imbalance and persistent pain. It is therefore helpful to compare the length of the thumb, relative to the second ray, before and after implantation of the components.

Increased cost

The need for implants significantly increases the cost of TJA, which is one of the main reasons why insurance companies are reluctant to provide coverage for this procedure, despite the increasing evidence of its advantages.

Outcome

New generation implants with cementless fixation of both components and a single centre of rotation in the trapezium show reassuring durability. Reported survival rate after 10 years is 95% for the Ivory prosthesis (5) and 93% for the ARPE prosthesis (29). These results come close to the 10-year survival rate of 97% for uncemented primary total hip arthroplasty, the standard reference in orthopedic total joint replacement surgery (32). They even reach the UK benchmark for hip implants set by the National Institute of Health and Care Excellence in 2014, which stated that ‘individual hip replacement components are only recommended if 5% or fewer need revision at 10 years’ (33). Long follow-up studies have shown that implant survival decreases steadily after 10 years. At 15 years follow-up, the cumulated survival rate of the ARPE prosthesis was 85% (27).

Surgical technique

A standardized and meticulous surgical technique is essential to achieve a good outcome. The surgical goal of thumb CMC TJA is double. First, the implant components should be well-positioned and solidly fixed to allow bony ingrowth, providing long-term stability. Secondly, complete range of motion without mechanical impingement or dislocation needs to be possible.

Approach

The thumb CMC joint can be approached through a dorsal or a lateral (also known as Moberg-Gedda or Wagner) incision. The choice between both depends on the preference of the surgeon as neither is superior. Both approaches have been described in detail by Tchurukdichian and Lussiez (34).

Stem placement in the thumb metacarpal

The articular surface at the base of the thumb metacarpal is resected. Care is taken to remove the volar beak because often osteophytes are present that can cause impingement and instability when the thumb is flexed or opposed (Fig. 1). Removal of the volar beak also facilitates later exposure of the trapezium and frees loose bodies that are often trapped in the region of the palmar recess of the joint. Next, the metacarpal medullary canal is prepared with broaches of increasing size, until a press fit with rotational stability is achieved. Aligning the axis of the stem with the anatomical axis of the thumb metacarpal is relatively straightforward as stems are sufficiently long. Cortical contact is not essential to prevent subsidence of the stem. The size of the final implant will therefore be more dependent on bone quality than on the size of the intramedullary canal. At this point, a trial stem of the appropriate size is inserted, flush with the metacarpal base. The intramedullary canal is broached. Insertion of the stem without cortical contact has several advantages. First, it lowers the risk of metacarpal fracture during stem insertion. Secondly, a finite element analysis demonstrated that placing metacarpal stems with cortical contact predisposes to stress shielding with bone loss in the proximal part of the metacarpal (35). When the stem is not placed in cortical contact at the isthmus, bone loading will probably be more uniform and more proximal in the metacarpal. Additionally, eventual stem removal is easier when there is some space between the stem and the cortex to allow the advancement of pins or osteotomes. This would lessen the need for metacarpal osteotomy to remove well-ingrown stems. A prospective radiographic study where only 23% of stems had cortical contact demonstrated stable radiographic results at 1 year postoperatively (36). This suggests that properly impacted cancellous bone forms a dense layer of bone that is able

to resist subsidence of a cementless hydroxyapatite-coated anatomical stem in the thumb metacarpal. Longer-term follow-up studies are needed to evaluate if these results are maintained over time.

Cup placement in the trapezium

Several factors make the correct placement of the cup in the trapezium a challenge. The trapezium is deformed by degenerative joint disease and can have an aberrant tilt of its articular surface in case of dysplasia. There is also a lack of visible biomechanical reference points and the design of the available cups does not replicate the anatomy of the trapezium.

Osteophytes need to be removed. The medial horn of the distal articular surface is often enlarged by osteophytes which can cause mechanical impingement with thumb adduction. Removal of osteophytes on the lateral side of the trapezium improves the aesthetical appearance of the hand (Fig. 2). The central hard subchondral bone of the distal articular surface of the trapezium should be preserved because it improves the mechanical fixation of a cementless cup (37).

Mechanical impingement between the cup and neck can provoke dislocation of a ball-in-socket articulation. Hence, the cup needs to be well centred in the trapezium and correctly aligned with the centre of motion of the CMC-1 joint. A biomechanical study demonstrated that radiographic placement of the cup parallel to the proximal articular surface of the trapezium (PAST) lowers the chance of dislocation (38). The PAST is a line that can be well delineated on radiographs (Fig. 3). The radiographic views of the base of the thumb as described by Kapandji are considered the gold standard to visualize the base of the thumb. We recommend the use of fluoroscopy during thumb CMC total joint replacement surgery. Not only does it allow evaluation of the extent of bony debridement it also helps to confirm correct cup placement. In a clinical series where cup implantation was guided with fluoroscopy, there were no cups with more than 14° oblique inclination relative to the PAST (39). As most implants allow more than the physiological range of motion, this accuracy can be considered adequate.

Fluoroscopic guided cup placement with a mini C-arm results in a mean effective radiation dose of 0.23 μ Sv. This is comparable with 1 h of natural background radiation, so the risk of radiation-induced stochastic (primarily cancer induction) and deterministic side effects (primarily skin injury) is negligible (39).

Soft tissue management

Management of the periarticular capsule and ligamentous soft tissues partly depends on the surgical approach. One principle is universal: a ball-in-socket joint replacement

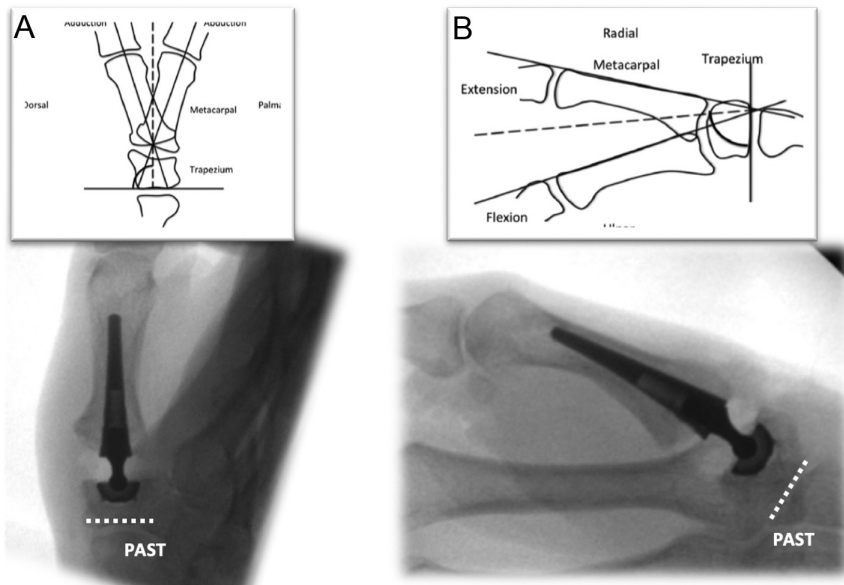


Figure 3
Placement of the cup in the trapezium parallel with the proximal articular surface of the trapezium aligns it with the centre of motion with the normal thumb carpometacarpal joint.

simplifies the complex biomechanics of the thumb CMC joint with its double centre of rotation to a single centre of rotation in the trapezium. For this reason, several authors recommend circumferential release of the joint capsule to prevent ligament tethering, decreased range of motion and dislocation (5, 40).

In a biomechanical cadaver study, complete capsuloligamentous release of the thumb CMC joint increases the risk of dislocation with longitudinal traction on the thumb (41), and this was confirmed in a clinical series (40). Capsular release also increases the motion of the CMC-1 joint, but not beyond the limits of most implant designs (42). To increase stability, one can have the tendency to lengthen the thumb during CMC TJA (43). The length of the thumb CMC joint can be assessed by comparing the length of the thumb, relative to the second ray, before and after implantation of the components. It can also be assessed radiographically by evaluating the congruency of the first metacarpal arch on anteroposterior views with the thumb in 45° abduction (44).

Correction of MCP1 hyperextension

TJA allows the restoration of the length of the thumb, restores tendon balance, stabilizes the thumb base and

increases thumb abduction. As a result, the position of the MCP1 joint is automatically corrected in most cases (13, 16, 45). In cases where MCP hyperextension is below 30°, TJA will restore the alignment. If the MCP hyperextension is above 30°, and insufficient correction occurs after TJA, we advise a palmar capsulodesis (Fig. 4) or an arthrodesis of the radial sesamoid under the head of the thumb metacarpal (12). In static deformities of the MCP joint, with less than 20° of passive MCP flexion, MCP arthrodesis is the preferred procedure.

Postoperative care

A bulky soft dressing is applied at the end of surgery to stabilize the base of the thumb. Enough padding should be provided to open the webspace between the thumb and index finger. Two weeks postoperatively, the dressing and skin sutures are removed and the patient is allowed to actively move the thumb. A removable thumb spica is applied and should be worn at night and during activity. Strenuous pinching should be avoided until 6 weeks after surgery to allow bony fixation of the prosthesis. After clinical and radiographic evaluation at 6 weeks after surgery, the patient has no further restrictions.

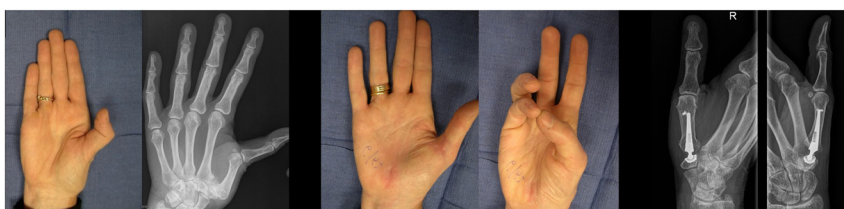


Figure 4
Correction of Z-deformity of the thumb by thumb carpometacarpal total joint replacement combined with volar capsulodesis of the MCP joint.

Conclusion

Total joint replacement has certain advantages over other surgical treatment methods for osteoarthritis of the thumb CMC joint, including restoration of thumb length and alignment, fast recovery of hand function and prevention of iatrogenic complications at neighbouring joints. Disadvantages include the technical difficulty to perform this surgery and a possible higher complication rate. A meticulous surgical technique is therefore mandatory. Combined with a cementless and modular ball-in-socket implant with a metal-on-polyethylene friction couple, a 10-year survival rate higher than 90% can be expected.

ICMJE Conflict of Interest Statement

The authors declare that there is no conflict of interest that could be perceived as prejudicing the impartiality of the work reported here.

Funding Statement

The work reported here did not receive any specific grant from any funding agency in the public, commercial or not-for-profit sector.

References

1. Wajon A, Vinycomb T, Carr E, Edmunds I & Ada L. WITHDRAWN: surgery for thumb (trapeziometacarpal joint) osteoarthritis. *Cochrane Database of Systematic Reviews* 2017 **4** CD004631. (<https://doi.org/10.1002/14651858.CD004631.pub5>)
2. Hentz VR. Surgical treatment of trapeziometacarpal joint arthritis: a historical perspective. *Clinical Orthopaedics and Related Research* 2014 **472** 1184–1189. (<https://doi.org/10.1007/s11999-013-3374-z>)
3. Borgers A, Verstreken A, Vanhees M & Verstreken F. Primary endoprosthesis replacement of the arthritic CMC-1 joint. *Operative Orthopädie und Traumatologie* 2021 **33** 228–244. (<https://doi.org/10.1007/s00064-021-00713-y>)
4. Ottenhoff JSE, Teunis T, Janssen SJ, Mink van der Molen AB & Ring D. Variation in offer of operative treatment to patients with trapeziometacarpal osteoarthritis. *Journal of Hand Surgery* 2020 **45** 123.e1–130.e1. (<https://doi.org/10.1016/j.jhsa.2019.10.017>)
5. Tchurukdichian A, Guillier D, Moris V, See LA & Macheboeuf Y. Results of 110 IVORY prostheses for trapeziometacarpal osteoarthritis with a minimum follow-up of 10 years. *Journal of Hand Surgery, European Volume* 2020 **45** 458–464. (<https://doi.org/10.1177/1753193419899843>)
6. Jager T, Barbary S, Dap F & Dautel G. Evaluation of postoperative pain and early functional results in the treatment of carpometacarpal joint arthritis. Comparative prospective study of trapeziectomy vs. MAIA® prosthesis in 74 female patients. *Chirurgie de la Main* 2013 **32** 55–62. (<https://doi.org/10.1016/j.main.2013.02.004>)
7. Ulrich-Vinther M, Puggaard H & Lange B. Prospective 1-year follow-up study comparing joint prosthesis with tendon interposition arthroplasty in treatment of trapeziometacarpal osteoarthritis. *Journal of Hand Surgery* 2008 **33** 1369–1377. (<https://doi.org/10.1016/j.jhsa.2008.04.028>)
8. Wolf JM, Atroschi I, Zhou C, Karlsson J & Englund M. Sick leave After surgery for thumb carpometacarpal osteoarthritis: a population-based study. *Journal of Hand Surgery* 2018 **43** 439–447. (<https://doi.org/10.1016/j.jhsa.2017.11.019>)
9. Vadstrup LS, Schou L & Boeckstyns ME. Basal joint osteoarthritis of the thumb treated with Weilby arthroplasty: a prospective study on the early postoperative course of 106 consecutive cases. *Journal of Hand Surgery, European Volume* 2009 **34** 503–505. (<https://doi.org/10.1177/1753193409105084>)
10. Armbruster EJ & Tan V. Carpometacarpal joint disease: addressing the metacarpophalangeal joint deformity. *Hand Clinics* 2008 **24** 295–299, vii. (<https://doi.org/10.1016/j.hcl.2008.03.013>)
11. Bricout M & Rezzouk J. Complications and failures of the trapeziometacarpal Maia® prosthesis: a series of 156 cases. *Hand Surgery and Rehabilitation* 2016 **35** 190–198. (<https://doi.org/10.1016/j.hansur.2016.02.005>)
12. Tonkin MA, Beard AJ, Kemp SJ & Eakins DF. Sesamoid arthrodesis for hyperextension of the thumb metacarpophalangeal joint. *Journal of Hand Surgery* 1995 **20** 334–338. ([https://doi.org/10.1016/S0363-5023\(05\)80036-X](https://doi.org/10.1016/S0363-5023(05)80036-X))
13. Robles-Molina MJ, López-Caba F, Gómez-Sánchez RC, Cárdenas-Grande E, Pajares-López M & Hernández-Cortés P. Trapeziectomy with ligament reconstruction and tendon Interposition versus a trapeziometacarpal prosthesis for the treatment of thumb basal joint osteoarthritis. *Orthopedics* 2017 **40** e681–e686. (<https://doi.org/10.3928/01477447-20170503-03>)
14. Loisel F, Chapuy S, Rey PB, Obert L, Parratte B, Tatu L & Lepage D. Dimensions of the trapezium bone: a cadaver and CT study. *Surgical and Radiologic Anatomy* 2015 **37** 787–792. (<https://doi.org/10.1007/s00276-015-1418-7>)
15. Downing ND & Davis TR. Trapezial space height after trapeziectomy: mechanism of formation and benefits. *Journal of Hand Surgery* 2001 **26** 862–868. (<https://doi.org/10.1053/jhsu.2001.27761>)
16. Degeorge B, Dagneaux L, Andrin J, Lazerges C, Coulet B & Chammas M. Do trapeziometacarpal prosthesis provide better metacarpophalangeal stability than trapeziectomy and ligamentoplasty? *Orthopaedics and Traumatology, Surgery and Research* 2018 **104** 1095–1100. (<https://doi.org/10.1016/j.otsr.2018.07.008>)
17. Drewniany JJ, Palmer AK & Flatt AE. The scaphotrapezial ligament complex: an anatomic and biomechanical study. *Journal of Hand Surgery* 1985 **10** 492–498. ([https://doi.org/10.1016/s0363-5023\(85\)80070-8](https://doi.org/10.1016/s0363-5023(85)80070-8))
18. Herren DB, Lehmann O & Simmen BR. Does trapeziectomy destabilize the carpus? *Journal of Hand Surgery* 1998 **23** 676–679. ([https://doi.org/10.1016/s0266-7681\(98\)80027-2](https://doi.org/10.1016/s0266-7681(98)80027-2))
19. Rectenwald JP, Green DP & Dobyns JH. Symptomatic carpal collapse after trapeziectomy and partial trapeziectomy: report of two cases. *Journal of Hand Surgery* 2005 **30** 706–710. (<https://doi.org/10.1016/j.jhsa.2005.01.017>)
20. Paul AW, Athens CM, Patel R, Rizzo M & Rhee PC. Effect of Trapeziectomy on carpal stability. *Hand* 2020 In press. (<https://doi.org/10.1177/1558944720939198>)
21. Yuan BJ, Moran SL, Tay SC & Berger RA. Trapeziectomy and carpal collapse. *Journal of Hand Surgery* 2009 **34** 219–227. (<https://doi.org/10.1016/j.jhsa.2008.11.007>)
22. Salem H & Davis TR. Six year outcome excision of the trapezium for trapeziometacarpal joint osteoarthritis: is it improved by ligament reconstruction and temporary Kirschner wire insertion? *Journal of Hand Surgery, European Volume* 2012 **37** 211–219. (<https://doi.org/10.1177/1753193411414516>)
23. Naidu SH, Poole J & Horne A. Entire flexor carpi radialis tendon harvest for thumb carpometacarpal arthroplasty alters wrist kinetics. *Journal of Hand Surgery* 2006 **31** 1171–1175. (<https://doi.org/10.1016/j.jhsa.2006.05.005>)
24. Craik JD, Glasgow S, Andren J, Sims M, Mansouri R, Sharma R & Ellahee N. Early results of the ARPE arthroplasty versus trapeziectomy for the treatment of thumb

- carpometacarpal joint osteoarthritis. *Journal of Hand Surgery Asian-Pacific Volume* 2017 **22** 472–478. (<https://doi.org/10.1142/S0218810417500526>)
- 25. Lenoir H, Erbland A, Lumens D, Coulet B & Chammas M.** Trapeziectomy and ligament reconstruction tendon interposition after failed trapeziometacarpal joint replacement. *Hand Surgery and Rehabilitation* 2016 **35** 21–26. (<https://doi.org/10.1016/j.hansur.2015.09.002>)
- 26. Kaszap B, Daecke W & Jung M.** Outcome comparison of primary trapeziectomy versus secondary trapeziectomy following failed total trapeziometacarpal joint replacement. *Journal of Hand Surgery* 2013 **38** 863–871.e3. (<https://doi.org/10.1016/j.jhsa.2013.01.030>)
- 27. Dumartinet-Gibaud R, Bigorre N, Raimbeau G, Jeudy J & Saint Cast Y.** Arpe total joint arthroplasty for trapeziometacarpal osteoarthritis: 80 thumbs in 63 patients with a minimum of 10 years follow-up. *Journal of Hand Surgery, European Volume* 2020 **45** 465–469. (<https://doi.org/10.1177/1753193420909198>)
- 28. Vissers G, Goorens CK, Vanmierlo B, Bonte F, Mermuys K, Fils JF & Goubau JF.** Ivory arthroplasty for trapeziometacarpal osteoarthritis: 10-year follow-up. *Journal of Hand Surgery, European Volume* 2019 **44** 138–145. (<https://doi.org/10.1177/1753193418797890>)
- 29. Martin-Ferrero M, Simón-Pérez C, Coco-Martín MB, Vega-Castrillo A, Aguado-Hernández H & Mayo-Iscar A.** Trapeziometacarpal total joint arthroplasty for osteoarthritis: 199 patients with a minimum of 10 years follow-up. *Journal of Hand Surgery, European Volume* 2020 **45** 443–451. (<https://doi.org/10.1177/1753193419871660>)
- 30. Tang JB & Giddins G.** Why and how to report surgeons' levels of expertise. *Journal of Hand Surgery, European Volume* 2016 **41** 365–366. (<https://doi.org/10.1177/1753193416641590>)
- 31. Tchurukdichian A, Gerenton B, Moris V, See LA, Stivala A & Guillier D.** Outcomes of double-mobility prosthesis in trapeziometacarpal joint arthritis with a minimal 3 years of follow-up: an advantage for implant stability. *Hand* 2021 **16** 368–374. (<https://doi.org/10.1177/1558944719855690>)
- 32. Chaudhry H, MacDonald SJ, Howard JL, McCalden RW, Naudie DD & Vasarhelyi EM.** Clinical outcomes and midterm survivorship of an uncemented primary total hip arthroplasty system. *Journal of Arthroplasty* 2020 **35** 1662–1666. (<https://doi.org/10.1016/j.arth.2020.01.063>)
- 33.** National Institute of Health and Care Excellence. (available at: www.nice.org.uk/guidance/ta304). Accessed on 10 October 2020.
- 34. Tchurukdichian A & Lussiez B.** Surgical approaches to the trapeziometacarpal joint for the insertion of implants and prostheses (non-arthroscopy). *Hand Surgery and Rehabilitation* 2021 **40S** S29–S32. (<https://doi.org/10.1016/j.hansur.2020.10.019>)
- 35. Ledoux P.** Modelising of the behavior of a metallic implant in the first metacarpal. *Chirurgie de la Main* 2011 **30** S145–S147.
- 36. Perelli S, Caekebeke P & Duerinckx J.** Cortical contact is unnecessary to prevent stem subsidence in cementless trapeziometacarpal arthroplasty. *Journal of Hand Surgery, European Volume* 2018 **43** 98–99.
- 37. Thillemann JK, Dremstrup L, Hansen TB & Stilling M.** The mechanical fixation of a cementless conical cup in cortical versus cancellous trapezium bone: an experimental study. *Journal of Hand Surgery, European Volume* 2021 **46** 146–153. (<https://doi.org/10.1177/1753193420963255>)
- 38. Brauns A, Caekebeke P & Duerinckx J.** The effect of cup orientation on stability of trapeziometacarpal total joint arthroplasty: a biomechanical cadaver study. *Journal of Hand Surgery, European Volume* 2019 **44** 708–713. (<https://doi.org/10.1177/1753193419851775>)
- 39. Dirckx G, Caekebeke P & Duerinckx J.** Fluoroscopy-guided cup placement in total trapeziometacarpal joint arthroplasty. *Hand Surgery and Rehabilitation* 2021 **40** 205–206. (<https://doi.org/10.1016/j.hansur.2020.10.013>)
- 40. Andrzejewski A & Ledoux P.** Maïa trapeziometacarpal joint arthroplasty: survival and clinical outcomes at 5 years' follow-up. *Hand Surgery and Rehabilitation* 2019 **38** 169–173. (<https://doi.org/10.1016/j.hansur.2019.03.004>)
- 41. Van Hove B, Degreef I & Duerinckx J.** The effect of capsular release on stability in trapeziometacarpal total joint arthroplasty. *Journal of Hand Surgery, European Volume* 2020 **45** 872–874. (<https://doi.org/10.1177/1753193420922756>)
- 42. Van Hove B, Vantilt J, Bruijnes A, Caekebeke P, Corten K, Degreef I & Duerinckx J.** Trapeziometacarpal total joint arthroplasty: the effect of capsular release on range of motion. *Hand Surgery and Rehabilitation* 2020 **39** 413–416. (<https://doi.org/10.1016/j.hansur.2020.04.008>)
- 43. Goubau JF, Goubau L, Goorens CK, van Hoonacker P, Kerckhove D, Vanmierlo B & Berghs B.** De Quervain tenosynovitis following trapeziometacarpal ball-and-socket joint replacement. *Journal of Wrist Surgery* 2015 **4** 35–42. (<https://doi.org/10.1055/s-0034-1398487>)
- 44. Duché R & Trabelsi A.** The concept of first metacarpal M1-M2 arch. New interest in trapeziometacarpal prostheses. *Hand Surgery and Rehabilitation* 2022 In press. (<https://doi.org/10.1016/j.hansur.2021.12.011>)
- 45. Lussiez B, Falaise C & Ledoux P.** Dual mobility trapeziometacarpal prosthesis: a prospective study of 107 cases with a follow-up of more than 3 years. *Journal of Hand Surgery, European Volume* 2021 **46** 961–967. (<https://doi.org/10.1177/17531934211024500>)