

# Osteochondral lesion of the talus: still a problem?

Fabian Krause and Helen Anwander<sup>id</sup>

Department of Orthopaedic Surgery and Traumatology, Inselspital, Bern University Hospital, University of Bern, Bern, Switzerland

Correspondence should be addressed to H Anwander  
**Email**  
[helen.anwander@insel.ch](mailto:helen.anwander@insel.ch)

- Osteochondral lesion of the talus (OLT) often occurs after ankle trauma or repetitive micro-traumata, whereas the actual etiology remains unclear. The most common symptoms are local pain deep in the medial or lateral ankle that increases with weight-bearing and activity, accompanied by tenderness and swelling.
- Eventually, most patients with symptomatic or unstable OLT require surgery. Many reasonable operative techniques have been described, whereas most lead to similar and satisfactory results. They can be divided into cartilage repair, cartilage regeneration and cartilage replacement techniques. The OLT size and morphology in the first place but also surgeon and individual patient aspects are considered when it comes to surgery.
- For high postoperative success and low recurrence rates, underlying causes, for example, ligamentous instability and hindfoot malalignment should also be addressed during surgery.

## Keywords

- ▶ osteochondral lesion
- ▶ talus
- ▶ chondroplasty
- ▶ bone marrow stimulation
- ▶ cartilage transplantation

EFORT Open Reviews  
(2022) 7, 337–343

## Introduction

Over 60% of the talus is covered with cartilage. Osteochondral lesion of the talus (OLT) describes damage to the talar cartilage including pathological changes in the underlying bone. In 1870, Paget (1) first described loose bodies in joints. In 1888, König (2) described osteochondritis dissecans in several joints, including the ankle joint.

## Aetiology

In nearly 80% of patients with OLT a history of ankle trauma can be found (3, 4). Thirty-eight percent of patients with OLT present ankle ligament laxity and 39% of patients with ankle instability present with an OLT (5, 6). Subsequently, acute trauma and repetitive micro-traumata due to ankle instability and/or hindfoot malalignment seem to be a leading cause of OLT. A traumatic insult can cause damage to the cartilage and lead to microfractures. In an ankle with chondral damage, the synovial fluid penetrates these microfractures. Loading leads to high fluid pressure that in turn induces osteonecrosis and later on cyst formations (7). The poor vascularization of the talus leads to a higher risk of osteonecrosis and decreased healing capacity. Particularly, in the presence of ankle instability and hindfoot malalignment, the increased load on the cartilage can lead to cellular degeneration or death by the disruption of collagen fibril ultrastructure (8). Further theories about the aetiology of OLT include vascular,

endocrine or metabolic causes (9). It is suspected that the cartilage damage itself does not lead to pain but the osteonecrosis of the highly innervated subchondral bone underneath the cartilage defect (7).

## Symptoms and diagnostic

OLT is a predominantly male disease, mostly affecting patients in their thirties. Patients typically present 6–12 months after an initial trauma (ankle fracture or sprain); typical symptoms are local pain, tenderness and swelling deep in the medial or lateral ankle that increases with weight-bearing and activity. Occasionally, patients report locking or catching of the ankle. Often, recurrent sprains and unbalanced loading of the entire foot go along with the ankle problem.

A thorough clinical examination of the patient focussing on the location of tenderness and swelling of the ankle, limitations of ankle, subtalar, and talonavicular range of motion, ligamentous ankle stability, and hindfoot alignment should be performed.

Standard imaging includes weight-bearing anteroposterior (AP) and lateral radiographs of the ankle. For the radiological assessment of the hindfoot alignment, many surgeons advocate the Saltzman hindfoot alignment view; others are content with the detailed clinical examination of the hindfoot and AP radiograph of the ankle. In the majority of cases, an additional MRI to evaluate the OLT activity and accompanying injuries of ligaments and tendons completes the imaging. A CT allows

a better resolution of bony pathologies, for example, the size of subchondral cysts, but less information on articular cartilage wear, OLT activity and soft tissues. SPECT CT enables information received from both MRI and CT and has therefore gained popularity within the last decade. However, the radiation the patient is exposed to by having a SPECT CT should not be neglected.

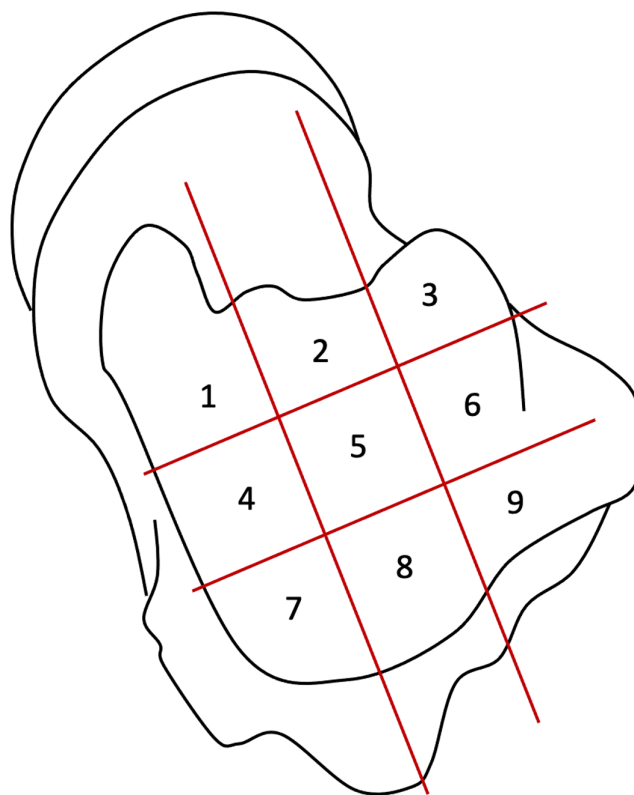
Ankle arthroscopy is a very effective method for the diagnostic of ankle OLTs and other intraarticular pathologies. The direct visualization of the entire joint in addition to examining the lesion by the probe and testing the ligamentous stability provides the most comprehensive evaluation in deciding the appropriate treatment of every single pathology.

The most frequently used classification on plain radiographs was introduced by Bernt & Hardy in 1959 (10). Stage 1 describes a trabecular compression of subchondral bone. Partial detachment of osteochondral fragment defines stage 2, complete detachment without displacement stage 3 and a displaced fragment finally outlines stage 4. Ferkel *et al.* (11) adapted the classification to the CT. Hepple *et al.* adapted the classification on the MRI (12). In the classification of Hepple, in stage 1, no alteration is seen on x-ray, but damage to the cartilage on MRI. Stage 2 includes subchondral fracture without detachment of the cartilage. Stages 3 and 4 are analogue to the stages described by Bernt and Hardy undisplaced and displaced fragments. Raikin *et al.* (13) established a nine-zone anatomical grid system on the talar dome to locate osteochondral lesions (Fig. 1).

The centromedial zone is the most commonly involved (31–42%) (4, 5). Medial lesions tend to be bigger and deeper, lateral lesions tend to be smaller but more often associated with a ligament laxity (5). No correlation has been found between location of the OLT and extent of preoperative pain, functional scores and stage of injury (5).

### Therapy of osteochondral lesion of the talus

Lesions that are diagnosed incidentally and symptomatic patients with non-displaced cartilage lesions can be treated non-operatively. Conservative treatment includes restriction of physical activity, partial weight-bearing and in case of a hindfoot varus or valgus, corrective orthopedic insoles. Seo *et al.* report a good outcome 6 years after conservative treatment (without restriction of activity) of OLT with a decrease of VAS pain score from 3.8 to 0.9 and no progression of osteoarthritis (14). Injective treatments have been introduced. Infiltration of hyaluronic acid, platelet-rich plasma, bone marrow aspirate concentrate (BMAC), and prolotherapy in the ankle joint all have led to decreased pain and increased function 6–12 months after infiltration (15, 16). No adverse events were reported,



**Figure 1** Nine-zone anatomical grid system according to Raikin.

indicating infiltrations are safe. However, long-term efficacy higher than placebo has yet to be proven (17).

We generally recommend initial conservative treatment in symptomatic but undisplaced OLT for at least 3 months before surgery is taken into consideration. Non-operative treatment is effective in roughly 50% of these cases (18). However, the level of patient’s activity, ligamentous ankle stability and hindfoot alignment may influence the timing of surgery. The issue of lost time in professional but also in recreational athletes and the unlikely healing of ankle OLT in unstable ankles or malaligned hindfeet may guide the surgeon to recommend early surgery. Numerous operative techniques have been described in the literature; however, consensus particularly for bigger lesions has yet to be found.

We recommend an ankle arthroscopy at the beginning of the operative treatment for inspection of the entire joint including direct visualization of the OLT and testing of the ligamentous stability.

Operative treatment strategies can be divided into cartilage repair, cartilage regeneration and cartilage replacement. These therapies are discussed in detail below.

#### Direct fixation (repair)

Acute primary and chronic OLT fragments can be fixed directly back into the defect, when the osteochondral

fragment has a minimum diameter of at least 10 mm and depth of 3 mm (19). For acutely displaced OLT in the skeletally immature, fixation should be considered in the first place, while acute symptomatic but stable lesions and chronic lesions should initially be treated conservatively. The benefits of fixation over other surgical treatments are the ability to restore the congruency of the talus and the preservation of hyaline cartilage and subchondral bone.

After exposure by arthrotomy, malleolar osteotomy or arthroscopically, the osteochondral fragment is removed and the underlying bone and/or cyst curetted or drilled. Autologous bone graft is used as needed in the presence of bony defects. Fixation is achieved by absorbable pins, headless compression screws or countersunk standard 1.5 or 2 mm screws.

Outcomes for open fixation of osteochondral fragments have been reported in multiple studies. Schuh *et al.* (20) found excellent and good results according to the Ogilvie-Harris score in 80 and 20% of patients, respectively. A mean Japanese Society for Surgery of the Foot ankle/hindfoot score of 93 out of 100 points at 2 years postoperatively for 44 patients was reported by Haraguchi *et al.* (21).

#### Bone marrow stimulation (regeneration)

In 1959, Pridie (22) introduced bone marrow stimulation (BMS; i.e. microfracture, retrograde drilling) of OLT. Today, BMS is the most common first-line technique of operative treatment for OLT, even without proven superiority over debridement alone (23).

First the unstable cartilage is resected, then the bed of the OLT is debrided back to bleeding bone and penetrated with an awl or a drill. In case of a cyst, the cyst has to be removed by curettage and filled with bone graft from the calcaneus, tibia or iliac crest. In patients with lesions within the subchondral bone but intact hyaline cartilage, retrograde drilling can be offered with the aim of treating the subchondral lesion whilst preserving overlying cartilage (24). In the retrograde drilling procedure, talar surface without articular cartilage is selected for the entry of the guidewire. The wire is then directed into the lesion in a retrograde direction under image intensifier control. Overdrilling of the wire allows curettage of cysts and filling with for example, an autologous bone graft.

Articular hyaline cartilage is avascular, subsequently, a defect not penetrating the subchondral bone has limited regenerative capabilities. The principal aim of BMS is revascularization of the defect.

BMS comes with several advantages: it is neither a technically demanding, nor an expensive technique with low morbidity and rapid recovery (3). An early return to full weight-bearing 2 weeks postoperatively has shown no inferior clinical outcome compared to a delayed weight-bearing (25). BMS leads to fibrocartilaginous repair tissue

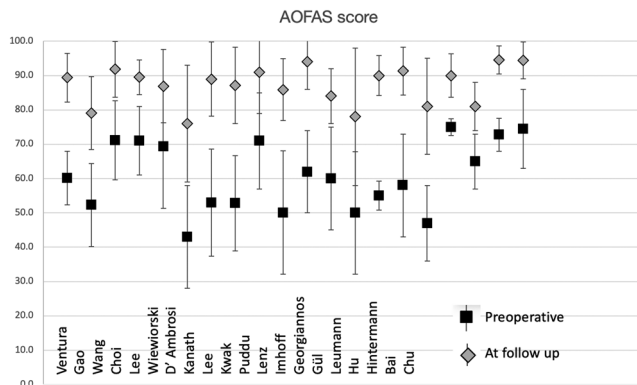
that is superior to the blank subchondral bone but has inferior biomechanical and biological properties and is not as resilient as native hyaline cartilage (26). In smaller OLTs, the fibrocartilage filling of the lesion is not exposed to a high load, but in bigger OLT, the mechanical load may lead to failure over time (26). This corresponds to the suggested cut-off size between 1.07 and 1.5cm<sup>2</sup> for the indication of BMS for OLT (9, 27, 28). Good short- to mid-term outcome has been reported after BMS, but 5 years after surgery, a deterioration of 35% has been shown by Ferkel *et al.* (11). The onset of OA caused by deterioration of the less resilient fibrocartilage over time, different joint biomechanics, and subchondral bone damage are concerns in the current literature and daily clinical practice. Several investigators have reported the manifestation of OA in their patients treated with BMS. Uncontained OLT (entailed the location on the shoulder of the talus) experiences inferior clinical outcomes (9, 29). The presence of a cyst as well as age as risk factors for inferior outcome are discussed contradictory in the literature (9, 29).

Depending on the location of the OLT, BMS often can be conducted arthroscopically. Arthroscopy carries the benefit of lower surgical morbidity, shorter rehabilitation and less stiffness (9).

#### AMIC (regeneration)

Autologous matrix-induced chondrogenesis (AMIC) was introduced in 2005 by Behrens (30). AMIC describes the application of a collagen type I/III bilayer porcine matrix glued into the defect after BMS and filling of a cyst if present. This matrix stabilizes the super clot released by BMS from the underlying bone and holds pluripotent stem cells. In a recent histological analysis of regenerated cartilage after AMIC (data submitted for journal review), not only fibrocartilage but also hyaline-like cartilage tissue with comparable biomechanical properties to native hyaline cartilage was present. Similar to BMS, AMIC is a single-step, technically rather easy and economical procedure that avoids donor site morbidity. Good short- to mid-term results have been published after primary AMIC. Two years postoperatively, the AOFAS score improved from 60 to 89 points (Fig. 2) and the VAS pain score from 5 to 1.6 on average in 26 AMIC procedures (31). In over 50% of this cohort, a ligament repair or reconstruction, a corrective calcaneal osteotomy, or both were executed concomitant to the AMIC procedure. This has to be kept in mind, as the underlying cause has to be addressed to achieve healing of the lesion.

Complete defect filling was seen in 88% of patients ( $n=33$ ) treated with AMIC when evaluated by MRI, along with a decrease of pain and improvement in function at 4.7 (mean; range, 2.3–8.0) years postoperatively (32). A systematic review of 13 papers, further confirmed the efficacy of AMIC (33). In another study, FFI-D score improved from 56 points preoperatively to 33 at 1-year follow-up and



**Figure 2**

AOFAS outcome score before and after surgery for osteochondral lesion of the talus.

24 after 5 years in 21 patients (34). At a 5-year follow-up, there was also a substantial return-to-sport rate.

AMIC can be combined with autologous iliac crest BMAC delivered on the collagen matrix in an attempt to increase the amount and quality of hyaline-like cartilage in the defect. BMAC has been demonstrated to have good long-term results in the treatment of both OLTs and OA. In one of these studies patients receiving BMAC therapy demonstrated significantly increased AOFAS scores, decreased Ankle Osteoarthritis Scale pain and disability subscales and high patient satisfaction after 24 months and 10-year follow-up (35).

### Cartilage implantation (regeneration)

Autologous chondrocyte implantation (ACI) is a two-step procedure (36). Healthy chondrocytes are sampled from a non-weight-bearing area. The donor site is mainly the anterior talus or the knee. The cells are isolated and grown *in vitro* for 2–6 weeks. In a second surgery, the cultured chondrocytes are implanted into the talar defect and covered with periosteum or a biomembrane. matrix-induced autologous chondrocyte implantation (MACI) is a second generation of ACI where the use of a matrix replaces the periosteal patch in securing the implanted autologous chondrocytes. While BMS leads to the growth of fibrocartilage, ACI and MACI on the other hand provide hyaline-like cartilage tissue with similar biomechanical properties to native hyaline cartilage. Failure after ACI was recorded early in patients with insufficient integration of the lesion, but there was less deterioration over time than seen in BMS cases (37). This leads to the hypothesis that ACI provides more resilient tissue with increased durability also in patients with bigger lesions and/or failed previous surgery for OLT (38). Three disadvantages of this technique are the necessity of two surgeries, the high costs and the possible donor site morbidity in the before healthy knee joint.

### Autograft (replacement)

Osteochondral autologous transplantation surgery (OATS) (39) has been introduced for OLT too big for treatment with the above-described techniques such as BMS and ACI and for OLTs located at the talar shoulder or with an unstable rim of the surrounding cartilage. OATS describes the transplantation of osteochondral cylinders (mainly from the knee) into the talar lesion. Depending on the size and shape of the lesion, mosaicplasty utilizing several smaller plugs may provide a better fit. The advantage is the replacement of damaged cartilage with autologous, healthy hyaline cartilage and the ability to fill lesions up to 4 cm<sup>2</sup>. However, there are problems as the curvature of the knee articular surface is different from the one of the talus and the talar cartilage is less thick (under 1 mm) compared to the knee cartilage (1.5–2.6 mm) (40, 41). Short to mid-term results are promising with good to excellent results in 87–94% (42, 43, 44). In a systematic review, pooled success rate (AOFAS score >80) after autografts has been reported to be 77% for primary lesions and 90% for secondary lesions (45). OATS and mosaicplasty, both come with a donor site morbidity in a before healthy knee joint in 12–15% of the patients (44).

### Allograft (replacement)

Osteochondral allograft is also used in substantial cartilage and subchondral bone lesions with a size up to 4 cm<sup>2</sup> and in revision cases. The allograft is chosen to be size matched and provides viable hyaline cartilage and structural bone. Grafts can be frozen or stored at 4°C. For allografts, the pooled clinical success rate was found to be 55% in secondary lesions and ranged from 20 to 100% for primary lesions in a systematic review (45). In another recent systematic review, the mean preoperative AOFAS score of six studies was 50 and increased to 80 at follow-up (46). The VAS pain score improved from 7.3 preoperatively to 2.6 at follow-up in five studies. Over 90% of patients are satisfied with the outcome (47, 48, 49). After allograft, there was a higher revision rate (28.1% compared to autologous osteochondral transplantation 6.7%) (50).

## Discussion

Osteochondral lesion of the talus: still a problem? The answer is probably yes and no.

Yes, because the evidence with regard to the comparison of different techniques and long-term results in the literature is still low. As the gold standard treatment of OLT has yet to be found, newer experimental techniques are constantly introduced. A systematic review of 52 studies including 1236 primary OLT by Dahmen *et al.* (30) to detect the most effective treatment for OLT



concluded that none of the interventions were clinically superior over another.

No, because all current techniques appear to result in a significant improvement of ankle function and pain. Generally, contained OLT of the talar dome has a better outcome than uncontained lesion of the talar shoulder. The recent studies all report an AOFAS hindfoot score between 80 and 90 at the latest follow-up (minimum 24 months).

The surgical technique should be primarily selected depending on the status of the overlying cartilage, size, and containment of the OLT. Although the outcomes of most of these techniques are encouraging, it is impossible to recommend one procedure over another due to a lack of comparative analyses. Consequently, treatment should be individualized for every single patient, with appropriate counseling in terms of outcome and associated pros and cons of the recommended technique.

Most foot and ankle surgeons agree (but there is still no evidence) that, in patients with an underlying cause for the OLT, the therapy of this cause is essential for a successful treatment of the OLT. Common underlying causes are chronic lateral or medial ligamentous ankle instability and hindfoot malalignment in either isolation or combination. Without addressing these pathologies, the likelihood of poor results or even failures appears to be much higher.

For instance, any lateral OLT should be investigated for underlying instability and hindfoot varus malalignment and treated at the same time.

## Conclusion

The aetiology of OLT remains not fully clarified but either an acute major or chronic repetitive minor ankle trauma or a local ischaemia in isolation or combination with any trauma are likely involved. The range of non-operative treatment and chondroplasty techniques is wide, whereas most techniques demonstrate similar and appropriate results.

Given the paucity of comparative research on OLT treatment outcomes, there are no specific criteria to guide the orthopedic surgeon to the optimal option, and treatment should therefore be individualized for every single patient. The decision of which approach is most suited to each patient also depends on the specific presentation of the OLT for example, size, site (contained or uncontained), depth and presence of subchondral cysts. All of these procedures have pros and cons, and a decision has to be made regarding the assumed efficacy in consideration with the potential risks, for example, donor site morbidity. The threshold for additional surgical steps, that is, ligament repair or reconstruction and bony realignment procedures, should be low.

### ICMJE Conflict of Interest Statement

F K reports receiving consultancy fees from Zimmer and Lecture fees from Geistlich, Swiss Foot Ankle Society and royalties from Marquardt, Ortho team.

### Funding Statement

The work reported here did not receive any specific grant from any funding agency in the public, commercial or not-for-profit sector.

## References

1. **Paget J.** On the production of some of the loose bodies and joints. *St. Bartholomew's Hospital Reports* 1870 **6** 1–4.
2. **König F.** Ueber freie Körper in den Gelenken. *Deutsche Zeitschrift für Chirurgie* 1888 **27** 90–109. (<https://doi.org/10.1007/BF02792135>)
3. **Dahmen J, Lambers KTA, Reilingh ML, van Bergen CJA, Stufkens SAS & Kerkhoffs GMMJ.** No superior treatment for primary osteochondral defects of the talus. *Knee Surgery, Sports Traumatology, Arthroscopy* 2018 **26** 2142–2157. (<https://doi.org/10.1007/s00167-017-4616-5>)
4. **van Diepen PR, Dahmen J, Altink JN, Stufkens SAS & Kerkhoffs GMMJ.** Location distribution of 2,087 osteochondral lesions of the talus. *Cartilage* 2021 **13** (1\_Supplement) 1344S–1353S. (<https://doi.org/10.1177/1947603520954510>)
5. **Barbier O, Amouyel T, de l'Escalopier N, Cordier G, Baudrier N, Benoist J, Dubois-Ferrière V, Leiber F, Morvan A, Mainard D, et al.** Osteochondral lesion of the talus: what are we talking about? *Orthopaedics and Traumatology, Surgery and Research* 2021 **107** 103068. (<https://doi.org/10.1016/j.otsr.2021.103068>)
6. **Kim YS, Kim TY & Koh YG.** Demographic predictors of concomitant osteochondral lesion of the talus in patients with chronic lateral ankle instability. *Foot and Ankle Orthopaedics* 2021 **6** 24730114211013344. (<https://doi.org/10.1177/24730114211013344>)
7. **van Dijk CN, Reilingh ML, Zengerink M & van Bergen CJ.** Osteochondral defects in the ankle: why painful? *Knee Surgery, Sports Traumatology, Arthroscopy* 2010 **18** 570–580. (<https://doi.org/10.1007/s00167-010-1064-x>)
8. **Frenkel SR & Di Cesare PE.** Degradation and repair of articular cartilage. *Frontiers in Bioscience* 1999 **4** D671–D685. (<https://doi.org/10.2741/frenkel>)
9. **Choi WJ, Jo J & Lee JW.** Osteochondral lesion of the talus: prognostic factors affecting the clinical outcome after arthroscopic marrow stimulation technique. *Foot and Ankle Clinics* 2013 **18** 67–78. (<https://doi.org/10.1016/j.fcl.2012.12.004>)
10. **Berndt AL & Harty M.** Transchondral fractures (osteochondritis dissecans) of the talus. *Journal of Bone and Joint Surgery* 1959 **41** 1363. (<https://doi.org/10.2106/00004623-195941070-00020>)
11. **Ferkel RD, Zanotti RM & Komenda GA.** Arthroscopic treatment of osteochondral lesions of the talus: technique and results. *American Journal of Sports Medicine* 2008 **36** 1750–1762. (<https://doi.org/10.1177/0363546508316773>)
12. **Hepple S, Winson IG & Glew D.** Osteochondral lesions of the talus: a revised classification. *Foot and Ankle International* 1999 **20** 789–793. (<https://doi.org/10.1177/107110079902001206>)
13. **Elias I, Zoga AC, Morrison WB, Besser MP, Schweitzer ME & Raikin SM.** Osteochondral lesions of the talus: localization and morphologic data from 424 patients using a novel anatomical grid scheme. *Foot and Ankle International* 2007 **28** 154–161. (<https://doi.org/10.3113/FAI.2007.0154>)

- 14. Seo SG, Kim JS, Seo DK, Kim YK, Lee SH & Lee HS.** Osteochondral lesions of the talus. *Acta Orthopaedica* 2018 **89** 462–467. (<https://doi.org/10.1080/17453674.2018.1460777>)
- 15. Mei-Dan O, Carmont MR, Laver L, Mann G, Maffulli N & Nyska M.** Platelet-rich plasma or hyaluronate in the management of osteochondral lesions of the talus. *American Journal of Sports Medicine* 2012 **40** 534–541. (<https://doi.org/10.1177/0363546511431238>)
- 16. Akpancar S & Gul D.** Comparison of platelet rich plasma and prolotherapy in the management of osteochondral lesions of the talus: a retrospective cohort study. *Medical Science Monitor* 2019 **25** 5640–5647. (<https://doi.org/10.12659/MSM.914111>)
- 17. Boffa A, Previtali D, Di Laura Frattura G, Vannini F, Candrian C & Filardo G.** Evidence on ankle injections for osteochondral lesions and osteoarthritis: a systematic review and meta-analysis. *International Orthopaedics* 2021 **45** 509–523. (<https://doi.org/10.1007/s00264-020-04689-5>)
- 18. Canale ST & Belding RH.** Osteochondral lesions of the talus. *Journal of Bone and Joint Surgery: American Volume* 1980 **62** 97–102. (<https://doi.org/10.2106/00004623-198062010-00014>)
- 19. Reilingh ML, van Bergen CJ, Blankevoort L, Gerards RM, van Eekeren IC, Kerkhoffs GM & van Dijk CN.** Computed tomography analysis of osteochondral defects of the talus after arthroscopic debridement and microfracture. *Knee Surgery, Sports Traumatology, Arthroscopy* 2016 **24** 1286–1292. (<https://doi.org/10.1007/s00167-015-3928-6>)
- 20. Schuh A, Salminen S, Zeiler G & Schraml A.** Ergebnisse der refixation der Osteochondrosis Dissecans D. Talus mit Kirschnerdrähten. *Zentralblatt für Chirurgie* 2004 **129** 470–475. (<https://doi.org/10.1055/s-2004-832393>)
- 21. Haraguchi N, Shiratsuchi T, Ota K, Ozeki T, Gibu M & Niki H.** Fixation of the osteochondral talar fragment yields good results regardless of lesion size or chronicity. *Knee Surgery, Sports Traumatology, Arthroscopy* 2020 **28** 291–297. (<https://doi.org/10.1007/s00167-019-05716-8>)
- 22. Pridie K.** A method of resurfacing osteoarthritic knee joint. *Journal of Bone and Joint Surgery: British Volume* 1959 **41**. (<https://doi.org/10.1302/0301-620X.41B3.616>)
- 23. Marin Fermin T, Hovsepian JM, D’Hooghe P & Papakostas ET.** Arthroscopic debridement of osteochondral lesions of the talus: a systematic review. *Foot* 2021 **49** 101852. (<https://doi.org/10.1016/j.foot.2021.101852>)
- 24. Lomax A & Calder JD.** Retrograde drilling for the treatment of osteochondral lesions in the ankle. In *Arthroscopy*, pp. 1023–1031. Eds **P Randelli, D Dejour, C van Dijk, M Denti & R Seil**. Springer, 2016. ([https://doi.org/10.1007/978-3-662-49376-2\\_85](https://doi.org/10.1007/978-3-662-49376-2_85))
- 25. Lee DH, Lee KB, Jung ST, Seon JK, Kim MS & Sung IH.** Comparison of early versus delayed weightbearing outcomes after microfracture for small to mid-sized osteochondral lesions of the talus. *American Journal of Sports Medicine* 2012 **40** 2023–2028. (<https://doi.org/10.1177/0363546512455316>)
- 26. Murawski CD, Foo LF & Kennedy JG.** A review of arthroscopic bone marrow stimulation techniques of the talus: the good, the bad, and the causes for concern. *Cartilage* 2010 **1** 137–144. (<https://doi.org/10.1177/1947603510364403>)
- 27. Choi WJ, Park KK, Kim BS & Lee JW.** Osteochondral lesion of the talus: is there a critical defect size for poor outcome? *American Journal of Sports Medicine* 2009 **37** 1974–1980. (<https://doi.org/10.1177/0363546509335765>)
- 28. Ramponi L, Yasui Y, Murawski CD, Ferkel RD, DiGiovanni CW, Kerkhoffs GMMJ, Calder JDF, Takao M, Vannini F, Choi WJ, et al.** Lesion size is a predictor of clinical outcomes after bone marrow stimulation for osteochondral lesions of the talus: a systematic review. *American Journal of Sports Medicine* 2017 **45** 1698–1705. (<https://doi.org/10.1177/0363546516668292>)
- 29. Dankert J, Kennedy JG, Shimozone Y, Deyer T & Mercer NP.** Predictors of outcomes of microfracture for osteochondral lesions of the talus. *Foot and Ankle Orthopaedics* 2022 **7** 2473011421500014. (<https://doi.org/10.1177/2473011421500014>)
- 30. Behrens P.** Matrixgekoppelte Mikrofrakturierung Ein neues Konzept zur Knorpeldefektbehandlung. *Arthroskopie* 2005 **18** 193–197. (<https://doi.org/10.1007/s00142-005-0316-0>)
- 31. Valderrabano V, Miska M, Leumann A & Wiewiorski M.** Reconstruction of osteochondral lesions of the talus with autologous spongiosa grafts and autologous matrix-induced chondrogenesis. *American Journal of Sports Medicine* 2013 **41** 519–527. (<https://doi.org/10.1177/0363546513476671>)
- 32. Weigelt L, Hartmann R, Pfirrmann C, Espinosa N & Wirth SH.** Autologous matrix-induced chondrogenesis for osteochondral lesions of the talus: a clinical and radiological 2- to 8-year follow-up study. *American Journal of Sports Medicine* 2019 **47** 1679–1686. (<https://doi.org/10.1177/0363546519841574>)
- 33. Malahias MA, Kostretzis L, Megalokonomos PD, Cantiller EB, Chytas D, Thermann H & Becher C.** Autologous matrix-induced chondrogenesis for the treatment of osteochondral lesions of the talus: a systematic review. *Orthopedic Reviews* 2020 **12** 8872. (<https://doi.org/10.4081/or.2020.8872>)
- 34. Gottschalk O, Altenberger S, Baumbach S, Kriegelstein S, Dreyer F, Mehlhorn A, Hörterer H, Töpfer A, Röser A & Walther M.** Functional medium-term results after autologous matrix-induced chondrogenesis for osteochondral lesions of the talus: a 5-year prospective cohort study. *Journal of Foot and Ankle Surgery* 2017 **56** 930–936. (<https://doi.org/10.1053/j.jfas.2017.05.002>)
- 35. Vannini F, Filardo G, Altamura SA, Di Quattro E, Ramponi L, Buda R, Giannini S & Faldini C.** Bone marrow aspirate concentrate and scaffold for osteochondral lesions of the talus in ankle osteoarthritis: satisfactory clinical outcome at 10 years. *Knee Surgery, Sports Traumatology, Arthroscopy* 2021 **29** 2504–2510. (<https://doi.org/10.1007/s00167-021-06494-y>)
- 36. Brittberg M, Lindahl A, Nilsson A, Ohlsson C, Isaksson O & Peterson L.** Treatment of deep cartilage defects in the knee with autologous chondrocyte transplantation. *New England Journal of Medicine* 1994 **331** 889–895. (<https://doi.org/10.1056/NEJM199410063311401>)
- 37. Peterson L, Brittberg M, Kiviranta I, Akerlund EL & Lindahl A.** Autologous chondrocyte transplantation. Biomechanics and long-term durability. *American Journal of Sports Medicine* 2002 **30** 2–12. (<https://doi.org/10.1177/03635465020300011601>)
- 38. Kwak SK, Kern BS, Ferkel RD, Chan KW, Kasraeian S & Applegate GR.** Autologous chondrocyte implantation of the ankle: 2- to 10-year results. *American Journal of Sports Medicine* 2014 **42** 2156–2164. (<https://doi.org/10.1177/0363546514540587>)
- 39. Outerbridge HK, Outerbridge AR & Outerbridge RE.** The use of a lateral patellar autologous graft for the repair of a large osteochondral defect in the knee. *Journal of Bone and Joint Surgery: American Volume* 1995 **77** 65–72. (<https://doi.org/10.2106/00004623-199501000-00009>)
- 40. Al-Ali D, Graichen H, Faber S, Englmeier KH, Reiser M & Eckstein F.** Quantitative cartilage imaging of the human hind foot: precision and inter-subject variability. *Journal of Orthopaedic Research* 2002 **20** 249–256. ([https://doi.org/10.1016/S0736-0266\(01\)00098-5](https://doi.org/10.1016/S0736-0266(01)00098-5))

- 41. Ateshian GA, Soslowsky LJ & Mow VC.** Quantitation of articular surface topography and cartilage thickness in knee joints using stereophotogrammetry. *Journal of Biomechanics* 1991 **24** 761–776. ([https://doi.org/10.1016/0021-9290\(91\)90340-s](https://doi.org/10.1016/0021-9290(91)90340-s))
- 42. Hangody L, Kish G, Modis L, Szerb I, Gaspar L, Dioszegi Z & Kendik Z.** Mosaicplasty for the treatment of osteochondritis dissecans of the talus: two to seven year results in 36 patients. *Foot and Ankle International* 2001 **22** 552–558. (<https://doi.org/10.1177/107110070102200704>)
- 43. Hangody L, Vasarhelyi G, Hangody LR, Sukosd Z, Tibay G, Bartha L & Bodó G.** Autologous osteochondral grafting – technique and long-term results. *Injury* 2008 **39** (Supplement 1) S32–S39. (<https://doi.org/10.1016/j.injury.2008.01.041>)
- 44. Zengerink M, Struijs PA, Tol JL & van Dijk CN.** Treatment of osteochondral lesions of the talus: a systematic review. *Knee Surgery, Sports Traumatology, Arthroscopy* 2010 **18** 238–246. (<https://doi.org/10.1007/s00167-009-0942-6>)
- 45. Lambers KTA, Dahmen J, Reilingh ML, van Bergen CJA, Stufkens SAS & Kerkhoffs GMMJ.** No superior surgical treatment for secondary osteochondral defects of the talus. *Knee Surgery, Sports Traumatology, Arthroscopy* 2018 **26** 2158–2170. (<https://doi.org/10.1007/s00167-017-4629-0>)
- 46. Pereira GF, Steele JR, Fletcher AN, Clement RD, Arasa MA & Adams SB.** Fresh osteochondral allograft transplantation for osteochondral lesions of the talus: a systematic review. *Journal of Foot and Ankle Surgery* 2021 **60** 585–591. (<https://doi.org/10.1053/j.jfas.2021.02.001>)
- 47. Hahn DB, Aanstoos ME & Wilkins RM.** Osteochondral lesions of the talus treated with fresh talar allografts. *Foot and Ankle International* 2010 **31** 277–282. (<https://doi.org/10.3113/FAI.2010.0277>)
- 48. Gortz S, De Young AJ & Bugbee WD.** Fresh osteochondral allografting for osteochondral lesions of the talus. *Foot and Ankle International* 2010 **31** 283–290. (<https://doi.org/10.3113/FAI.2010.0283>)
- 49. Raikin SM.** Fresh osteochondral allografts for large-volume cystic osteochondral defects of the talus. *Journal of Bone and Joint Surgery: American Volume* 2009 **91** 2818–2826. (<https://doi.org/10.2106/JBJS.I.00398>)
- 50. Azam M, Davey MS, Colasanti C, Mercer NP, Hurley ET, Shimozono Y & Kennedy JG.** Cylindrical osteochondral allograft for osteochondral lesions of the talus: a systematic review. *Foot and Ankle Orthopaedics* 2022 **7** 2473011421500101. (<https://doi.org/10.1177/2473011421500101>)