



The influence of shoulder arthrodesis on the function of the upper limb in adult patients after a brachial plexus injury: a systematic literature review with elements of meta-analysis

Michał Górecki
Piotr Czarnecki

- Based on the literature, 294 shoulder arthrodeses after brachial plexus injury in adults were assessed, mostly male; the mean age of the patients was 33 years, and the mean follow-up time was 5.5 years. The most common cause of injury was a traffic accident, especially on a motorcycle.
- Arthrodesis position ranged from 15 to 40 degrees of flexion, 15 to 60 degrees of abduction, and 0 to 50 degrees of internal rotation with the predominance of position by the 30-30-30 rule. Plates, screws, and external fixation were used for stabilization. The complication rate was at the level of 28%, the most common complication being delayed union or nonunion.
- Active movements of flexion and abduction averaged 61 and 56 degrees, respectively, while reaching the hand to the mouth, front pocket, and buttock was feasible for 69%, 71%, and 38%, respectively, after surgery. Shoulder pain was present in 77% of patients, and 28% experienced no relevant pain reduction after surgery. The subjective satisfaction rate was 82% based on significant improvement and satisfaction reported by patients after arthrodesis.
- Arthrodesis of the shoulder, in adult patients after brachial plexus palsy, can reduce shoulder pain, increase stability, and result in a range of motion that increases the possibility of carrying out everyday activities. This affects the high level of subjective patient satisfaction after surgery.

Keywords: brachial plexus palsy; shoulder arthrodesis; systematic review

Cite this article: *EFORT Open Rev* 2021;6:797-807.

DOI: 10.1302/2058-5241.6.200114

Introduction

‘Shoulder arthrodesis’ or ‘shoulder fusion’ is a procedure that involves the fusion of the humeral head to the glenoid. In some techniques, additional acromioclavicular

arthrodesis is also performed.¹ At the beginning of the 20th century, this type of surgery was widely used for treatment due to numerous indications, such as osteoarthritis, rheumatoid arthritis, irreparable injury of the rotator cuff, severely comminuted fracture of the proximal humerus, glenohumeral destruction resulting from tuberculosis, and recurrent dislocations of the shoulder. In recent years, surgical indications for shoulder arthrodesis have been continuously decreasing due to the development of shoulder arthroplasty, for which results have proved more promising. Nowadays, shoulder arthrodesis is one of the salvage and reconstructive procedures used in brachial plexus palsy resulting from an injury in adult patients.^{1–16}

Damage to the upper brachial plexus leads to a complete lack of shoulder function. The C5 and C6 roots are damaged, which leads to the suprascapular, subscapular, and axillary nerves becoming dysfunctional, and the consequence is rotator cuff and deltoid muscle paralysis. This causes significant shoulder dysfunction with a lack of active movement of abduction, flexion, and external and internal rotation of the arm. In the absence of spontaneous nerve regeneration, surgical treatment should be undertaken approximately 3–6 months after injury.¹⁶ Microsurgical techniques aim to restore suprascapular and axillary nerve function, but their results remain uncertain. Muscular transfers allow the restoration of active range of motion in abduction and external rotation, but those techniques are less reliable in the restoration of shoulder function than, for example, in the restoration of elbow flexion.^{16,17} A good alternative for that secondary procedure might be shoulder arthrodesis. It can improve shoulder stability, relieve pain, and partially restore the shoulder’s active range of motion (ROM). It allows basic daily activities to be performed and increases the patient’s quality of life.^{1,7,15–18} After glenohumeral fusion, the shoulder’s functional ROM is retained through scapula thoracic

movement by the periscapular muscles, the trapezius, serratus anterior, and rhomboid muscles. Their proper function and strength are necessary for carrying out this type of operation.

The aim of this article was a systematic review of the literature for shoulder arthrodesis in adult patients for whom the surgical indication was a brachial plexus injury and the impact of this type of surgery on the final result, the functioning of the upper limb, and patient satisfaction.

Material and methods

This systematic review was conducted according to the Preferred Reporting Items for Systematic Reviews and Meta-Analyses (PRISMA) guidelines.¹⁹

Search strategy

A systematic search of PubMed, Medline, and ResearchGate was conducted from inception until April 2021 to identify studies reporting the treatment outcomes of shoulder arthrodesis for adult patients with a brachial plexus injury. Keywords used in the electronic search included: (((shoulder) OR (glenohumeral)) AND ((fusion) OR (arthrodesis))). The reference list for each potentially eligible text was reviewed to identify any additional relevant articles.

Eligibility criteria

The titles of papers and their abstracts were analysed, and those which reported on functional outcomes after shoulder arthrodesis with patients above the age of 18 years were selected. We excluded: papers of veterinary cases, descriptions of the operation technique only, papers written in languages other than English, articles without abstracts. Then selected papers were evaluated based on the full texts and those where the indication for arthrodesis was a brachial plexus injury qualified. At this stage, we rejected publications that did not include the final results of treatment and where it was impossible to clearly select only the data of patients with a brachial plexus injury.

Data extraction

All relevant data were extracted for a systematic review with the use of a data collection table. The data extracted included: the number of arthrodeses, gender, age during surgery, follow-up time, mechanism of injury (MOI), indication for arthrodesis, the type of fixation, the position of the arthrodesis, complications, revisions, functional outcomes such as hand excursion and active range of motion of the shoulder, pain before and after the operation, subjective patient satisfaction. Data extraction was deemed complete once all reviewers were in total agreement.

Statistical analysis

All results as a percentage were determined based on a meta-analysis, while the range of motion after arthrodesis (flexion, abduction) was determined based on the weighted average of the available articles. For the statistical analysis, a test comparing two percentages was used (after the meta-analysis), and the results with $p < 0.05$ were considered statistically significant.

Results

Literature

The search of electronic databases revealed a total of 351 relevant studies. Once duplicates were removed, 257 articles remained. An initial screening of titles and abstracts fielded 77 potentially eligible publications. Inclusion and exclusion criteria were used on the full texts of these. From this, 14 articles were included in the final study. Rühmann et al from 2005²⁰ was included conditionally due to the large study group. In this study, the main indication for arthrodesis was brachial plexus injury, while a smaller group of patients had other indications. It was impossible to isolate demographic data from both groups, which, in our opinion, is of little importance, but importantly, it is possible to separate the obtained results for the group of patients with brachial plexus injury.

All collected articles report 287 cases of patients with shoulder arthrodesis after brachial plexus injury, which they experienced in adulthood. Details of the study screening and selection are shown in Fig. 1. Tables 1 to 4 give an overview of the data extracted from the literature review.

Demographics and aetiology

Two hundred and eighty-seven shoulder arthrodesis cases after a brachial plexus injury in adulthood were reported. The average age of patients during the surgery was 33 years old. The mean follow-up of all included publications was 5.5 years (range 0.6–20 years). The MOI was defined in 13 articles^{8,9,11,17,21–29} and the most common cause of injury was a traffic accident, especially on a motorcycle.

Indication

The indications for shoulder arthrodesis were clearly defined in five publications and mostly concerned a significant limitation of shoulder functions and, to a much lesser extent, shoulder pain.^{11,21,30–32}

Before arthrodesis, 77 patients in seven publications^{23–25,27,30–32} had additional neurosurgical procedures, such as brachial plexus exploration in 46 cases, transfer of the spinal accessory nerve to the suprascapular nerve in 14 cases, suprascapular nerve or upper trunk grafting in 13

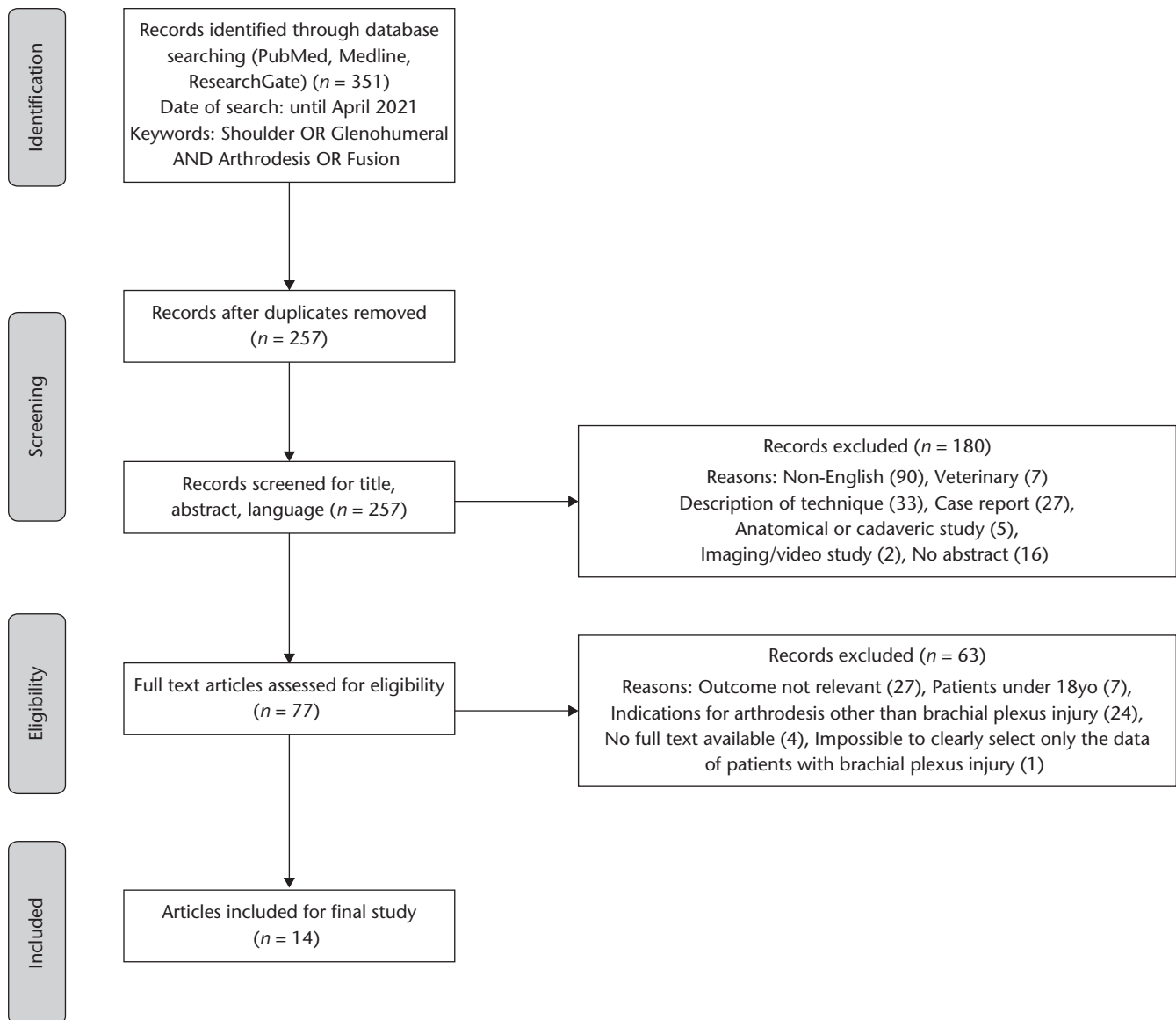


Fig. 1 PRISMA (Preferred Reporting Items for Systematic Reviews and Meta-Analyses) guidelines flowchart illustrating the search strategy.

cases, and neurolysis of brachial plexus in four cases. Four publications^{23,27,30,31} reported no significant improvement in shoulder function after surgery with a shoulder strength of 2 or less on the Medical Research Council (MRC) scale, and in the other three,^{24,25,32} no direct effect on shoulder function was described, while all these patients qualified for shoulder arthrodesis, which may suggest no significant improvement of function.

Technique of arthrodesis

Two types of internal fixation were used: a plate in 200 cases^{17,22,24,26–29,32,33} and screws in 97 cases.^{9,11,21,23,25,28,33} Additionally, in 28 cases of stabilization with screws, a

Hoffmann external fixator was used.^{9,23} In four publications (78 cases), the technique additionally included the use of bone grafts.^{17,21–23} One publication describes an arthroscopic surgical technique,²³ the rest describes the classic open surgery technique.

The arthrodesis position was presented in 11 articles^{11,17,21–26,29,32,33} and ranged from 15 to 40° of flexion, from 15 to 60° of abduction, and from 0 to 50° of internal rotation. Authors in five publications applied the ‘30-30-30’ position, which means 30° of flexion, abduction, and internal rotation.^{17,22–24,32} One work described the arthrodesis angle’s determination based on the individual needs of the patient (Table 2).²⁸

Table 1. Review of the literature: demographic data, indication, and additional procedures

No.	Author of publication (year)	No. of arthrodesis	Male/Female	Age (years)	Indication for arthrodesis (no. of patients)		No. of additional procedures before arthrodesis ^a
					Limitation of shoulder functions	Shoulder pain	
1	Cofield and Briggs (1979) ²¹	21	19/2	27	16	5	–
2	Richards et al (1985) ²⁴	14	14/0	30	–	–	9
3	Vastamäki (1987) ¹¹	14	8/6	26	14	0	–
4	Rouholamin et al (1991) ²⁵	13	12/1	28	–	–	6
5	Richards et al (1993) ³²	46	44/2	30	46	0	42
6	Rühmann et al (1999) ²⁶	14	12/2	34	–	–	–
7	Chammas et al (2004) ⁹	27	25/2	25	27	0	11
8	Rühmann et al (2005) ⁸	32	33/10*	35*	–	–	–
9	Sousa et al (2011) ²⁷	13	11/2	46	–	–	4
10	Atlan et al (2012) ¹⁷	54	54/0	24	–	–	0
11	Ivalde et al (2017) ²²	12	12/0	29	–	–	–
12	Lenoir et al (2017) ^{23‡}	8	8/0	33	–	–	3
13	Thangarajah and Lambert (2017) ²⁸	7	6/1	48	7	0	2
14	van der Lingén et al (2018) ²⁹	12	11/1	46	–	–	–
		287	269/29	33	110	5	77

*Data of patients with brachial plexus palsy and other indication for arthrodesis.

‡Arthroscopic method.

^aThe procedures are detailed in the text.

Table 2. Review of the literature: position of arthrodesis and type of stabilization

No.	Position of arthrodesis [°]			Type of stabilization		
	Flexion	Abduction	Internal rotation	Plate	Screws (with ex.fix.)	Bone graft
1	25°	45°	20°	0	21	3
2	30°	30°	30°	14	0	0
3	15–30°	45–50°	–	0	13	0
4	30°	30°	20°	0	13	0
5	30°	30°	30°	46	0	0
6	30°	20°	40°	14	0	0
7	–	–	–	0	27 (21)	0
8	20–40°	20–60°	0–50°	30*	13*	0
9	–	–	–	13	0	0
10	30°	30°	30°	54	0	54
11	30°	30°	30°	12	0	12
12	30°	30°	30°	0	8 (8)	7
13		Individually		5	2	0
14	25–30°	15–20°	40–50°	12	0	0
	15–40°	15–60°	0–50°	200	97 (29)	76

*Data of patients with brachial plexus palsy and other indication for arthrodesis. '30-30-30' position.

Outcome and satisfaction

The final outcomes were presented in the form of a range of functional movements with hand excursion to reach the mouth, front pocket, and buttock and based on the shoulder's active range of motion. The flexion range was stated in ten articles and abduction in 11; it was determined based on the weighted average. Flexion was obtained up to 59° with a range of 10 to 105°,^{9,11,23–27,29,33} and abduction up to 55° with a range of 10 to 110°.^{9,11,17,22–27,29,33}

Reaching the hand to the mouth was included in ten publications and was feasible for 69% of operated patients,^{9,11,21,23–25,27,29,32,33} while reaching the hand to the front pocket, and buttock was described in six publications and was possible for 71% and 38% of patients, respectively.^{9,11,21,23,24,29,32}

Before surgery, shoulder pain was mentioned in seven articles and occurred at the level of 77%.^{9,11,21,23–25,28} Based on eight articles,^{9,11,21,23–25,29,32} shoulder pain after arthrodesis occurred at the level of 28% where patients did not experience a subjective reduction in pain, or it was at the level of six points and more, according to the Numeric Rating Scale (NRS) for pain, which corresponds to mild and severe pain in terms of pain-related interference with functioning.³⁴ There was a statistically significant reduction in the percentage of pain index after shoulder arthrodesis (p = < 0.0001).

Patient satisfaction was analysed. To standardize the results, we qualified for subjective satisfaction rate the excellent and good results and the patients' subjective functional improvement statement after the operation. Based on ten articles, the percentage of patients' subjective improvement and satisfaction after surgery was at the level of 82%, at 83% after plate stabilization and 78% after screw stabilization with no statistically significant difference between them (p = 0.4626) (Table 3).^{9,11,21,24–27,29,32,33}

Complications

Complications were described in 12 of the articles and occurred in 26% of cases. Delayed bone union or pseudoarthrosis, fracture of the humerus, and infection were

Table 3. Review of the literature: outcome, patient satisfaction, and follow-up

No	Active range of motion after an operation				% of patients able to reach by hand to:			% of patients with shoulder pain ²		Subjective satisfaction rate after operation ^a	Follow-up (years)
	Flexion		Abduction		Mouth	Front pocket	Buttock	Before surgery	After surgery		
	Average	Range	Average	Range							
1	–	–	–	–	61%	–	67%	24%	15%	75%	9.2
2	min. 50°	–	min. 60°	–	100%	100%	–	21%	27%	100%	3.0
3	58°	10–90°	56°	40–85°	64%	57%	43%	54%	31%	64%	7.0
4	50°	40–70°	56°	50–80°	77%	–	–	100%	15%	92%	2.8
5	–	–	–	–	75%	79%	33%	–	21%	92%	3.7
6	51°	30–90°	59°	40–90°	–	–	–	–	–	79%	1.2
7	61°	–	61°	–	89%	33%	15%	100%	70%	96%	5.9
8	59°	20–105°	56°	20–90°	96%	–	–	–	–	59%	0.6*
9	59°	–	44°	–	46%	–	–	–	–	92%	8.4
10	–	–	59°	20–110°	–	–	–	–	–	–	3.5
11	–	–	43°	10–100°	–	–	–	–	–	–	1.0
12	80°	60°–90°	59°	40–80°	25%	100%	75%	100%	13%	–	2.3
13	–	–	–	–	–	–	–	100%	–	–	8.0
14	60°	12–72°	48°	14–78°	58%	42%	8%	–	50%	67%	19.8
	59°	10–105°	55°	10–110°	69%	71%	38%	77%	28%	82%	5.5

*Data of patients with brachial plexus palsy and other indication for shoulder arthrodesis.

^aThe evaluation criteria are described in the text.

observed most often and were at the level of 10%, 6%, and 5% of cases, respectively. The remaining complications were less common, and their frequency was described as absolute numbers: irritation of the soft tissues above the plate, malposition, haematoma, loosening of the screw, postoperative necrosis of the skin – six, four, two, two, and one cases respectively.^{9,11,17,21–23,25–28,32,33} The complication rate was at the level of 26.1% after plate and 21.6% after screw stabilization, with a not statistically significant difference between them ($p = 0.4471$).

Delayed bone union or pseudoarthrosis occurred as a complication in 9.3% after plate and 10.3% after screw stabilization. In the technique with free bone grafts, the occurrence of delayed or nonunion was at the level of 9.1%, while without bone grafts it was at 9.4%. There was no statistically significant difference between the type of stabilization ($p = 0.7704$) or the use or non-use of free bone graft ($p = 0.9321$) on the incidence of delayed or nonunion.

Thirty-two revision operations were performed, including five in one patient,^{11,17,21,23,25–27,30–32} representing the reoperation rate at the level of 16.5%. The most common indication was nonunion and removal of stabilizing material (Table 4).

Discussion

The collected demographic data show that shoulder arthrodesis due to brachial plexus palsy is mainly applied in the population of young men injured during a motorcycle

accident. The most common indication for arthrodesis was shoulder function limitations, which made it difficult to perform basic daily activities. Shoulder arthrodesis was performed as an end-stage salvage procedure due to the lack of significant shoulder function improvement after previous reconstructive neurosurgical procedures.

Technique of arthrodesis

Type of stabilization

Many operating techniques for shoulder arthrodesis are described in the literature. Internal stabilization used in the Arbeitsgemeinschaft für Osteosynthesefragen (AO) technique describes the use of one or two wide AO plates.³⁵ For stabilization, Richards et al recommend using a 4.5 mm pelvic reconstruction plate because it is easier to bend than a classic AO plate.³⁶ The method described by Hawkins and Neer,³⁷ and Cofield and Briggs²¹ is the use of several long cancellous screws inserted laterally through the head of the humerus into the glenoid and vertically through the acromion to the head of the humerus. Some authors combine both fixation techniques in their surgical technique, most often in the form of several long cancellous screws, together with Hoffman's external fixator.^{38,39} The advantage is not having the necessity for immobilization, which allows limb movements to be performed after surgery.

As standard, shoulder arthrodesis is performed using the open method from the lateral approach, which is associated with extensive surgery. With the development of minimally invasive techniques, it is possible to perform

Table 4. Review of the literature: complications and revisions

No.	Complications								Revision rate ^a	
	Delayed / bone nonunion	Humerus fracture	Infection	Irritation of the soft tissues	Malposition	Haematoma	Loosening of the screw	Necrosis of the skin		Total
1	–	3	–	–	–	–	–	–	3	33%
2	–	–	–	–	–	–	–	–	–	–
3	3	–	–	–	–	–	–	–	3	21%
4	2	–	–	–	–	–	–	–	2	8%
5	1 #	–	1	4	–	–	1 #	–	7	13%
6	1 #	–	2 #	–	1 #	1 #	–	1	6	36% #
7	2	3	1	–	–	–	–	–	6	7%
8	4	3 †	3	–	2	1	–	–	13	–
9	1	1	–	–	1	–	–	–	3	8%
10	13	4	2	–	–	–	1	–	20	7%
11	–	1	1	1	–	–	–	–	3	–
12	–	–	1	1	–	–	–	–	2	25%
13	1 ^	–	–	–	–	–	–	–	1 ^	14%
14	–	–	–	–	–	–	–	–	–	–
	28 (10%)	15 (6%)	11 (5%)	6	4	2	2	1	69 (26%)	16.5%

#Complication in the same patient.

†Only for patients after plate stabilization.

^Only for patients after screw stabilization.

^aThe procedures are detailed in the text.

this type of surgery assisted with arthroscopy. Porcellini et al⁴⁰ show in their work that the final results after shoulder arthrodesis assisted with arthroscopy are comparable to those obtained using the classic open method but with less extensive surgery.

The current literature review reveals that all of the above-mentioned surgical techniques can be used for shoulder arthrodesis in patients with a brachial plexus injury. The authors of the first published papers preferred internal fixation using screws. Over time, the tendency changed, and in subsequent works, more and more authors began to choose stabilization using a plate. Only two papers describe the technique with the additional use of Hoffman’s external fixator. Besides, Lenoir et al²³ are the only ones who have performed a shoulder arthrodesis using arthroscopy in the collected articles. In their opinion, the most crucial advantage of this technique is a lower risk of damage to the circumflex humeral arteries and capsular periosteal blood supply, which can improve the fusion rate and reduce the risk of nonunion.

Long-term observation indicates that the type of internal stabilization did not significantly affect the final patient satisfaction, complication, or nonunion rates after surgery.

Position of arthrodesis

Many scientific articles have attempted to determine the optimal position of shoulder arthrodesis, and there are still different opinions on this subject. One of the first major works related to shoulder arthrodesis was published by the Research Committee of the American Orthopedic Association in 1942 and described the results of more than

100 shoulder arthrodeses. It proposed the position of the arthrodesis at 50° of abduction, 15–25° of flexion, and 25° of internal rotation.⁴¹ Rowe⁴² and Clare et al¹ recommend reducing the flexion and abduction to around 15–20° and increasing internal rotation to about 40–45°. They claim that excessive flexion and abduction cause a strong rotation and a winged scapula when the shoulder is at rest with the arm at the side. It can lead to fatigue of the scapulothoracic muscles and cause residual shoulder pain. In their opinion, the proposed flexion allows the patient to reach their hand to their mouth, internal rotation to the midline of the body, and abduction for ipsilateral armpit hygiene. On the other hand, Cofield and Briggs²¹ did not notice, in their work, that excessive flexion or abduction was associated with shoulder pain at rest. Arthrodesis made in an abduction greater than 45° or flexion greater than 25° did not cause significantly greater residual shoulder pain than the lower values of the position.

The collected publications do not clearly indicate the optimal position of the arthrodesis. It was performed in the range of flexion of 15–40°, abduction of 15–60° and internal rotation of 0–50°. There is a tendency among the authors of the publications to place the upper limb in a lower flexion and abduction position than was initially recommended in older literature, and non-excessive internal rotation. Some authors applied for the ‘30-30-30’ position, i.e., 30° of flexion, abduction, and internal rotation, a position which, in our opinion, could be reasonable. Jonsson et al also proposed an analogous position. In their work, they used moiré photography, which allowed them to establish the scapula’s neutral position.

They concluded that the optimal position for the arthrodesis would be 20–30° of flexion, abduction, and internal rotation. In their opinion, the angle of fusion in the internal rotation should be lower than 40° as it tends to allow better functioning of the shoulder.⁴³

The arthrodesis position should mostly satisfy the patient's expectations and facilitate their functioning in everyday life and work as much as possible. Based on many publications, the position is still not clearly defined, and perhaps it is worth thinking about an individual attitude towards each patient and determining the position of the arthrodesis based on their preferences as in the article by Thangarajah and Lambert. They temporarily stabilized the shoulder in a position established with the patients to assess whether it would be appropriate for them during everyday functioning.²⁸

Pain

Shoulder pain in patients after a brachial plexus injury may be associated with muscular balance disorder caused by paralysis of the shoulder stabilizing muscles. This occurs due to the instability of the shoulder joint and painful subluxations. Another cause of pain characteristic of this group of patients is neuropathic pain caused by direct damage to the brachial plexus somatosensory fibres.^{9,25,44–47}

In the collected articles, three-quarters of patients experienced chronic shoulder pain before surgery. Only in minority cases, was it an indication for surgical treatment. After arthrodesis, the percentage of pain decreased significantly but still occurred in one-quarter of patients and was the most common cause of dissatisfaction in long-term follow-up. Because of the different methods used in publications to assess the level of pain, the lack of improvement in this area was taken into account based on:

1. The subjective lack of reduction of shoulder pain after surgery or referred to as mild or severe.

2. Pain at the level of six points and more, according to the Numeric Rating Scale (NRS) for pain, corresponds to mild and severe pain in terms of pain-related interference with functioning.³⁴

As already mentioned in the discussion, shoulder pain after arthrodesis may be due to the limb's position in excessive flexion and abduction. This is a reason for reoperation and a corrective osteotomy of the humerus.^{1,18,42,48} Another reason may be the lack of bone union or incomplete bone union, which leads to severe shoulder pain, which is also an indication for reoperation.³³ The authors of the reviewed articles suggest that shoulder pain after surgery could have a neurogenic nature. Shoulder arthrodesis may reduce traction neuritis of the brachial plexus and relieve pain by increasing stabilization, but pain will not completely disappear. Symptomatic treatment is necessary, in the form of pharmacotherapy based on neurological drugs, including neuroleptics, tricyclic antidepressants, or antiepileptics.^{1,44,46} Recent scientific studies noticed that Transcutaneous Electrical Nerve Stimulation (TENS) plays a significant role in reducing neuropathic pain. If used early enough, it can even prevent the development of neuropathic pain.^{47,49–51}

Outcome and satisfaction

Only a few collected articles describe the shoulder's preoperative range of motion, and this description was significantly limited. Some authors attempted brachial plexus revision, neurolysis, transfer of the accessory nerve to the suprascapular nerve, or reconstruction of the suprascapular nerve with an autograft to improve shoulder function. Due to the lack of significant improvement in function after reconstructive procedures, it was decided to perform arthrodesis of the shoulder. After surgery, the range of motion was on average 59° of flexion and 55° of abduction, while some patients achieved significantly better results, at a level of 90–100° of active flexion and abduction (Fig. 2). It is much more important to assess the ability

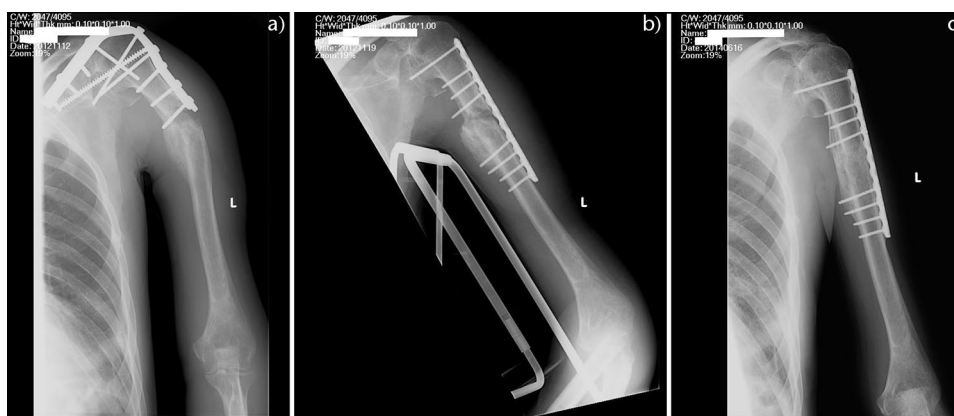

Fig. 2 Active shoulder flexion and abduction after arthrodesis.

to perform everyday activities by operated limb. After arthrodesis, reaching the operated limb to the mouth was possible for 69% of patients, to the front pocket for 71%, and to the buttock for 38%. These results were assessed, on average, five years after surgery. After the operation, the subjective satisfaction rate was 82% based on significant shoulder function improvement reported by patients.

As mentioned earlier, the type of internal fixation did not significantly affect the final patient satisfaction after surgery, although a higher percentage of satisfaction was achieved after plate stabilization than with screws. Clare et al also found that after shoulder arthrodesis, for other indications than a brachial plexus injury, patient satisfaction was equal.¹

Before surgery, it is important to evaluate the function and strength of the periscapular muscles, the trapezius, serratus anterior, and rhomboid muscles because, after glenohumeral fusion, functional motion can be retained through scapula–thoracic movement by these muscles. Their insufficiency may be associated with the treatment having an unsatisfactory outcome.^{1,11,25,29} When the brachial plexus is injured, the elbow and hand functions are also often impaired. To achieve a satisfactory final result, surgery should be considered to improve the range of elbow and hand movement and, most importantly, their stability. Their insufficiency will not allow the limb to reach the midline of the body and perform basic everyday activities, which will result in poorer treatment results and less patient satisfaction after surgery. Some authors suggest amputation of the limb above the elbow for good prosthetics, which also brings good final results.^{21,24,25}

A high percentage of satisfaction after surgery in this group of patients could be associated with obtaining a range of motion that allows the use of an injured limb to perform basic everyday activities, such as eating or personal hygiene. As a result of arthrodesis and solid bone union, the shoulder is also stable, allowing the patient to return to physical work.

Complications

Recent studies show that the incidence of all complications after shoulder arthrodesis is 28%. Early complications are less common and include surgery site infection, skin breakdown, and wound haematoma. More common are late complications, including delayed bone union, malunion, malposition, and ipsilateral humeral fractures.⁴⁸ Based on collected articles, the complication rate after shoulder arthrodesis was 26%. The type of stabilization did not have a statistically significant effect after surgery.

The most common complication was delayed or non-bone union and occurred in 9% of cases. The type of fixation did not significantly affect the incidence of this complication. Some authors suggest using free bone grafts to increase bone adherence, increasing the percentage of

a solid bone union. Atlan et al¹⁷ compared the results of a bone union in 54 patients after shoulder arthrodesis. In some of them, a cancellous graft was used, while others had a corticocancellous bone graft. The results showed that a corticocancellous graft gives a significantly higher fusion rate. In our literature analysis, some authors used free bone grafts in their technique, but it did not significantly reduce the delayed bone union rate. Methods using free vascularized fibula transfer are also described in cases with a significant loss of the humerus proximal end,^{52,53} but this situation is rare in patients with brachial plexus damage. Clare et al suggest paying particular attention to eliminating all cartilage, maximum bone coaptation, and stable positioning of all implants to achieve a solid bone union. In addition, the patient needs to quit smoking, as smoking generally increases bone nonunion.¹

The second most common complication was a fracture of the humerus and affected 6% of all cases. Rühmann et al assessed the frequency of fractures after plate stabilization to be in the range of 3% to 8%, while after screw stabilization it was 1%⁸. In our literature analysis, a fracture of the humerus after plate stabilization was at a comparable level and amounted to 5%, while a slightly higher percentage of fractures occurred after screw stabilization and amounted to 6% of all cases. All fractures occurred as a late complication several months after surgery. They can be treated conservatively by immobilization or with open reduction and plate fixation as shown in Fig. 3.

A complication that can directly affect treatment and patient satisfaction is malposition of the extremity after arthrodesis. It is most often associated with limb position in excessive flexion and abduction and external instead of internal rotation during arthrodesis. As discussed earlier, this can lead to winging of the scapula and, consequently, to a periscapular muscle strain resulting in chronic, residual shoulder pain. Besides this, excessive abduction can lead to traction neuritis on the brachial plexus, specifically on the suprascapular nerve, which also affects persistent shoulder pain after arthrodesis, but which is neurogenic. Malposition additionally causes the limb to be placed in a non-functional position, which causes difficulty with daily activities.^{1,18,48} It is necessary to perform surgery to correct the position of the limb by corrective osteotomy. Groh et al performed nine corrective osteotomies due to malposition, where the main reasons for dissatisfaction were the limitation of limb function in everyday life and chronic shoulder pain. Before surgery, patients' average limb position was at 47° of flexion, 37° of abduction and internal rotation, and patients could perform an average of three out of six assessed daily activities. To correct excessive flexion and abduction, Groh proposes a closing-wedge osteotomy, with bone wedge excision at the humerus's surgical neck level. Its size was determined based on X-ray images in the anterior-posterior (AP) and lateral positions

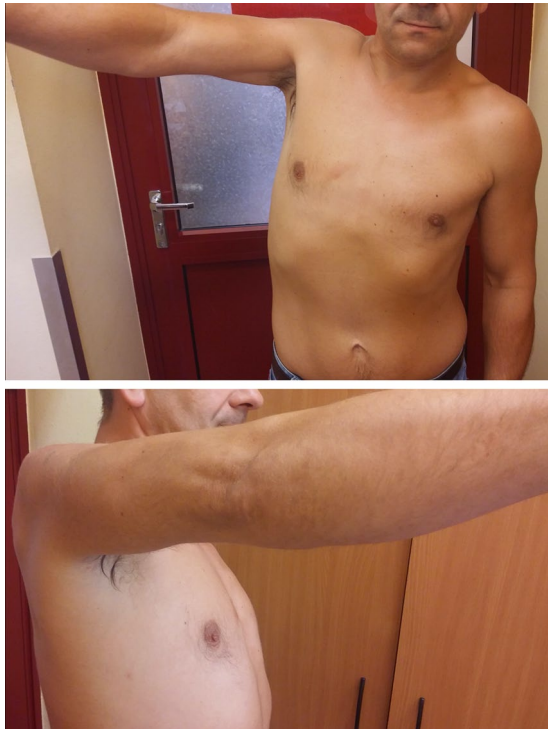

Fig. 3 Late complication after shoulder arthrodesis in the form of a fracture of the humerus distal to the plate. (A) Humerus shaft fracture, (B) open reduction and plate fixation, (C) complete humerus shaft union.

Groh et al suggest that the degree of internal rotation correction should be determined based on the patient's weight. For slim patients, he recommends setting the internal rotation to 60° and for obese patients to 40°. After surgery, the average limb position was 13° of flexion, 16° of abduction, and 48° of internal rotation, which resulted in resolution of shoulder pain in all patients, and the ability to perform all six assessed daily activities.¹⁸

In collected publications, this complication is reported in only 2% of all cases. All patients underwent a corrective osteotomy, resulting in a more favourable limb position and relief from shoulder pain.

Conclusion

Shoulder arthrodesis is a well-established, valuable surgery for extensive, irreparable brachial plexus injury in adult patients. It should be considered as an end-stage salvage procedure if other reconstructive options fail^{16,54,55}. It improves function, provides a range of motion that makes carrying out everyday activities possible, increases shoulder stability, and reduces shoulder pain. This effects a high level of subjective patient satisfaction rate after surgery.

However, the indications for this operation are limited. The selection of a specific technique is still unclear. Each has its pros and cons, but neither significantly impacts

patients' final satisfaction, so the choice should depend on the surgeon's preferences. The position of arthrodesis is still not clearly defined. The tendency is to lower the flexion and abduction angle with non-excessive internal rotation. In our opinion, the '30-30-30' position, or an analogous position, could be reasonable. The assessment of the function and strength of the periscapular muscles, the trapezius, serratus anterior, and rhomboid muscles is necessary to provide the movement of the shoulder after fusion. Patients should be informed of the significantly high risk of complication and reoperation, but in long-term observations, this does not negatively affect patient satisfaction because of the benefits obtained after arthrodesis.

The limitations of the study

Based on the collected publications, it was impossible to compare a significant parameter: the change in shoulder movement or the possibility of reaching with the hand before and after arthrodesis due to the lack of such data from the preoperative period.

AUTHOR INFORMATION

Department of Traumatology, Orthopaedics and Hand Surgery, Poznań University of Medical Sciences, Poznań, Poland.

Correspondence should be sent to: Michał Górecki ul. 28 Czerwca 1956r. nr 135/147 61-545 Poznań, Poland.

Email: michalmgorecki@gmail.com

ACKNOWLEDGEMENTS

The Association For The Development Of Hand Surgery funded a professional linguistic proofreading of this manuscript.

ICMJE CONFLICT OF INTEREST STATEMENT

The authors have no relevant financial or non-financial interests to disclose.

FUNDING STATEMENT

No benefits in any form have been received or will be received from a commercial party related directly or indirectly to the subject of this article.

OPEN ACCESS

© 2021 The author(s)

This article is distributed under the terms of the Creative Commons Attribution-Non Commercial 4.0 International (CC BY-NC 4.0) licence (<https://creativecommons.org/licenses/by-nc/4.0/>) which permits non-commercial use, reproduction and distribution of the work without further permission provided the original work is attributed.

REFERENCES

1. **Clare DJ, Wirth MA, Groh GI, Rockwood CA Jr.** Shoulder arthrodesis. *J Bone Joint Surg [Am]* 2001;83-A:593–600.
2. **Wagner ER, McLaughlin R, Sarfani S, et al.** Long-term outcomes of glenohumeral arthrodesis. *J Bone Joint Surg [Am]* 2018;100-A:598–604.
3. **González-Díaz R, Rodríguez-Merchán EC, Gilbert MS.** The role of shoulder fusion in the era of arthroplasty. *Int Orthop* 1997;21:204–209.

4. **Safran O, Iannotti JP.** Arthrodesis of the shoulder. *J Am Acad Orthop Surg* 2006;14:145–153.
5. **Diaz JA, Cohen SB, Warren RF, Craig EV, Allen AA.** Arthrodesis as a salvage procedure for recurrent instability of the shoulder. *J Shoulder Elbow Surg* 2003;12:237–241.
6. **Thangarajah T, Higgs D, Bayley JIL, Lambert SM.** Glenohumeral arthrodesis for recurrent types II and III shoulder instability. *J Shoulder Elbow Surg* 2017;26:687–691.
7. **Cofield RH.** Shoulder arthrodesis and resection arthroplasty. *Instr Course Lect* 1985;34:268–277.
8. **Rühmann O, Schmolke S, Bohnsack M, Flamme C, Wirth CJ.** Shoulder arthrodesis: indications, technique, results, and complications. *J Shoulder Elbow Surg* 2005;14:38–50.
9. **Chammas M, Goubier JN, Coulet B, Reckendorf GMZ, Picot MC, Allieu Y.** Glenohumeral arthrodesis in upper and total brachial plexus palsy: a comparison of functional results. *J Bone Joint Surg [Br]* 2004;86-B:692–695.
10. **Wieser K, Modaresi K, Seeli F, Fuchs B.** Autologous double-barrel vascularized fibula bone graft for arthrodesis of the shoulder after tumor resection. *Arch Orthop Trauma Surg* 2013;133:1219–1224.
11. **Vastamäki M.** Shoulder arthrodesis for paralysis and arthrosis. *Acta Orthop Scand* 1987;58:549–553.
12. **Rybka V, Raunio P, Vainio K.** Arthrodesis of the shoulder in rheumatoid arthritis: a review of forty-one cases. *J Bone Joint Surg [Br]* 1979;61-B:155–158.
13. **Zeman CA, Arcand MA, Cantrell JS, Skedros JG, Burkhead WZ Jr.** The rotator cuff-deficient arthritic shoulder: diagnosis and surgical management. *J Am Acad Orthop Surg* 1998;6:337–348.
14. **Jouve J-L, Bollini G, Legre R, et al.** Shoulder arthrodesis. In: Bentley G, ed. *European surgical orthopaedics and traumatology: the EFORT textbook*. Berlin, Heidelberg: Springer, 2014:1201–1215.
15. **Trumble T, Budoff J, Cornwall R.** *Ręka, łokieć, ramię*. Wrocław: Elsevier Urban & Partner, 2010.
16. **Czarnecki P.** Brachial plexus injury: assessment and treatment. *Issue Rehabil Orthop Neurophysiol Sport Promot* 2016;14:45–52.
17. **Atlan F, Durand S, Fox M, Lévy P, Belkheyar Z, Oberlin C.** Functional outcome of glenohumeral fusion in brachial plexus palsy: a report of 54 cases. *J Hand Surg Am* 2012;37:683–688.
18. **Groh GI, Williams GR, Jarman RN, Rockwood CA Jr.** Treatment of complications of shoulder arthrodesis. *J Bone Joint Surg Am* 1997;79:881–887.
19. **Liberati A, Altman DG, Tetzlaff J, et al.** The PRISMA statement for reporting systematic reviews and meta-analyses of studies that evaluate health care interventions: explanation and elaboration. *PLoS Med* 2009;6:e1000100.
20. **Rühmann O, Schmolke S, Bohnsack M, Flamme C, Wirth CJ.** Shoulder arthrodesis: indications, technique, results, and complications. *J Shoulder Elbow Surg* 2005;14:38–50.
21. **Cofield RH, Briggs BT.** Glenohumeral arthrodesis: operative and long-term functional results. *J Bone Joint Surg Am* 1979;61:668–677.
22. **Ivalde FC, Bataglia D, Nizzo G, Melo M, Socolovsky M, Nizzo G.** Arthrodesis of the shoulder in patients with posttraumatic brachial plexus palsy: functional outcome and complications. *Int J Adv Jt Reconstr* 2017;4:14–18.
23. **Lenoir H, Williams T, Griffart A, et al.** Arthroscopic arthrodesis of the shoulder in brachial plexus palsy. *J Shoulder Elbow Surg* 2017;26:e115–e121.
24. **Richards RR, Waddell JP, Hudson AR.** Shoulder arthrodesis for the treatment of brachial plexus palsy. *Clin Orthop Relat Res* 1985;198:250–258.
25. **Rouholamin E, Wootton JR, Jamieson AM.** Arthrodesis of the shoulder following brachial plexus injury. *Injury* 1991;22:271–274.
26. **Rühmann O, Gossé F, Wirth CJ, Schmolke S.** Reconstructive operations for the paralyzed shoulder in brachial plexus palsy: concept of treatment. *Injury* 1999;30:609–618.
27. **Sousa R, Pereira A, Massada M, Trigueiros M, Lemos R, Silva C.** Shoulder arthrodesis in adult brachial plexus injury: what is the optimal position? *J Hand Surg Eur Vol* 2011;36:541–547.
28. **Thangarajah T, Lambert SM.** Glenohumeral arthrodesis for late reconstruction of flail shoulder in patients with traumatic supraclavicular brachial plexus palsy. *Shoulder Elbow* 2017;9:266–271.
29. **van der Lingen MAJ, de Joode SGJ, Schotanus MGM, et al.** Satisfied patients after shoulder arthrodesis for brachial plexus lesions even after 20 years of follow-up. *Eur J Orthop Surg Traumatol* 2018;28:1089–1094.
30. **Thangarajah T, Lambert SM.** Glenohumeral arthrodesis for late reconstruction of flail shoulder in patients with traumatic supraclavicular brachial plexus palsy. *Shoulder Elbow* 2017;9:266–271.
31. **Chammas M, Goubier J-N, Coulet B, Reckendorf GM, Picot MC, Allieu Y.** Glenohumeral arthrodesis in upper and total brachial plexus palsy: a comparison of functional results. *J Bone Joint Surg [Br]* 2004;86-B:692–695.
32. **Richards RR, Beaton D, Hudson AR.** Shoulder arthrodesis with plate fixation: functional outcome analysis. *J Shoulder Elbow Surg* 1993;2:225–239.
33. **Rühmann O, Schmolke S, Bohnsack M, Flamme C, Wirth CJ.** Shoulder arthrodesis: indications, technique, results, and complications. *J Shoulder Elbow Surg* 2005;14:38–50.
34. **Boonstra AM, Stewart RE, Köke AJA, et al.** Cut-off points for mild, moderate, and severe pain on the numeric rating scale for pain in patients with chronic musculoskeletal pain: variability and influence of sex and catastrophizing. *Front Psychol* 2016;7:1466.
35. **Muller M, Allgower M, Schneider R, Willenegger H.** *Manual of internal fixation: technique recommended by the AO-Group*. Second ed. New York: Springer, 1979.
36. **Richards RR, Sherman RM, Hudson AR, Waddell JP.** Shoulder arthrodesis using a pelvic-reconstruction plate: a report of eleven cases. *J Bone Joint Surg [Am]* 1988;70-A:416–421.
37. **Hawkins RJ, Neer CS II.** A functional analysis of shoulder fusions. *Clin Orthop Relat Res* 1987;223:65–76.
38. **Johnson CA, Healy WL, Brooker AF Jr, Krackow KA.** External fixation shoulder arthrodesis. *Clin Orthop Relat Res* 1986;211:219–223.
39. **Kociałkowski A, Wallace WA.** Shoulder arthrodesis using an external fixator. *J Bone Joint Surg [Br]* 1991;73-B:180–181.
40. **Porcellini G, Savoie FH III, Campi F, Merolla G, Paladini P.** Arthroscopically assisted shoulder arthrodesis: is it an effective technique? *Arthroscopy* 2014;30:1550–1556.
41. **Barr J, Freiberg J, Colonna P, Pemberton P.** A survey of end results on stabilization of the paralytic shoulder: report of the Research Committee of the American Orthopaedic Association. *J Bone Joint Surg [Am]* 1942;24:699–707.
42. **Rowe CR.** Re-evaluation of the position of the arm in arthrodesis of the shoulder in the adult. *J Bone Joint Surg Am* 1974;56:913–922.

43. **Jonsson E, Lidgren L, Rydholm U.** Position of shoulder arthrodesis measured with moiré photography. *Clin Orthop Relat Res* 1989;238:117–121.
44. **Lovaglio AC, Socolovsky M, Di Masi G, Bonilla G.** Treatment of neuropathic pain after peripheral nerve and brachial plexus traumatic injury. *Neurol India* 2019;67: S32–S37.
45. **Hou A-L, Xu W-D.** A model of neuropathic pain in brachial plexus avulsion injury and associated spinal glial cell activation. *J Pain Res* 2018;11:3171–3179.
46. **Saiz-Sapena N, Vanaclocha-Vanaclocha V, Ortiz-Criado JM, Vanaclocha L, Vanaclocha N.** Treatment of neuropathic pain in brachial plexus injuries. *Treat Brachial Plex Inj* 2019. <https://www.intechopen.com/books/treatment-of-brachial-plexus-injuries/treatment-of-neuropathic-pain-in-brachial-plexus-injuries> (date last accessed 15 June 2020).
47. **Parry CB.** Pain in avulsion of the brachial plexus. *Neurosurg* 1984;15:960–965.
48. **Throckmorton TW.** Arthrodesis of the shoulder and elbow. In: Canale ST, Beaty JH *Campbell's operative orthopaedics*. Volume I. Twelfth ed. Philadelphia, PA: Elsevier, Inc, 2013:83–596.
49. **DeSantana JM, Walsh DM, Vance C, Raket BA, Sluka KA.** Effectiveness of transcutaneous electrical nerve stimulation for treatment of hyperalgesia and pain. *Curr Rheumatol Rep* 2008;10:492–499.
50. **Chakravarthy K, Nava A, Christo PJ, Williams K.** Review of recent advances in peripheral nerve stimulation (PNS). *Curr Pain Headache Rep* 2016;20:60.
51. **Goroszeniuk T, Pang D.** Peripheral neuromodulation: a review. *Curr Pain Headache Rep* 2014;18:412.
52. **Viehweger E, Gonzalez J-F, Launay F, Legre R, Jouve JL, Bollini G.** Shoulder arthrodesis with vascularized fibular graft after tumor resection of the proximal humerus. *Rev Chir Orthop Repar Appar Mot* 2005;91:523–529.
53. **Scalise JJ, Iannotti JP.** Glenohumeral arthrodesis after failed prosthetic shoulder arthroplasty: surgical technique. *J Bone Joint Surg [Am]* 2009;91-A:30–37.
54. **Boyd AD Jr, Thornhill TS.** Surgical treatment of osteoarthritis of the shoulder. *Rheum Dis Clin North Am* 1988;14:591–611.
55. **Gill TJ, Warren RF, Rockwood CA Jr, Craig EV, Cofield RH, Hawkins RJ.** Complications of shoulder surgery. *Instr Course Lect* 1999;48:359–374.