



# Acute osteoarticular infections in children are frequently forgotten multidiscipline emergencies: beyond the technical skills

Tamer El-Sobky  
Shady Mahmoud

- Acute osteoarticular infections (AOI) should be treated as top emergencies. The first few days following the inception of infection are ultra-critical to long-term prognosis.
- A comprehensive road map for management of childhood AOI is still lacking despite recent advances in microbiology and imaging (magnetic resonance imaging). The many faces of childhood AOI warrant a multidiscipline approach to management.
- Laboratory and imaging findings of are still debatable and should not overshadow or delay a management plan based on the experienced physician's clinical judgment.
- Ample evidence-based practice supports the use of a few days of intravenous antibiotic administration followed by oral therapy until correlative clinical and basic laboratory (acute phase reactants) results improve.
- The growing body of evidence on 'high-risk' children/neonates of AOI warrants continual clinical extra-vigilance in identifying these patient subsets.
- Open drainage and debridement remain the mainstay of treatment of septic hips, whereas for other joints the use of alternative surgical techniques should be individualized or on case-by-case basis.
- Because the consequences of misdiagnosis of AOI are usually grave and permanent, proactive treatment/over-treatment is justified in the event of unconfirmed but suspicious diagnosis.

**Keywords:** acute pyogenic osteomyelitis; paediatric musculoskeletal infection; childhood suppurative arthritis; referral / consultation; non-technical skills

Cite this article: *EFORT Open Rev* 2021;6:584-592.  
DOI: 10.1302/2058-5241.6.200155

Septic arthritis and acute haematogenous osteomyelitis are frequently encountered among otherwise healthy children

and adolescents. Misdiagnosis may increase the likelihood of bone and joint complications. The slightest delay in appropriate management can lead to serious and permanent musculoskeletal morbidities such as joint destruction, dislocation and physal growth arrest. Childhood septic arthritis and acute haematogenous osteomyelitis are thus regarded as top paediatric emergencies. The objective of this concise update is to unravel the diagnostic challenges and management controversies of septic arthritis and acute hematogenous osteomyelitis in the paediatric population. And to highlight the factors responsible for poor outcomes in real-time clinical scenarios, both technical and non-technical. The differential diagnostic utility of magnetic resonance imaging has made advances. The clinical utility of laboratory acute phase reactants, synovial fluid analysis/polymerase chain reaction (PCR) and blood cultures has been demonstrated in emerging evidence. However, results of imaging and laboratory investigations should not overshadow the experienced physician's clinical judgment, as their diagnostic utility is still debatable. An early transition from intravenous to oral antibiotic administration is currently a well-grounded practice. The growing clinical and microbiologic body of evidence on 'high-risk' children/neonates of acute osteoarticular infections warrants continual clinical extra-vigilance in identifying these patient subsets. Because of the irreversibly severe consequences of misdiagnosis, proactive treatment, or 'overtreatment', in clinically suspicious cases remains a valid strategy. Inadequate healthcare referral systems in regard to the generalist–specialist communication process are a potential source of delayed referral to the specialist and subsequent poor outcomes, particularly in emergency settings. Raising healthcare personnel's awareness of the importance of interdisciplinary communication and concentrating the focus of future research on the efficiency of healthcare referral systems in low-resource countries is recommended.

## Introduction

Acute osteoarticular infections (AOI), namely bacterial acute hematogenous osteomyelitis and septic arthritis, are not uncommon in the paediatric population, with variations in annual hospitalization rates ranging from 1.34 to 82 per 100,000.<sup>1–4</sup> Recent reports have shown an uptrend in the prevalence of surgically treated septic arthritis of the hip and knee.<sup>5,6</sup> Hematogenous and/or spread from adjacent anatomic focus are the common modes of acquiring sepsis, with *Staphylococcus aureus* infections being the most common.<sup>1,7–9</sup> This is unlike fungal osteomyelitis, where the route of infection is basically exogenous.<sup>10</sup> Developing countries and impoverished populations of the developed world tend to have higher disease burden in terms of both incidence and severity of complications.<sup>2,11,12</sup>

Paediatric AOI have a strong predilection in favour of large joints such as the hip, knee and shoulder, and/or their adjacent metaphyses.<sup>3,4,7,13,14</sup> The differential diagnosis of AOI is broad and multifaceted. The clinical picture of septic arthritis of the hip and osteomyelitis of the proximal femur overlap in various aspects. Clinical and laboratory features of transient synovitis of the hip should be taken into account in the differential diagnosis of septic arthritis of the hip. Additionally, osteomyelitis and bone malignancies overlap in terms of radioclinical features.<sup>15,16</sup> The fact that AOI may be associated with extra-skeletal manifestations such as pyomyositis compounds the diagnostic challenges.<sup>17</sup> Misdiagnosis, delayed diagnosis and consequent delay in institution of definitive treatment, late presentation, poor compliance with antibiotic regimes, high organism virulence and positive findings on joint ultrasound predict a poor long-term prognosis.<sup>2,7,9,12,18–20</sup> Empiric antibiotic therapy with or without surgical drainage and debridement are the goal standard for treatment.<sup>7,9</sup> Significant controversies exist as to the diagnostic role of acute phase reactants, synovial fluid analysis and culture, antimicrobial regimes and techniques of surgical drainage.<sup>7,9,13,18</sup>

Our review will be restricted to appendicular pyogenic non-specific osteoarticular infections. The objective of this study is to highlight the updates on recent approaches to diagnosis and management of childhood AOI. And investigate the available body of evidence for the current treatment algorithms.

## Non-technical precipitating factors

AOI in children are frequently encountered by neonatologists, general paediatricians, family or primary care physicians, emergency department physicians, radiologists and orthopaedic surgeons. In low-resource settings or remote areas of high-income countries, healthcare workers and

physician assistants may be the first to make initial contact with the child suffering from an AOI. Unsurprisingly, these healthcare providers are usually not equipped with the necessary medical knowledge and skills that allow them to diagnose or suspect and immediately and appropriately respond to such a serious paediatric emergency.<sup>21,22</sup> The problem of AOI in children lies in the fact that delayed diagnosis and treatment is usually associated with irreparable bone and joint destruction that, in some instances, may result in lifelong disability and severe gait impairment. The window period for surgical intervention, namely drainage of the septic hip, is therefore extremely critical and time sensitive. This is because the ultimate prognosis is highly dependent upon this golden but very narrow window of opportunity from inception of the suppurative infection and symptomatology to the surgical drainage and elimination of the threat of irreparable articular cartilage destruction by enzymes released by polymorphonuclear leukocytes and lysosomal enzymes from the synovial membrane. The above-mentioned diagnostic difficulties of childhood AOI, especially in neonates, the severe long-term sequels of untimely institution of treatment and the current controversies in management, all call for a well-orchestrated and efficient healthcare referral system and generalist–specialist interdisciplinary communication. If this ultra-critical window of opportunity is not seized efficiently by timely referral to the orthopaedic surgeon, it will put the child at risk of severe and lifelong functional disability.<sup>21–25</sup> In real-time clinical practice settings in remote areas and in some developing countries, patients are prone to experience long delays until they meet the end-care provider, namely the orthopaedic surgeon. A defective healthcare referral system and a disorganized generalist–specialist communication may in part be responsible for such management delays and can thus be considered as important potential contributors to poor patient outcomes for AOI, especially in low-resource countries.<sup>21,22,24</sup>

## Diagnostic challenges

The diagnosis of childhood septic arthritis and acute hematogenous osteomyelitis is fundamentally a clinical one. However, fever may be absent and local signs of infection may pose diagnostic difficulties in deep joints like the hip, in contrast to the knee and the subcutaneous proximal tibia, where local signs of infection are readily evident clinically.<sup>5,18,26</sup> Childhood pyomyositis, occurring either in isolation or in association with AOI, can further complicate the diagnostic process because of its nearly identical clinical and biochemical presentation.<sup>17,23</sup> Non-weight-bearing and pseudoparalysis in neonates and young children is the chief cornerstone of the diagnosis.<sup>19,27</sup> Plain radiograph abnormalities are

usually absent or inconclusive in the acute setting. And acute phase reactants – CRP, ESR and procalcitonin – and blood cultures are an important supplement to the clinical picture. Developmental immaturity of the immune system, variations in specificity and sensitivity values of each reactant across studies, type and virulence of causative microorganism, type of joint – hip versus knee – and previous antibiotic intake may alter their diagnostic utility.<sup>5,18,28–36</sup> Nonetheless, a recent study suggested that synovial fluid cell count of polymorphonuclear leukocyte is not influenced by intake of antibiotics prior to aspiration of various joints.<sup>37</sup> Another reported excellent positive and negative predictive values of leukocyte esterase strip test on synovial fluid to aid the diagnosis of septic arthritis in children.<sup>38</sup> These findings work to enhance the diagnostic utility of synovial fluid analysis. AOI in children may closely mimic skeletal trauma because it is not uncommon to recall a history of trauma in children presenting with AOI.<sup>17</sup> Confusingly, physeal separation may co-occur with acute haematogenous osteomyelitis without prior history of trauma, especially in neonates and infants.<sup>39</sup> The fact that some toddlers can walk with a limp in spite of suffering long bone fissure fractures further compounds the diagnostic challenge. Acute/subacute haematogenous osteomyelitis in children bears a misleading clinical and radiological similarity to various bone tumours, most importantly Ewing's sarcoma and osteosarcoma.<sup>15,40,41</sup> Acute haematogenous osteomyelitis must be ruled out before arriving at the diagnosis of bone contusion or fracture. Conversely, Ewing's sarcoma must be ruled out before reaching the diagnosis of subacute haematogenous osteomyelitis. The occasional coexistence of septic arthritis and acute haematogenous osteomyelitis is another source of diagnostic complexity. This is particularly problematic and common in joints where the metaphysis is wholly or partly intra-articular. Typical and common examples are the hip and the shoulder,<sup>6,14,42–45</sup> and elbow.<sup>46,47</sup> Typically, AOI occur in children and adolescents who are who present with no co-occurring health problems.<sup>1–4</sup> Nevertheless, patients with renal osteodystrophy, haematologic disorders, those receiving regular steroid therapy, acute lymphoblastic leukaemia and juvenile diabetes are considered at high risk for developing AOI.<sup>48,49</sup> Therefore, in the event of acute musculoskeletal symptomatology, acute septic arthritis and haematogenous osteomyelitis should top the list of differential diagnosis.

Transient synovitis of the hip – a non-septic inflammation – is a frequent cause of a painful limp in young children. It usually runs a self-limiting course without residual joint damage. Mismanaged AOI carry a contrastingly high risk for permanent joint damage. Thus, although these disorders have diverse prognoses, they can occasionally overlap both clinically and biochemically. Again as noted above, non-weight-bearing and a CRP > 20 mg/l are useful

tools to exclude transient hip synovitis. Surprisingly, children with transient synovitis of the hip usually maintain a fair level of daily activities, in remarkable contrast to those with established AOI.<sup>19,27,28,48</sup> A misdiagnosis of AOI for transient synovitis of the hip could result in failure to institute a timely management plan with subsequent lifelong disabling sequels.<sup>18,25</sup> Scurvy is a rare nutritional disorder caused by longstanding vitamin C deficiency. It is likely underdiagnosed rather than rare. Interestingly, scurvy can exhibit a deceptive radioclinical resemblance to septic arthritis and acute hematogenous osteomyelitis.<sup>50–52</sup> Systematic history-taking, a comprehensive clinical examination and knowledge of characteristic, though not universal, radiographic pattern of involvement and keeping a high level of clinical suspicion in children with underlying risk factors such as autism and developmental delay is helpful in arriving at a diagnosis. Serum ascorbic acid level can confirm the diagnosis but may be within normal range in early disease stages.<sup>51,52</sup>

#### *Role of musculoskeletal magnetic resonance imaging (MRI)*

Musculoskeletal MRI can be beneficial in the decision-making process through confirming the clinical suspicion of AOI, differentiating between isolated septic arthritis versus coexistent adjacent osteomyelitis and vice versa, revealing clinically undetectable multiple foci of sepsis, identifying extra-osseous affection and suggesting a different diagnosis, particularly the extended field of view and detailing concurrent epiphyseal slips.<sup>16,39,44,53,54</sup> MRI, especially fat-suppressed, fluid-sensitive sequences, has been found to be helpful in differentiating AOI from transient synovitis of the hip<sup>16</sup> and Ewing's sarcoma.<sup>13,55</sup> The presence of a soft tissue mass and the nature of the transition are critical to the diagnosis of Ewing's sarcoma.<sup>15</sup> However, MRI findings should be interpreted with caution as they are not pathognomonic.<sup>15,16,55</sup>

Similarly, fat-suppressed, fluid-sensitive sequences and fat-suppressed, contrast-enhanced sequences of MRI can be used to clearly identify the pathologic components and multiplicity of childhood pyomyositis, to exclude or confirm the co-occurrence of acute haematogenous osteomyelitis of the proximal femur or septic arthritis of the hip.<sup>17,23,29</sup> Emerging reports indicate that MRI may be useful in differentiating scurvy from the overlapping diseases including AOI and malignancies.<sup>50,51,53,56</sup> However, the practicality of MRI as a clinical tool and availability and accessibility in emergency settings is questionable. MRI findings should be interpreted with caution and in view of accurate clinical, imaging and laboratory correlations. Hip ultrasound is an ionizing radiation-free and non-invasive tool that can aid in diagnosis, guide interventions such as joint/subperiosteal abscess aspiration and the need for MRI.<sup>32,57</sup> The diagnostic and treatment pitfalls are shown in Fig. 1.

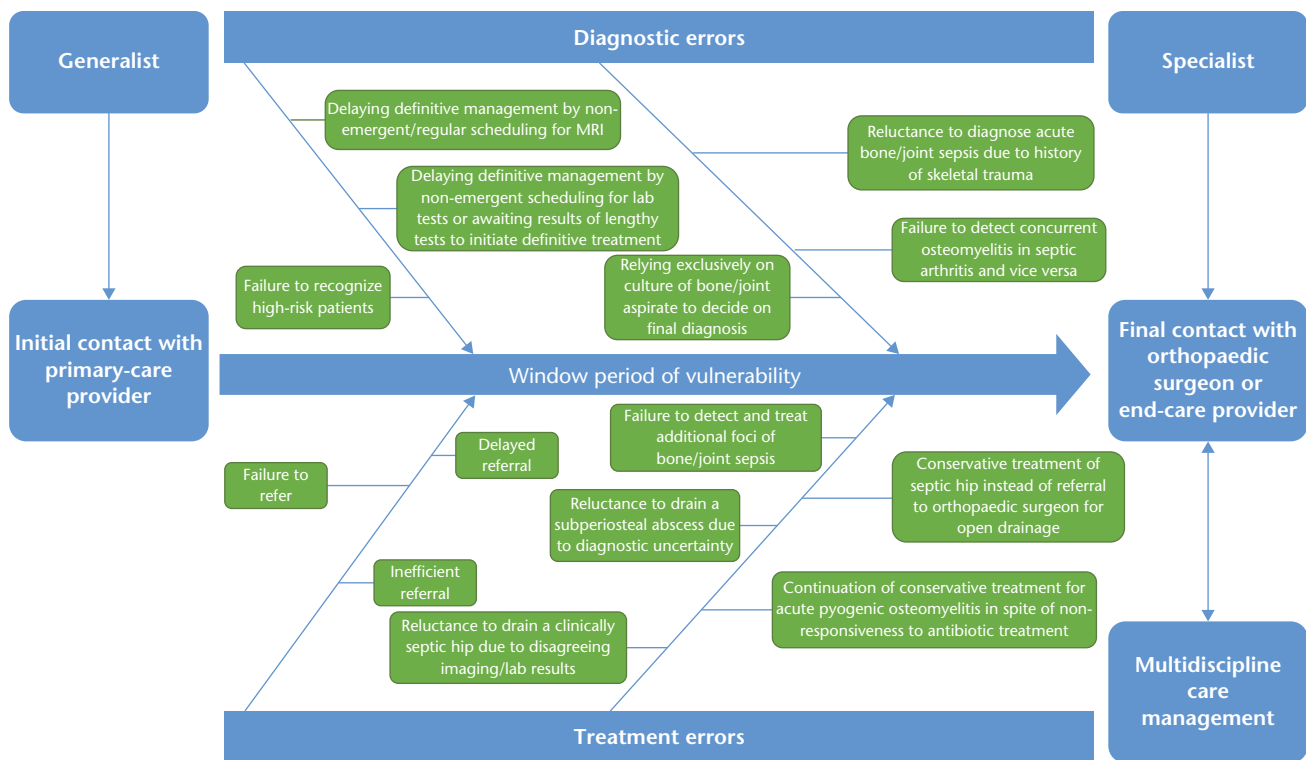


Fig. 1 Serious clinical scenarios precipitating complications.

### Neonatal septic arthritis and acute haematogenous osteomyelitis

Neonatal and infantile AOI should be recognized as clinically distinct from those occurring during childhood.<sup>7</sup> Neonates and toddlers account for most AOI in children and adolescents below 15 years of age.<sup>58</sup> Septic arthritis tends to be more common than osteomyelitis in this age group.<sup>31,44</sup> Of this already vulnerable subset, incubated, ventilated, preterm new-borns, those with anaemia and those who have undergone invasive procedures/catheterizations are more prone to acquire AOI.<sup>34,59–61</sup> The constitutional manifestations of infection may be lacking, and the total leucocyte count and acute phase reactants are not reliable diagnostic clues in neonates due to developmental immaturity. Normal leucocyte count or even leukopenia and to a lesser extent normal CRP and ESR can co-occur with AOI.<sup>18,32,33,61,62</sup> Contrastingly, failure to localize origin of fever and to grow a causative pathogen in culture and sensitivity from joint aspirate is not uncommon.<sup>7</sup> The objective local clinical data are difficult to elicit in deep joints such as the hip. In neonatal AOI there is a tendency to involve multiple bone and joint foci, to physal/epiphyseal destruction and joint dislocation.<sup>39,60</sup> The degree of limitation of active/reflex limb motion – pseudo-paralysis – with the contralateral side as a comparator, is a very useful but often overlooked clinical tool to establish the diagnosis. This can also be obtained from meticulous

history-taking.<sup>19,27,28</sup> Given all the diagnostic challenges, a high level of suspicion of AOI should be maintained when attending such patient subsets.

### Management controversies

#### Acute haematogenous osteomyelitis versus septic arthritis

Considering the devastating consequences of neglected or mismanaged AOI in children, immediate and urgent institution of treatment is crucial to the final outcome. In acute haematogenous osteomyelitis, empirical antibiotics are considered to be the first-line management.<sup>8,9,63</sup> Surgical drainage and bone drilling may be urgently required in the event that a subperiosteal or intramedullary abscess has formed. Additionally, surgical drainage may be urgently required if the patient is clinically and laboratory non-responsive within two days of a timely instituted antibiotic protocol.<sup>64,65</sup> Failure to seize this window of opportunity to abort the suppurative process is an all-important cause of chronicity and lifelong disabling sequelae.<sup>11,25,64</sup>

In acute septic arthritis in children, open surgical drainage or arthrotomy from the start is the mainstay of treatment, at least for the hip joint and shoulder joints.<sup>5,65,66</sup> Arthroscopic and open drainage of the septic hip have been shown to be equally successful in early presenting cases.<sup>66</sup> However, arthroscopic drainage, a technically demanding procedure, did not involve neonates, toddlers and delayed

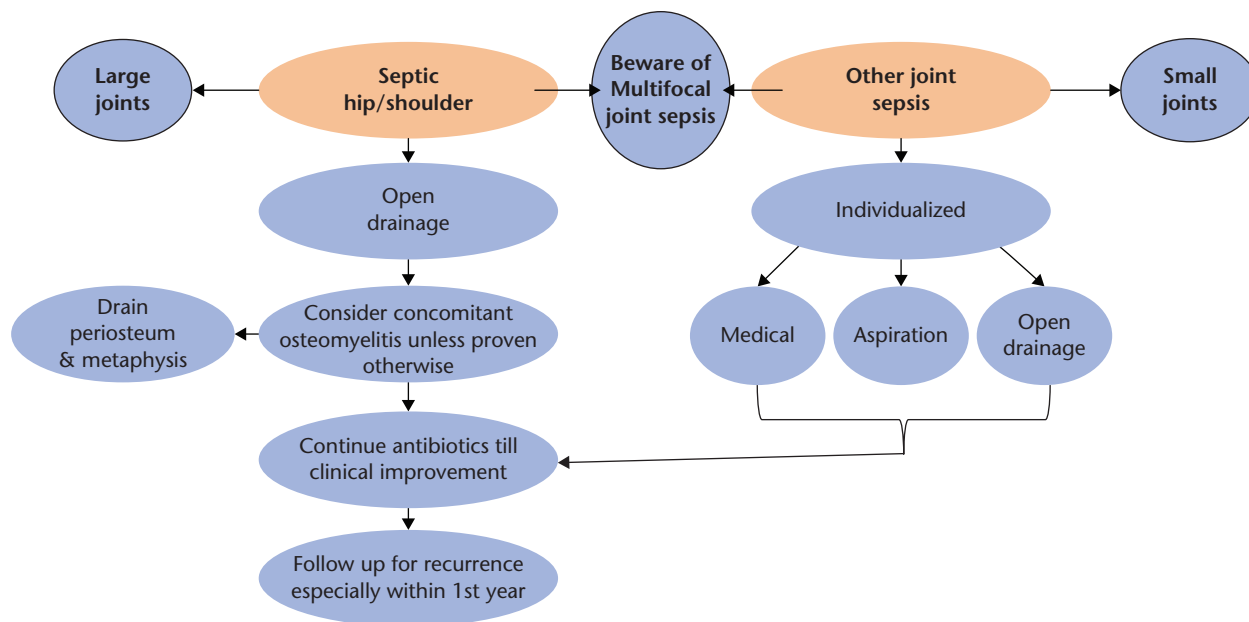


Fig. 2 Management algorithm for septic arthritis in children.

presenting cases.<sup>66</sup> Although repeated ultrasound-guided joint aspiration under appropriate antibiotic coverage has been reported, there is no clear consensus on its use on a routine basis because the patient and disease predictors of success are not yet clearly defined.<sup>63,66–69</sup> Nevertheless, joint aspiration may be justifiable in smaller joints other than the hip and shoulder.<sup>65</sup> The management guidelines for acute haematogenous osteomyelitis are equally applicable to childhood pyomyositis.<sup>17,30</sup> The use of steroid therapy as an adjunctive to antibiotic therapy in septic arthritis can shorten the overall treatment period and time needed for CRP to normalize. However, steroids should not be used as a substitute for antibiotic therapy.<sup>12,68</sup> Management algorithms for AOI are shown in Fig. 2 and Fig. 3.

#### Antibiotic controversies

Antibiotics are an integral pillar of any management plan involving AOI in children. Antibiotics covering methicillin-resistant *Staphylococcus aureus* infections are usually the first choice, such as intravenous vancomycin at a dose of 15 mg/kg/dose every six hours in severe infections with bacteraemia.<sup>9,62</sup> Clindamycin at a dose of 40 mg/kg/day and  $\beta$ -lactams, such as intravenous cefazolin and oral cephalixin can be used as a substitute in milder infections such as those caused by methicillin-susceptible/sensitive *Staphylococcus aureus*. These antibiotics may be used empirically if the microbiological epidemiologic profile favours methicillin-susceptible/sensitive *Staphylococcus aureus*.<sup>8,9,12,14,60,62</sup> *Kingella kingae* – a Gram-negative organism – is another notable but more indolent source of acute infections. The recent use of molecular diagnosis with 16S rRNA gene polymerase chain reaction

(PCR) and sequencing in synovial fluid has improved its detectability.<sup>8,29,32,33,35,69</sup> Unfortunately, vancomycin-resistant *Staphylococcus aureus* (VRSA) infections are emerging. Typically, AOI in children caused by VRSA require higher minimal inhibitory concentrations of vancomycin to achieve clinical improvement. This strategy may be associated with higher risk of nephrotoxicity.<sup>62,70</sup> Therefore, in the event of poor clinical and microbiologic response to vancomycin-treated AOI, a VRSA strain should be suspected and a paediatric infectious disease specialist must be consulted. Ceftaroline is an advanced-generation cephalosporin that has proven effective in treatment of methicillin-resistant *Staphylococcus aureus* bacteraemia, and should be used as a last-resort treatment.<sup>9,70–72</sup> Yet, further research is required to validate its role in the treatment of AOI in children. Highly virulent strains such as community-associated Pantón–Valentine leukocidin-producing MRSA strains can result in more intense orthopaedic complications and longer durations of antibiotic administration.<sup>30,34,62,70</sup> Occasionally Gram-negative organisms such as *Kingella kingae* are the causative agents, especially in neonates, casting doubt on the clinical utility of Gram stain of joint aspirates.<sup>8,29,32,33,58,60,73</sup> Similarly, the lack of rapidly available results from conventional PCR done for commonly encountered pathogens in joint fluid aspirate limits the clinical utility and practicality of current PCR techniques.<sup>74</sup> There has been disagreement in the literature about the route of administration, duration, number and type of antibiotics needed to treat AOI. Traditionally, antibiotics have been administered for several months including at least 4–6 weeks intravenously.<sup>62</sup> Currently, there is a tendency to adopt more conservative

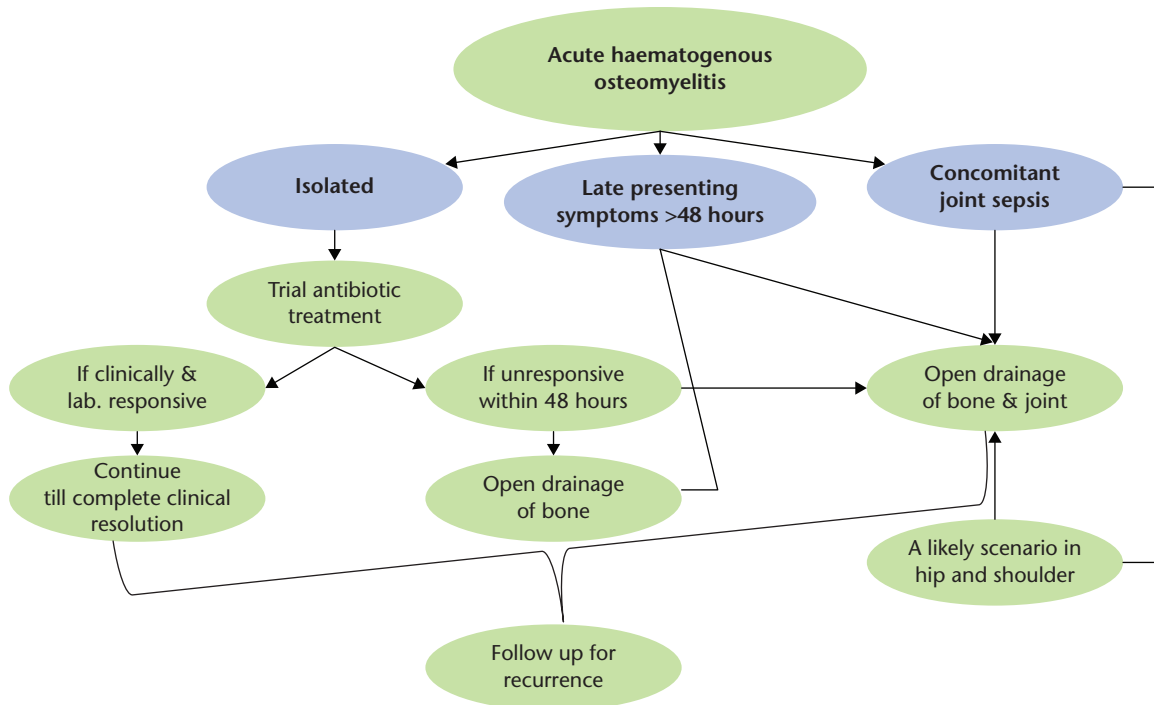


Fig. 3 Management algorithm for acute haematogenous osteomyelitis in children.

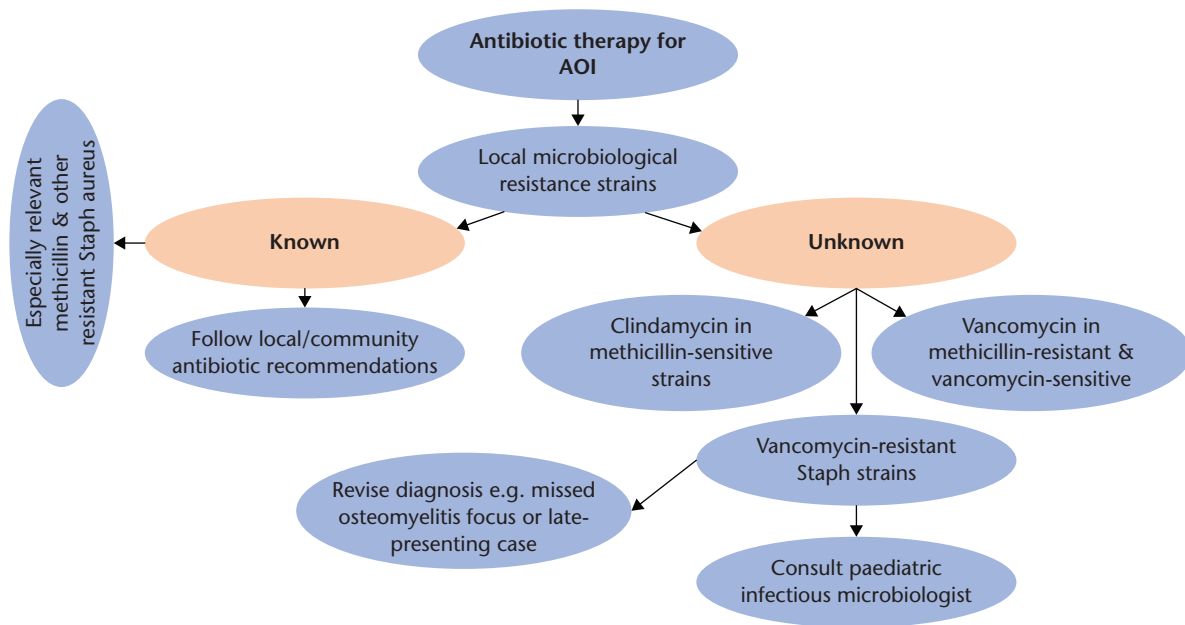


Fig. 4 Management algorithm for antibiotic therapy in acute osteoarticular infections in children.

antibiotic regimens in favour of shorter periods of intravenous administration – three to five days – and hospitalization, and relatively longer periods of oral administration of a single antibiotic with an overall shorter treatment period.<sup>2,8,62,63,75</sup> The duration of antibiotic administration is dictated by the objective general and local signs of

clinical improvement and the normalization of CRP.<sup>36,48,64</sup> Monitoring responsiveness to antibiotics by ESR in spite of clinical improvement can lead to an unduly long treatment period and potential antibiotic toxicity.<sup>36,66</sup> A management algorithm for antibiotic therapy in AOI is shown in Fig. 4.

## Conclusions

Given the serious and irreversible consequences of delayed management of AOI, the importance of timely institution of treatment cannot be overemphasized. AOI in children remains essentially a clinical diagnosis. The recent advances in use of musculoskeletal imaging/MRI and laboratory/microbiologic workup should be viewed as an adjunct to the clinical diagnosis only. In the event of disagreement, findings from these sources should not override the experienced physician's clinical judgment. Delaying the definitive management plan until the imaging and/or laboratory results have appeared increases the risk of children's musculoskeletal morbidity. For example, reluctance to operate on a suspicious septic hip may later cause lifelong morbidity, while draining a hip which later proves to be non-septic is generally risk-free. The practice of initial intravenous antibiotic administration with early transition to oral therapy has replaced the time-honoured and currently unjustifiable practice of lengthy courses of predominantly intravenous antibiotics.

## Recommendations

Regional epidemiological studies of microbiological profiles of childhood AOI can better inform antibiotic treatment protocols. A well-established healthcare referral system and efficient generalist–specialist communication have the potential to improve patients' outcomes in emergency settings. This is particularly relevant to countries with poor healthcare infrastructure.

### AUTHOR INFORMATION

Division of Paediatric Orthopaedics, Department of Orthopaedic Surgery, Faculty of Medicine, Ain Shams University, Cairo, Egypt.

Correspondence should be sent to: Shady Mahmoud MD, Lecturer of Orthopaedic Surgery, Division of Paediatric Orthopaedics, Department of Orthopaedic Surgery, Faculty of Medicine, Ain Shams University, Cairo, Egypt.  
Email: dr.shadi87@hotmail.com

### ICMJE CONFLICT OF INTEREST STATEMENT

The authors declare no conflict of interest relevant to this work.

### FUNDING STATEMENT

No benefits in any form have been received or will be received from a commercial party related directly or indirectly to the subject of this article.

### SOCIAL MEDIA

Twitter: @SobkyTamer  
LinkedIn: Tamer El-Sobky

### OPEN ACCESS

© 2021 The author(s)

This article is distributed under the terms of the Creative Commons Attribution-Non Commercial 4.0 International (CC BY-NC 4.0) licence (<https://creativecommons.org/licenses/by-nc/4.0/>)

licenses/by-nc/4.0/) which permits non-commercial use, reproduction and distribution of the work without further permission provided the original work is attributed.

### REFERENCES

1. Mitha A, Boutry N, Nectoux E, et al; Hospital Network for Evaluating the Management of Infectious Diseases in Children. Community-acquired bone and joint infections in children: a 1-year prospective epidemiological study. *Arch Dis Child* 2015;100:126–129.
2. Brischetto A, Leung G, Marshall CS, Bowen AC. A retrospective case-series of children with bone and joint infection from northern Australia. *Medicine (Baltimore)* 2016;95:e2885.
3. Kim J, Lee MU, Kim TH. Nationwide epidemiologic study for pediatric osteomyelitis and septic arthritis in South Korea: a cross-sectional study of national health insurance review and assessment service. *Medicine (Baltimore)* 2019;98:e15355.
4. Okubo Y, Nochioka K, Testa M. Nationwide survey of pediatric acute osteomyelitis in the USA. *J Pediatr Orthop B* 2017;26:501–506.
5. Tretiakov M, Cautela FS, Walker SE, et al. Septic arthritis of the hip and knee treated surgically in pediatric patients: analysis of the Kids' Inpatient Database. *J Orthop* 2019;16:97–100.
6. Safdieh G, Silberman J, Nguyen J, et al. Pediatric septic arthritis and osteomyelitis in the USA: a national KID database analysis. *HSS J* 2019;15:159–166.
7. Rai A, Chakladar D, Bhowmik S, et al. Neonatal septic arthritis: Indian perspective. *Eur J Rheumatol* 2020;7:572–577.
8. DeRonde KJ, Giroto JE, Nicolau DP. Management of pediatric acute hematogenous osteomyelitis, part I: antimicrobial stewardship approach and review of therapies for methicillin-susceptible *Staphylococcus aureus*, *Streptococcus pyogenes*, and *Kingella kingae*. *Pharmacotherapy* 2018;38:947–966.
9. DeRonde KJ, Giroto JE, Nicolau DP. Management of pediatric acute hematogenous osteomyelitis, part II: a focus on methicillin-resistant *Staphylococcus aureus*, current and emerging therapies. *Pharmacotherapy* 2018;38:1021–1037.
10. El-Sobky TA, Haleem JF, Samir S. Eumycetoma osteomyelitis of the calcaneus in a child: a radiologic-pathologic correlation following total calcanectomy. *Case Rep Pathol* 2015;2015:129020.
11. Omoke NI. Childhood pyogenic osteomyelitis in Abakaliki, south east Nigeria. *Niger J Surg* 2018;24:27–33.
12. Chiappini E, Mastrolia MV, Galli L, De Martino M, Lazzeri S. Septic arthritis in children in resource limited and non-resource limited countries: an update on diagnosis and treatment. *Expert Rev Anti Infect Ther* 2016;14:1087–1096.
13. Swarup I, Meza BC, Weltsch D, Jina AA, Lawrence JT, Baldwin KD. Septic arthritis of the knee in children: a critical analysis review. *JBJS Rev* 2020;8:e0069.
14. Street M, Crawford H. Pediatric humeral osteomyelitis. *J Pediatr Orthop* 2015;35:628–633.
15. Kasalak Ö, Overbosch J, Adams HJ, et al. Diagnostic value of MRI signs in differentiating Ewing sarcoma from osteomyelitis. *Acta Radiol* 2019;60:204–212.
16. Kim EY, Kwack KS, Cho JH, Lee DH, Yoon SH. Usefulness of dynamic contrast-enhanced MRI in differentiating between septic arthritis and transient synovitis in the hip joint. *AJR Am J Roentgenol* 2012;198:428–433.
17. Kiran M, Mohamed S, Newton A, George H, Garg N, Bruce C. Pelvic pyomyositis in children: changing trends in occurrence and management. *Int Orthop* 2018;42:1143–1147.

- 18. Boccuzzi E, Buonsenso D, Ferro V, et al.** The osteoarticular Infection in a pediatric emergency setting: a challenging diagnosis. *Pediatr Emerg Care* 2020;36:e108–e114.
- 19. Ben-Zvi L, Sebag D, Izhaki G, Katz E, Bernfeld B.** Diagnosis and management of infectious arthritis in children. *Curr Infect Dis Rep* 2019;21:23.
- 20. Ali AM, Maya E, Lakhoo K.** Challenges in managing paediatric osteomyelitis in the developing world: analysis of cases presenting to a tertiary referral centre in Tanzania. *Afr J Paediatr Surg* 2014;11:308–311.
- 21. Treleaven E, Pham TN, Le DN, Brooks TN, Le HT, Partridge JC.** Referral patterns, delays, and equity in access to advanced paediatric emergency care in Vietnam. *Int J Equity Health* 2017;16:215.
- 22. Marcin JP, Shaikh U, Steinhorn RH.** Addressing health disparities in rural communities using telehealth. *Pediatr Res* 2016;79:169–176.
- 23. Lovejoy JF III, Alexander K, Dinan D, Drehner D, Khan-Assad N, Lacerda IRA.** Team approach: pyomyositis. *JBSJ Rev* 2017;5:e4.
- 24. Kim J, Barreix M, Babcock C, Bills CB.** Acute care referral systems in Liberia: transfer and referral capabilities in a low-income country. *Prehosp Disaster Med* 2017;32:642–650.
- 25. Ilharberorde B.** Sequelae of pediatric osteoarticular infection. *Orthop Traumatol Surg Res* 2015;101:S129–S137.
- 26. Agarwal A, Aggarwal AN.** Bone and joint infections in children: septic arthritis. *Indian J Pediatr* 2016;83:825–833.
- 27. Patel L, Michael J, Schroeder L, Sherman AK, Berglund L, Newland JG.** Can a septic hip decision rule aid in the evaluation of suspected pediatric musculoskeletal infections? *J Emerg Med* 2019;56:241–247.
- 28. Ritchie B, Porritt K, Marin T, Williams N.** Diagnostic test accuracy of serum measurement of procalcitonin and C-reactive protein for bone and joint infection in children and adolescents: a systematic review protocol. *JBI Evid Synth* 2020;18:564–570.
- 29. Wong M, Williams N, Cooper C.** Systematic review of *Kingella kingae* musculoskeletal infection in children: epidemiology, impact and management strategies. *Pediatric Health Med Ther* 2020;11:73–84.
- 30. Hardy C, Osei L, Basset T, Elenga N.** Bone and joint infections with *Staphylococcus aureus* strains producing Pantone-Valentine leukocidin in French Guiana. *Medicine (Baltimore)* 2019;98:e16015.
- 31. Akinkugbe O, Stewart C, McKenna C.** Presentation and investigation of pediatric bone and joint infections in the pediatric emergency department. *Pediatr Emerg Care* 2019;35:700–704.
- 32. Nguyen JC, Rebsamen SL, Tuite MJ, Davis JM, Rosas HG.** Imaging of *Kingella kingae* musculoskeletal infections in children: a series of 5 cases. *Emerg Radiol* 2018;25:615–620.
- 33. Gravel J, Ceroni D, Lacroix L, et al.** Association between oropharyngeal carriage of *Kingella kingae* and osteoarticular infection in young children: a case-control study. *CMAJ* 2017;189:E1107–E1111.
- 34. Roediger JC, Outhred AC, Shadbolt B, Britton PN.** Paediatric *Staphylococcus aureus* bacteraemia: a single-centre retrospective cohort. *J Paediatr Child Health* 2017;53:180–186.
- 35. Al-Qwbani M, Jiang N, Yu B, Jiang N, Yu B.** *Kingella kingae* associated pediatric osteoarticular infections: an overview of 566 reported cases. *Clin Pediatr (Phila)* 2016;55:1328–1337.
- 36. Markanday A.** Acute phase reactants in infections: evidence-based review and a guide for clinicians. *Open Forum Infect Dis* 2015;2:ofv098.
- 37. Obana KK, Murgai RR, Schur M, et al.** Synovial fluid cell counts and its role in the diagnosis of paediatric septic arthritis. *J Child Orthop* 2019;13:417–422.
- 38. Mortazavi SMJ, Kalantar H, Baghdadi S, et al.** The utility of leukocyte esterase strip test in the diagnosis of pediatric septic arthritis. *J Pediatr Orthop* 2020;40:e312–e316.
- 39. Wyers MR, Samet JD, Mithal LB.** Physseal separation in pediatric osteomyelitis. *Pediatr Radiol* 2019;49:1229–1233.
- 40. Chaber R, Arthur CJ, Depciuch J, et al.** Distinguishing Ewing sarcoma and osteomyelitis using FTIR spectroscopy. *Sci Rep* 2018;8:15081.
- 41. McCarville MB, Chen JY, Coleman JL, et al.** Distinguishing osteomyelitis from Ewing sarcoma on radiography and MRI. *AJR Am J Roentgenol* 2015;205:640–650.
- 42. Ernat J, Riccio AI, Fitzpatrick K, Jo C, Wimberly RL.** Osteomyelitis is commonly associated with septic arthritis of the shoulder in children. *J Pediatr Orthop* 2017;37:547–552.
- 43. Rosenfeld S, Bernstein DT, Daram S, Dawson J, Zhang W.** Predicting the presence of adjacent infections in septic arthritis in children. *J Pediatr Orthop* 2016;36:70–74.
- 44. Monsalve J, Kan JH, Schallert EK, Bisset GS, Zhang W, Rosenfeld SB.** Septic arthritis in children: frequency of coexisting unsuspected osteomyelitis and implications on imaging work-up and management. *AJR Am J Roentgenol* 2015;204:1289–1295.
- 45. Merlini L, Anoosiravani M, Ceroni D.** Concomitant septic arthritis and osteomyelitis of the hip in young children: a new pathophysiological hypothesis suggested by MRI enhancement pattern. *BMC Med Imaging* 2015;15:17.
- 46. Nduaguba AM, Flynn JM, Sankar WN.** Septic arthritis of the elbow in children: clinical presentation and microbiological profile. *J Pediatr Orthop* 2016;36:75–79.
- 47. Kaziz H, Triki MA, Mouelhi T, Bouattour K, Naouar N, Ben Ayeche ML.** Septic elbow arthritis in children: epidemiology and outcome. *Arch Pediatr* 2019;26:38–43.
- 48. Le Saux N.** Diagnosis and management of acute osteoarticular infections in children. *Paediatr Child Health* 2018;23:336–343.
- 49. Gouveia C, Duarte M, Norte S, et al.** Osteoarticular infections in paediatric sickle cell disease: in the era of multidrug-resistant bacteria. *Br J Haematol* 2020;189:e147–e150.
- 50. Chalouhi C, Nicolas N, Vegas N, et al.** Scurvy: a new old cause of skeletal pain in young children. *Front Pediatr* 2020;8:8.
- 51. Golriz F, Donnelly LF, Devaraj S, Krishnamurthy R.** Modern American scurvy: experience with vitamin C deficiency at a large children's hospital. *Pediatr Radiol* 2017;47:214–220.
- 52. Agarwal A, Shaharyar A, Kumar A, Bhat MS, Mishra M.** Scurvy in pediatric age group: a disease often forgotten? *J Clin Orthop Trauma* 2015;6:101–107.
- 53. Lindsay AJ, Delgado J, Jaramillo D, Chauvin NA.** Extended field of view magnetic resonance imaging for suspected osteomyelitis in very young children: is it useful? *Pediatr Radiol* 2019;49:379–386.
- 54. Markhardt BK, Woo K, Nguyen JC.** Evaluation of suspected musculoskeletal infection in children over 2 years of age using only fluid-sensitive sequences at MRI. *Eur Radiol* 2019;29:5682–5690.
- 55. Moser T, Ehlinger M, Chelli Bouaziz M, Fethi Ladeb M, Durckel J, Dosch JC.** Pitfalls in osteoarticular imaging: how to distinguish bone infection from tumour? *Diagn Interv Imaging* 2012;93:351–359.



- 56. Gulko E, Collins LK, Murphy RC, Thornhill BA, Taragin BH.** MRI findings in pediatric patients with scurvy. *Skeletal Radiol* 2015;44:291–297.
- 57. Nguyen JC, Lee KS, Thapa MM, Rosas HG.** US evaluation of juvenile idiopathic arthritis and osteoarticular infection. *Radiographics* 2017;37:1181–1201.
- 58. Grammatico-Guillon L, Maakaroun Vermesse Z, Baron S, Gettner S, Rusch E, Bernard L.** Paediatric bone and joint infections are more common in boys and toddlers: a national epidemiology study. *Acta Paediatr* 2013;102:e120–e125.
- 59. Sankaran G, Zacharia B, Roy A, Purayil SP.** Current clinical and bacteriological profile of septic arthritis in young infants: a prospective study from a tertiary referral centre. *Eur J Orthop Surg Traumatol* 2018;28:573–578.
- 60. Sreenivas T, Nataraj AR, Kumar A, Menon J.** Neonatal septic arthritis in a tertiary care hospital: a descriptive study. *Eur J Orthop Surg Traumatol* 2016;26:477–481.
- 61. Gatto A, Lazzareschi I, Onesimo R, et al.** Short therapy in a septic arthritis of the neonatal hip. *Pediatr Rep* 2019;11:8161.
- 62. Kaushik A, Kest H.** Pediatric methicillin-resistant *Staphylococcus aureus* osteoarticular infections. *Microorganisms* 2018;6:40.
- 63. Nielsen AB, Nygaard U, Hoffmann T, Kristensen K.** Short individualised treatment of bone and joint infections in Danish children. *Arch Dis Child* 2019;104:205–206.
- 64. Chou AC, Mahadev A.** The use of C-reactive protein as a guide for transitioning to oral antibiotics in pediatric osteoarticular infections. *J Pediatr Orthop* 2016;36:173–177.
- 65. Sabour AF, Alluri RK, Heckmann N, Heidari KS, Rick Hatch GF III, Vandenberg C.** A nationwide analysis of failed irrigation and debridement for pediatric septic arthritis of the hip. *J Pediatr Orthop B* 2019;28:470–475.
- 66. El-Sayed AM.** Treatment of early septic arthritis of the hip in children: comparison of results of open arthrotomy versus arthroscopic drainage. *J Child Orthop* 2008;2:229–237.
- 67. Weigl DM, Becker T, Mercado E, Bar-On E.** Percutaneous aspiration and irrigation technique for the treatment of pediatric septic hip: effectiveness and predictive parameters. *J Pediatr Orthop B* 2016;25:514–519.
- 68. Qin YF, Li ZJ, Li H.** Corticosteroids as adjunctive therapy with antibiotics in the treatment of children with septic arthritis: a meta-analysis. *Drug Des Devel Ther* 2018;12:2277–2284.
- 69. Hernández-Rupérez MB, Suárez-Arrabal MDC, Villa-García Á, et al.** *Kingella kingae* as the main cause of septic arthritis: importance of molecular diagnosis. *Pediatr Infect Dis J* 2018;37:1211–1216.
- 70. Sharma R, Hammerschlag MR.** Treatment of methicillin-resistant *Staphylococcus aureus* (mrsa) infections in children: a reappraisal of vancomycin. *Curr Infect Dis Rep* 2019;21:37.
- 71. Lounsbury N, Reeber MG, Mina G, Chbib C.** A mini-review on ceftaroline in bacteremia patients with methicillin-resistant *Staphylococcus aureus* (MRSA) infections. *Antibiotics (Basel)* 2019;8:30.
- 72. Johnson LB, Ramani A, Guervil DJ.** Use of ceftaroline fosamil in osteomyelitis: CAPTURE study experience. *BMC Infect Dis* 2019;19:183.
- 73. Bram JT, Baldwin KD, Blumberg TJ.** Gram stain is not clinically relevant in treatment of pediatric septic arthritis. *J Pediatr Orthop* 2018;38:e536–e540.
- 74. Gan C, Hu J, Cao Q, et al.** Rapid identification of pathogens involved in pediatric osteoarticular infections by multiplex PCR. *Ann Transl Med* 2020;8:203.
- 75. Roul-Levy A, Looten V, Bachy M, Grimpel E, Carbajal R, Vialle R, Looten V, Bachy M, Grimpel E, Carbajal R, Vialle R.** Oral ambulatory treatment of acute osteomyelitis in children: a case-control study. *Pediatr Emerg Care* 2016;32:154–156.