



Optimal microbiological sampling for the diagnosis of osteoarticular infection

Ricardo Sousa^{1,2}

André Carvalho¹

Ana Cláudia Santos^{2,3}

Miguel Araújo Abreu^{2,4}

- Infection is a dire complication afflicting every field of orthopaedics and traumatology. If specific clinical, laboratory and imaging parameters are present, infection is often assumed even in the absence of microbiological confirmation. However, apart from confirming infection, knowing the exact infecting pathogen(s) and their antimicrobial susceptibility patterns is paramount to help guide treatment. Every effort should therefore be undertaken with that goal in mind.
- Not all microbiological findings carry the same relevance, and knowing exactly how and where a sample was collected is key. Several different sampling techniques are available, and one must be aware of both advantages and limitations. Microbiological sampling alternatives in some of the most common clinical scenarios such as native and prosthetic joint infections, osteomyelitis and fracture-related infections, spinal and diabetic foot infections will be discussed.
- Orthopaedic surgeons should also be aware of basic laboratory sample processing techniques as they have a direct impact on the way specimens should be dealt with and transported to the laboratory. Only by knowing these basic principles will surgeons be able to participate in the multidisciplinary discussion and decision making around how to interpret microbiological findings in each specific patient.

Keywords: bone and joint infections; microbiology; tissue sampling

Cite this article: *EFORT Open Rev* 2021;6:390-398.

DOI: 10.1302/2058-5241.6.210011

Introduction

Infection is a serious complication that affects all fields of orthopaedics and traumatology. Even though in certain specific conditions infection can be assumed even in the absence of isolated pathogens, adequate microbiological

confirmation is warranted in most clinical scenarios. Conversely, not all microbiological findings are necessarily pathologic as each individual is home to trillions of microbes that inhabit our bodies and constitute a healthy microbiome that contributes to normal homeostasis.¹ Human skin protects the body from outside pathogens but is also home to a rich microbial community of its own, most notably *Corynebacterium*, *Propionibacteriaceae* and *Staphylococci*.² Although in normal physiological conditions these bacteria are considered non-pathogenic, after operative procedures where the skin is breached, such as orthopaedic surgery, they are also among the most commonly found infective microorganisms.³

This scenario is aggravated by the presence of implants, such as screws, plates or even artificial joints that are frequently utilized in orthopaedic and trauma surgery. It is known that the presence of a foreign body reduces the amount of bacterial inoculum required to cause infection by a factor of more than 10^5 .⁴ Biofilm formation on the surface of such implants is not only responsible for increased susceptibility but also for increased difficulty in isolating infecting microorganisms. Bacteria present within biofilms are not as easily retrieved or grown in the laboratory.⁵

When deciding how to interpret microbiological findings, a number of other factors such as underlying clinical scenario, presence or absence of other laboratory or imaging findings indicative of infection, previous antibiotic therapy, etc., should be considered. However, precise identification of the microorganism(s) causing infection is at the very least needed to allow for the selection of the narrowest spectrum, least toxic, preferably oral antibiotics.

A comprehensive knowledge of how the sample was collected and subsequently processed is a critical part of the multidisciplinary decision process and one of which all orthopaedic surgeons must be aware. The aim of this article is to review the best practices for obtaining adequate samples in the most frequent clinical scenarios:

(a) native and prosthetic joint infections; (b) osteomyelitis and fracture-related infections; (c) spinal infections and; (d) diabetic foot infections. Although a thorough description of laboratory procedures is beyond the scope of this article, a short overview with a special emphasis on its impact on the correct collection and transport of specimens for microbiological investigation will also be provided.

Native and prosthetic joint infection

Whenever there is an infection, samples should be gathered as close to the site as possible. In the case of native or prosthetic joint infections (PJI), synovial fluid obtained through arthrocentesis of the affected joint is the best diagnostic sample. It allows not only for microbiological investigation but also more comprehensive investigation including differential leukocyte count and a number of potential biomarkers that may constitute the basis for diagnosis.^{6–8} In the case of an acutely ill patient, such as those with suspected native septic arthritis or full blown acute PJI, joint puncture must be performed as soon as possible. Blood cultures should also be taken before surgery or even starting antibiotic treatment to increase the chance of obtaining causative organisms.⁹

Suspected chronic PJI though is most often a quite different scenario. Although some suspicious clinical features such as a history of prosthetic joint infection (PJI), early loosening, previous wound healing disorder or elevated C-reactive protein increase the probability of infection, virtually every painful prosthesis should be investigated to rule out infection.^{6,10,11} In some instances, a draining wound or sinus tract will make the diagnosis of PJI obvious. In these cases, superficial swab cultures are tempting but they should be interpreted cautiously. Although they may be informative (especially if virulent microorganisms

such as Gram-negative bacilli or *S. aureus* are isolated in patients with suspected acute postoperative PJI) they are mostly unreliable in chronic draining sinus and often are positive for colonizing/contaminating bacteria.^{12,13}

Joint puncture must ideally be undertaken after a minimum two-week antibiotic-free period. Otherwise, diagnostic accuracy will be significantly compromised.¹⁴ It should also be performed under strict aseptic conditions in order to minimize the risk of iatrogenic contamination and to allow for further procedures (Fig. 1). If an insufficient amount of liquid is found, saline injection and subsequent reaspiration may be a useful technique.¹⁵ Naturally, if such a technique is used microbiology is the only feasible investigation. Although a positive *Gram stain* result may still be considered useful information, it should never be used to rule out infection as it has been shown to have very low sensitivity.^{16,17} Despite its lack of sensitivity and even some disagreement between preoperative and intraoperative bacteriological samples, *traditional cultures* of aspirated joint fluid remain an important feature of preoperative diagnosis.^{18,19} Specificity is quite high but even a positive culture must be interpreted cautiously together with other diagnostic tests.^{6,20} It is important to highlight that low-virulence microorganisms such as *Cutibacterium acnes* or coagulase-negative staphylococci are often contaminants.²¹

In addition to arthrocentesis, preoperative fluoroscopic-guided biopsies of periprosthetic synovial tissue²² or bone–prosthesis interface membrane²³ may also be helpful in establishing a diagnosis in doubtful cases (Fig. 1).

Given that most such infections will require some kind of surgical intervention, deep tissue sampling is usually considered to be the gold standard. Considering the etiology of implant-related infections, multiple surgical samples should be collected. Multiple sampling increases the chance of growing a pathogen (i.e. sensitivity) and

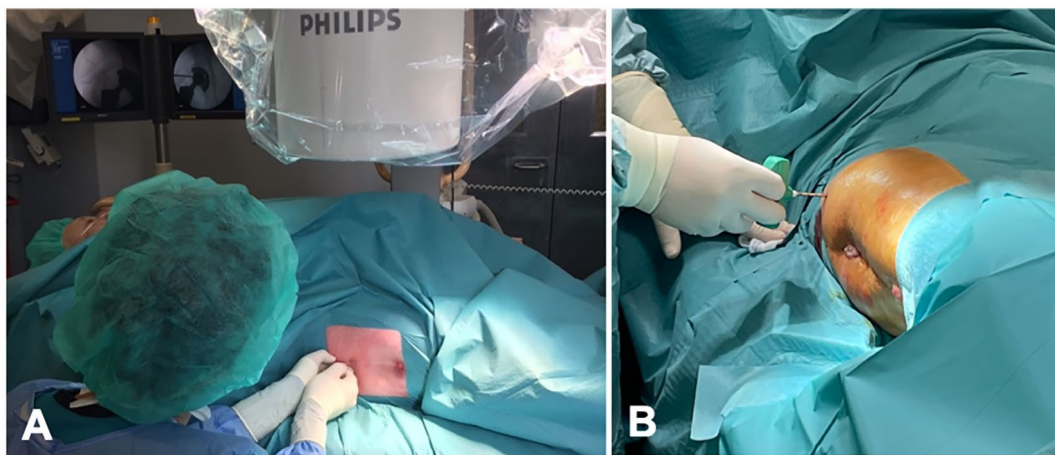


Fig. 1 Clinical aspect of fluoroscopic-guided hip arthrocentesis (A) and percutaneous biopsies (B). Downloaded from Bioscientifica.com at 10/04/2024 01:47:04AM via Open Access. This article is distributed under the terms of the Creative Commons Attribution-Non Commercial 4.0 International (CC BY-NC 4.0) licence (<https://creativecommons.org/licenses/by-nc/4.0/>) which permits non-commercial use, reproduction and distribution in any medium, provided the original work is attributed. <https://creativecommons.org/licenses/by-nc/4.0/>

it also allows more correct interpretation in cases where a low-virulence microorganism is found. Specificity is increased by interpreting the number of samples in which such species is grown. If more than one sample grows the same indistinguishable organism it is likely that it is indeed a pathogen and should not be dismissed as contaminant.^{6,24} Tissue sampling should be obtained from different sites within the joint and special consideration should be paid to obtaining samples from the bone–implant interface.^{25–27} To reduce the risk of cross contamination, they must be taken with different set of instruments and sent to the laboratory separately.

Lastly, biofilm dislodging techniques such as sonication are extremely helpful, especially when dealing with chronic low-grade implant-related infections.^{25,28,29} It is important to stress that sonication should not be considered an alternative to multiple tissue sampling but rather an add-on test especially useful in patients who have undergone previous antibiotic therapy.^{30–32}

Osteomyelitis and fracture-related infection

Whether it starts off as hematogenous or fracture-related infection, chronic osteomyelitis shares a lot of clinical features. Diagnosis may be evident if a sinus tract, wound breakdown to bone or implant or pus are present.³³ Nonetheless, even in this scenario, accurate identification of the microorganism(s) responsible for infection is critical to ensure correct antibiotic therapy.

Again, superficial swab cultures, tempting as they may be, should not be considered adequate sampling as they have consistently been shown not to correlate adequately with deep biopsy or tissue specimens.³⁴ Sinus tract cultures are also traditionally considered unreliable in predicting final microbiological results.^{35–37} Nevertheless, it has been shown that two consecutive sinus tract cultures with bone contact at different times may be informative in monomicrobial osteomyelitis if they offer identical results.³⁸ Unlike other clinical settings that will be discussed ahead, preoperative percutaneous biopsies are rarely of interest in chronic osteomyelitis as diagnostic yield as well as concordance with definitive cultures results are low.^{39,40}

As such, multiple surgical samples are indisputably the best way to achieve reliable identification of the microorganism(s) involved in osteomyelitis and fracture-related infection (FRI). Bacteria that may be considered skin commensals (such as coagulase-negative staphylococci, *Corynebacterium* or *Propionibacteriaceae*) account for a significant proportion of cases, especially in fractures and should never be dismissed without adequate consideration.⁴¹ As with PJI, at least five samples should be collected during surgery both to increase sensitivity and

help interpret positivity with such low-virulent microorganisms. Samples should be collected in a structured process, with separate instruments for each sample, avoiding touching the patient's skin with the sample or instrument.^{33,42} Tissue samples should be obtained from infection-suspected deep tissues and not superficial tissue or fluid. Bone samples, especially sequesters or loose infected bone fragments, should always be collected in chronic osteomyelitis.^{43,44}

Fracture-related infections are additionally problematic due to the presence of biofilm on the surface of implants. In these cases, tissue adjacent to the fracture, preferably from the implant–bone interface, should be favoured. Whenever possible, sonication of removed implants may also be performed as an adjunct to multiple tissue sampling.^{32,45}

Spinal infection

There are mostly two different types of spinal infections, primary hematogenous infections and surgical site infections. There are substantial differences regarding their pathophysiology, and they should be considered when deciding where and how to collect microbiology samples.

Hematogenous infections such as spondylodiscitis, facet joint septic arthritis or epidural abscess arise from hematogenous seeding of the axial skeleton from remote infected foci.⁴⁶ As such, blood cultures should routinely be collected. Their effectiveness in identifying the causative microorganism averages 58% (range, 30–78%).⁴⁷ Other clinically obvious foci such as urinary tract or abscesses should also be investigated.⁴⁶

Some patients, presenting with symptomatic cord compression with neurologic deficits, will require urgent surgery followed by empirical broad-spectrum antibiotics.⁴⁶ In these cases, open surgical biopsies during the procedure should naturally be collected as they offer the best diagnostic yield.^{48,49} However, most cases will not require urgent surgery. Except in critically ill patients with signs of sepsis, empiric antibiotics should be withheld until every effort has been made to collect adequate samples to establish a microbiological diagnosis as it will have a significant impact.

In patients with negative or unclear blood cultures results (ex. a single set growing coagulase-negative staphylococci) a computed tomography (CT)-guided biopsy should be scheduled as soon as possible. It is noteworthy that this technique is far from being a panacea, offering positive results in no more than 30–60% of cases.^{49–55} Positivity is higher in cases where imaging is consistent with infection^{52,53} and those with higher C-reactive protein. When the initial biopsy is negative, a second attempt may be performed although its real worth is unclear with results in the literature ranging from 0–60%.^{51,55,56} It is

still unclear why the diagnostic yield is so low in comparison to other specimen acquisition methods. Unlike other contexts in orthopaedics, it is not clear that bone tissue samples are advantageous over soft tissue sampling with conflicting results in the literature.^{50,57,58}

Postoperative surgical site infections are, nowadays, the most common form of spinal infection. They occur more commonly after spinal instrumentation compared to simple lumbar decompression or microdiscectomy, and clinical presentation varies accordingly.⁵⁹ Patients presenting with obvious signs of infection such as wound dehiscence and purulent drainage will often require wound exploration and surgical debridement during which unhealthy looking, preferably deep, tissues should be collected for microbiological diagnosis. As previously discussed, antibiotics should be withheld until sample collection except in patients systemically ill or septic. In these cases, blood cultures should be taken before broad-spectrum antibiotics are initiated.

Most patients will present a much more subtle clinical picture mainly characterized by excessive pain around one month after the procedure.^{59,60} Although percutaneous CT-guided biopsy may be informative, especially in postprocedural diskitis, it is seldom required after spinal instrumentation.

Unlike hematogenous infections the vast majority of implant-associated infections will require some form of surgery. Therefore, open surgical sampling is preferred. Spinal implant-related infection treatment follows similar principles as for other implants such as prosthesis. Early infections may be addressed without hardware removal but late infections often require removal of implants.⁵⁹ In such cases, culture of removed hardware may be extremely useful especially if biofilm-dislodging techniques such as sonication are used.^{61,62} It is becoming increasingly clear that occult infections are present in a significant proportion of presumably aseptic failures requiring revision surgery.^{61–64} Systematic sample collection for microbiology investigation is therefore recommended in every revision spinal surgery especially in the context of failed fusion.^{63,64}

Diabetic foot infection

Diabetic foot osteomyelitis (DFO) is usually caused by contiguous spread from an infected foot ulcer. Foot ulceration is the most frequently recognized complication of long-standing diabetes and typically originates from repeated microtrauma due to a combination of foot deformities, peripheral neuropathy and/or peripheral artery disease.⁶⁵ Patients with DFO have worse outcomes, more surgeries and amputations, longer hospitalizations, and higher rates of recurrent infection and readmission for infection than patients with soft tissue infection.⁶⁶ Naturally, clear identification of the infecting microorganism(s) is required for optimal treatment guidance.

Wound swabs are minimally invasive, easy to perform and widely employed in clinical practice, but their findings need to be appreciated and valued according to the specific clinical context. In clearly superficial ulcerate, when the swab is the only sampling method available, the Levine swab technique, where a swab is rotated over a 1 cm² area for five seconds with sufficient pressure to extract fluid both from the wound surface biofilm and from underlying tissues, may be a valid alternative to collect a superficial sample.^{67,68} Nevertheless, it is critical to acknowledge that organisms cultured from superficial swabs usually are not reliable for predicting the pathogens responsible for deeper infection and are also more prone to contamination.^{69–72} As such, the preferred clinical specimens for reliable culture from a diabetic foot wound include curettage from the ulcer base following superficial debridement of necrotic tissue or aspirate from an abscess.^{69–72}

When infection runs even deeper and there is clinical or radiographic evidence of osteomyelitis, deep tissue needle aspiration,⁷³ deep wound swabs taken through the discharging ulcer probing to the bone⁷⁴ or even tissue biopsies^{69,75} have also been suggested as alternative methods. However, several studies have shown poor correlation between cultures obtained by soft tissue and bone sampling, suggesting that soft tissue samples are inadequate to guide DFO antibiotic treatment.^{66,70,74–76} As such, percutaneous bone biopsies have emerged as the best sampling alternative in patients not undergoing surgical debridement⁷⁶ and have been widely recommended by major medical associations in the field, especially in patients at risk for antibiotic-resistant microorganism(s) and with unclear soft tissue culture results.^{77–79} Biopsies should be performed under fluoroscopic or CT guidance and the needle should traverse uninvolved skin. This is a technically simple procedure that can be easily performed in an outpatient setting without significant complications (Fig. 2).^{76,80}

Sample transport and laboratory processing

A first guiding principle that should always be recognized is that samples collected for microbiological investigation must be sent for laboratory processing as quickly as possible. The longer it takes for bacteria to reach the culture media, the less likely it will be that they are actually grown. A second critical point is that samples should be inserted into sterile transport containers immediately after being obtained. This is especially relevant during surgery. It is not an uncommon error to place samples on the table for the duration of the surgical procedure. It has been clearly shown that a significant proportion of false positives may arise in this manner.⁸¹

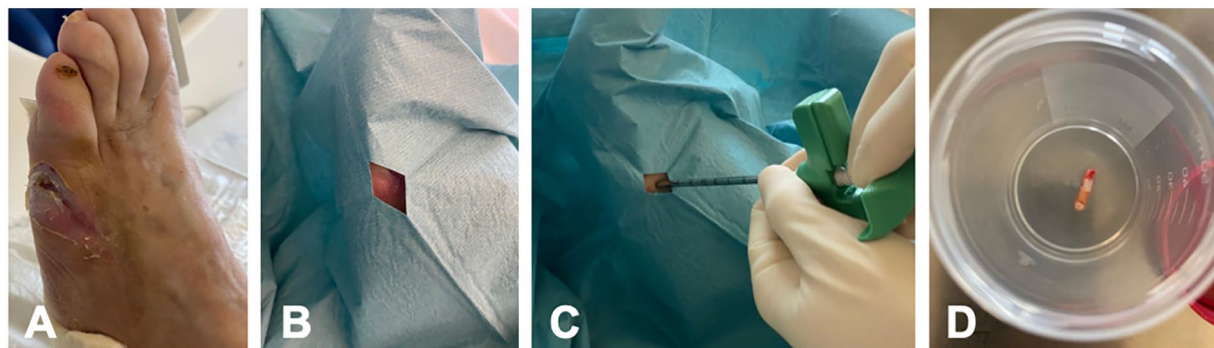


Fig. 2 Percutaneous bone biopsy performed in a diabetic foot. (A) Diabetic foot osteomyelitis of the fifth metatarsal; (B) surgical field prepared through uninvolved skin; (C) bone biopsy needle use; (D) bone plug sent for laboratory processing.




Fig. 3 (A) Commercially available vials with stainless steel beads, saline and soft perforable cover; (B) clinical aspect of tissue sample being immediately introduced into the vial within the operating field; (C) vortexing the sample; (D) aliquots of 'liquified' sample are now ready to be inoculated into aerobic and anaerobic blood culture bottles.

Traditionally, synovial fluid recovered from suspicious infected joints is sent to the laboratory in simple sterile vials. Only after reaching the laboratory would the fluid be inoculated onto culture media plates. In addition to reducing the time between harvest and processing, inoculation of synovial fluid directly into blood culture bottles offers a number of advantages. Firstly, it is a highly sensitive method which is especially important in scenarios where a small amount of fluid is recovered and/or there are a presumably low number of viable bacteria present. Secondly, it allows for identification of a broader spectrum of pathogens including slow-growing bacteria without requiring culturing several different and enriched culture media.⁸² Finally, automatic systems associated with processing blood culture bottles allow quicker bacterial identification with minimal human errors. The advantages of blood culture bottles have consistently been proven either for the diagnosis of true native septic arthritis⁸³ or even prosthetic joint infections.^{82,84,85} This method is also being used to study other fluids such as sonication fluid originating from implant-related orthopaedic infections with favourable results.²⁹

As previously discussed, multiple tissue samples are often recommended, but processing all these samples separately must be carried out fastidiously and is very time-consuming. This is especially true in the demanding setting of prosthetic joint and other implant-related infections where its biofilm, often polymicrobial, nature recommends the routine use of an assortment of media suitable for recovery of fastidious, slow-growing, anaerobic and sublethally damaged bacteria such as Chocolate agar, MacConkey agar, Thioglycolate broth, etc.^{86,87} Moreover, it has been shown that this process should be extended for up to 14 days.^{87,88}

Given its relative ease and simplicity, the use of blood culture bottles to process samples has also gained considerable popularity for processing bone and soft tissue samples. The main difference is that beads and vigorous shaking must be used to disrupt tissue and release bacteria. This can be done by manually adding sterile glass (Ballo-tini) beads using an aseptic technique in a safety cabinet or by using specific commercially available vials (Fig. 3). Once the sample is 'liquified', aliquots are inoculated into culture bottles. Since anaerobic bacteria are significant pathogens



Fig. 4 (A) Implant (in this case a hip spacer) sent to the laboratory in a solid container with airtight seal; (B) sonicator at the laboratory bench; (C) sonication of the container with the implant; (D) only after sonication is the container opened using aseptic technique and sonication fluid is collected and inoculated into selected culture media.

in implant-related infections, it is important to use both aerobic and anaerobic vials in such circumstances.⁸⁹ The use of automated blood culture bottles systems to process tissue samples has consistently been shown to result in improved diagnostic accuracy.^{90–93} In addition, time to positivity from surgery to results is significantly shorter, which translates into shorter broad-spectrum antibiotics periods.^{90,94}

As has already been discussed, sonication of removed implants may be a useful adjunct. It must be noted that it requires simple yet specific equipment that is not widely available in most laboratories. Once a decision is made to use sonication, it is important to point out that implants should be placed into sterile solid containers with airtight seals, as it has been shown that plastic bags are prone to contamination and therefore lack of specificity.⁹⁵ The implant should be (at least for the most part) covered in saline or Ringer's solution and subsequent laboratory processing follows a sequential vortexing–sonication–vortexing validated protocol before aliquots of sonication fluid are inoculated into selected culture media (Fig. 4).⁹⁶

Conclusion and future developments

Infections are defined by pathologic invasion and growth of germs in the human body. Adequate sampling and microbiological identification is critical. The specific pathophysiology of bone infections, especially the presence of biofilm in implants, is such that it is not uncommon for classic microbiological investigation to offer suboptimal results. As such, there is a growing body of knowledge allowing for definition of infection even without classic microbiologic confirmation. Highly sensitive molecular diagnostics techniques will certainly play a role in the future in these so-called culture-negative infections. They are already able to identify pathogens and even to determine the presence of certain antibiotic resistance genes. Despite their early promise, they are neither widely studied nor readily available in most laboratories.

For the time being, treating physicians must rely on adequate sampling to offer the best chance to identify the infecting pathogen(s). Ideally, decisions regarding complex bone and joint infections will be made in

a multidisciplinary team setting. Knowledge about how and when the sample was collected and processed is critical for accurate interpretation of the available information. The orthopaedic surgeon is often the one responsible for obtaining specimens and must therefore be knowledgeable about the nuances around this topic.

AUTHOR INFORMATION

¹Department of Orthopaedics, Centro Hospitalar Universitário do Porto, Porto, Portugal.

²Porto Bone and Joint Infection Group (GRIP), Centro Hospitalar Universitário do Porto and Grupo TrofaSaude, Portugal.

³Department of Microbiology, Centro Hospitalar Universitário do Porto, Porto, Portugal.

⁴Department of Infectious Diseases, Centro Hospitalar Universitário do Porto, Porto, Portugal.

Correspondence should be sent to: Ricardo Sousa, Orthopaedics Department, Centro Hospitalar Universitário do Porto, Largo Professor Abel Salazar, 4099-001 Porto, Portugal.

Email: contacto@ricardosousaortopedia.com

ACKNOWLEDGEMENTS

The authors would like to thank Dr Joana Martins, vascular surgeon of our institution's Diabetic Foot Clinic for allowing us to use the photographs that compose Fig. 2.

ICMJE CONFLICT OF INTEREST STATEMENT

RS received payment for lectures including service on speakers Bureaux, not related to the topic of this paper, for relevant financial activities outside the submitted work.

FUNDING STATEMENT

No benefits in any form have been received or will be received from a commercial party related directly or indirectly to the subject of this article.

OPEN ACCESS

© 2021 The author(s)

This article is distributed under the terms of the Creative Commons Attribution-Non Commercial 4.0 International (CC BY-NC 4.0) licence (<https://creativecommons.org/licenses/by-nc/4.0/>) which permits non-commercial use, reproduction and distribution of the work without further permission provided the original work is attributed.

REFERENCES

- Lloyd-Price J, Abu-Ali G, Huttenhower C.** The healthy human microbiome. *Genome Med* 2016;8:51.
- Grice EA, Kong HH, Conlan S, et al; NISC Comparative Sequencing Program.** Topographical and temporal diversity of the human skin microbiome. *Science* 2009;324:1190–1192.
- Lemaignen A, Bernard L, Marmor S, Ferry T, Grammatico-Guillon L, Astagneau P; Scientific Committee for Complex Bone and Joint Infections Reference Centers (CRIOAc), on behalf of the CRIOAc network.** Epidemiology of complex bone and joint infections in France using a national registry: the CRIOAc network. *J Infect* 2020;50163–4453(20)30771–4.
- Zimmerli W, Waldvogel FA, Vaudaux P, Nydegger UE.** Pathogenesis of foreign body infection: description and characteristics of an animal model. *J Infect Dis* 1982;146:487–497.
- Tzeng A, Tzeng TH, Vasdev S, et al.** Treating periprosthetic joint infections as biofilms: key diagnosis and management strategies. *Diagn Microbiol Infect Dis* 2015;81:192–200.
- McNally M, Sousa R, Wouthuyzen-Bakker M, et al.** The EBJS definition of periprosthetic joint infection. *Bone Joint J* 2021;103-B:18–25.
- Sousa R, Serrano P, Gomes Dias J, Oliveira JC, Oliveira A.** Improving the accuracy of synovial fluid analysis in the diagnosis of prosthetic joint infection with simple and inexpensive biomarkers: C-reactive protein and adenosine deaminase. *Bone Joint J* 2017;99-B:351–357.
- Margaretten ME, Kohlwes J, Moore D, Bent S.** Does this adult patient have septic arthritis? *JAMA* 2007;297:1478–1488.
- Mathews CJ, Weston VC, Jones A, Field M, Coakley G.** Bacterial septic arthritis in adults. *Lancet* 2010;375:846–855.
- Portillo ME, Salvado M, Alier A, Sorli L, Martinez S, Horcajada JP, et al.** Prosthesis failure within 2 years of implantation is highly predictive of infection. *Clin Orthop Relat Res* 2013;471:3672–3678.
- Zhu Y, Zhang F, Chen W, Liu S, Zhang Q, Zhang Y.** Risk factors for periprosthetic joint infection after total joint arthroplasty: a systematic review and meta-analysis. *J Hosp Infect* 2015;89:82–89.
- Tetreault MW, Wetters NG, Aggarwal VK, Moric M, Segreti J, Huddleston JI 3rd, et al.** Should draining wounds and sinuses associated with hip and knee arthroplasties be cultured? *J Arthroplasty* 2013;28:133–136.
- Cuñé J, Soriano A, Martínez JC, García S, Mensa J.** A superficial swab culture is useful for microbiologic diagnosis in acute prosthetic joint infections. *Clin Orthop Relat Res* 2009;467:531–535.
- Shahi A, Deirmengian C, Higuera C, et al.** Premature therapeutic antimicrobial treatments can compromise the diagnosis of late periprosthetic joint infection. *Clin Orthop Relat Res* 2015;473:2244–2249.
- Partridge DG, Winnard C, Townsend R, Cooper R, Stockley I.** Joint aspiration, including culture of reaspirated saline after a 'dry tap', is sensitive and specific for the diagnosis of hip and knee prosthetic joint infection. *Bone Joint J* 2018;100-B:749–754.
- Morgan PM, Sharkey PF, Ghanem E, Parvizi J, Clohisy JC, Burnett RSJ, et al.** The value of intraoperative Gram stain in revision total knee arthroplasty. *J Bone Joint Surg Am* 2009;91:2124–2129.
- Wouthuyzen-Bakker M, Shohat N, Sebillotte M, Arvieux C, Parvizi J, Soriano A.** Is Gram staining still useful in prosthetic joint infections? *J Bone Jt Infect* 2019;4:56–59.
- Matter-Parrat V, Ronde-Oustau C, Boéri C, Gaudias J, Jenny JY.** Agreement between pre-operative and intra-operative bacteriological samples in 85 chronic peri-prosthetic infections. *Orthop Traumatol Surg Res* 2017;103:301–305.
- Holleyman RJ, Deehan DJ, Charlett A, Gould K, Baker PN.** Does pre-operative sampling predict intra-operative cultures and antibiotic sensitivities in knee replacements revised for infection? A study using the NJR dataset. *Knee Surg Sports Traumatol Arthrosc* 2016;24:3056–3063.
- Qu X, Zanjing Z, Wu C, Jin F, Li H, Wang L, et al.** Preoperative aspiration culture for preoperative diagnosis of infection in total hip or knee arthroplasty. *J Clin Microbiol* 2013;51:3830–3834.
- Namdari S, Nicholson T, Parvizi J.** *Cutibacterium acnes* is isolated from air swabs: time to doubt the value of traditional cultures in shoulder surgery? *Arch Bone Jt Surg* 2020;8:506–510.
- Fink B, Schuster P, Braun R, Tagtalianidou E, Schlumberger M.** The diagnostic value of routine preliminary biopsy in diagnosing late prosthetic joint infection after hip and knee arthroplasty. *Bone Joint J* 2020;102-B:329–335.
- Corona P, Gil E, Guerra E, et al.** Percutaneous interface biopsy in dry-aspiration cases of chronic periprosthetic joint infections: a technique for preoperative isolation of the infecting organism. *Int Orthop* 2012;36:1281–1286.
- Atkins BL, Athanasou N, Deeks JJ, et al; The OSIRIS Collaborative Study Group.** Prospective evaluation of criteria for microbiological diagnosis of prosthetic-joint infection at revision arthroplasty. *J Clin Microbiol* 1998;36:2932–2939.
- Hischebeth GT, Randau TM, Molitor E, et al.** Comparison of bacterial growth in sonication fluid cultures with periprosthetic membranes and with cultures of biopsies for diagnosing periprosthetic joint infection. *Diagn Microbiol Infect Dis* 2016;84:112–115.
- Bori G, Muñoz-Mahamud E, García S, et al.** Interface membrane is the best sample for histological study to diagnose prosthetic joint infection. *Mod Pathol* 2011;24:579–584.
- Walker LC, Clement ND, Wilson I, Hashmi M, Samuel J, Deehan DJ.** The importance of multi-site intra-operative tissue sampling in the diagnosis of hip and knee periprosthetic joint infection: results from a single centre study. *J Bone Jt Infect* 2020;5:151–159.
- Zhai Z, Li H, Qin A, Liu G, Liu X, Wu C, et al.** Meta-analysis of sonication fluid samples from prosthetic components for diagnosis of infection after total joint arthroplasty. *J Clin Microbiol* 2014;52:1730–1736.
- Portillo ME, Salvado M, Trampuz A, Siverio A, Alier A, Sorli L, et al.** Improved diagnosis of orthopedic implant-associated infection by inoculation of sonication fluid into blood culture bottles. *J Clin Microbiol* 2015;53:1622–1627.
- Shen H, Tang J, Wang Q, Jiang Y, Zhang X.** Sonication of explanted prosthesis combined with incubation in BD bactec bottles for pathogen-based diagnosis of prosthetic joint infection. *J Clin Microbiol* 2015;53:777–781.
- Trampuz A, Piper KE, Jacobson MJ, Hanssen AD, Unni KK, Osmon DR, et al.** Sonication of removed hip and knee prostheses for diagnosis of infection. *N Engl J Med* 2007;357:654–663.
- Dudareva M, Barrett L, Figtree M, et al.** Sonication versus tissue sampling for diagnosis of prosthetic joint and other orthopedic device-related infections. *J Clin Microbiol* 2018;56:e00688-18.
- McNally M, Govaert G, Dudareva M, Morgenstern M, Metsemakers WJ.** Definition and diagnosis of fracture-related infection. *EFORT Open Rev* 2020;5:614–619.
- Vemu L, Sudhaharan S, Mamidi N, Chavali P.** Need for appropriate specimen for microbiology diagnosis of chronic osteomyelitis. *J Lab Physicians* 2018;10:21–25.

- 35. Patzakis MJ, Wilkins J, Kumar J, Holtom P, Greenbaum B, Ressler R.** Comparison of the results of bacterial cultures from multiple sites in chronic osteomyelitis of long bones: a prospective study. *J Bone Joint Surg Am* 1994;76:664–666.
- 36. Ulug M, Ayaz C, Celen MK, Geyik MF, Hosoglu S, Necmioglu S.** Are sinus-track cultures reliable for identifying the causative agent in chronic osteomyelitis? *Arch Orthop Trauma Surg* 2009;129:1565–1570.
- 37. Akinyoola AL, Adegbehingbe OO, Aboderin AO.** Therapeutic decision in chronic osteomyelitis: sinus track culture versus intraoperative bone culture. *Arch Orthop Trauma Surg* 2009;129:449–453.
- 38. Bernard L, Uckay I, Vuagnat A, Assal M, Stern R, Rohner P, et al.** Two consecutive deep sinus tract cultures predict the pathogen of osteomyelitis. *Int J Infect Dis* 2010;14:e390–3.
- 39. Hoang D, Fisher S, Oz OK, La Fontaine J, Chhabra A.** Percutaneous CT guided bone biopsy for suspected osteomyelitis: diagnostic yield and impact on patient's treatment change and recovery. *Eur J Radiol* 2019;114:85–91.
- 40. Hirschfeld CB, Kapadia SN, Bryan J, et al.** Impact of diagnostic bone biopsies on the management of non-vertebral osteomyelitis: a retrospective cohort study. *Medicine (Baltimore)* 2019;98:e16954.
- 41. Dudareva M, Hotchen AJ, Ferguson J, et al.** The microbiology of chronic osteomyelitis: changes over ten years. *J Infect* 2019;79:189–198.
- 42. Hellebrekers P, Rentenaar RJ, McNally MA, et al.** Getting it right first time: the importance of a structured tissue sampling protocol for diagnosing fracture-related infections. *Injury* 2019;50:1649–1655.
- 43. Zuluaga AF, Galvis W, Saldarriaga JG, Agudelo M, Salazar BE, Vesga O.** Etiologic diagnosis of chronic osteomyelitis: a prospective study. *Arch Intern Med* 2006;166:95–100.
- 44. Tawfik GM, Dibas M, Dung NM, et al.** Concordance of bone and non-bone specimens in microbiological diagnosis of osteomyelitis: a systematic review and meta-analysis. *J Infect Public Health* 2020;13:1682–1693.
- 45. Yano MH, Klautau GB, da Silva CB, et al.** Improved diagnosis of infection associated with osteosynthesis by use of sonication of fracture fixation implants. *J Clin Microbiol* 2014;52:4176–4182.
- 46. Babic M, Simpfendorfer CS.** Infections of the spine. *Infect Dis Clin North Am* 2017;31:279–297.
- 47. Mylona E, Samarkos M, Kakalou E, Fanourgiakis P, Skoutelis A.** Pyogenic vertebral osteomyelitis: a systematic review of clinical characteristics. *Semin Arthritis Rheum* 2009;39:10–17.
- 48. Marshall J, Bhavan KP, Olsen MA, Fraser VJ, Wright NM, Warren DK.** The impact of prebiopsy antibiotics on pathogen recovery in hematogenous vertebral osteomyelitis. *Clin Infect Dis* 2011;52:867–872.
- 49. Kim CJ, Kang SJ, Yoon D, et al.** Factors influencing culture positivity in pyogenic vertebral osteomyelitis patients with prior antibiotic exposure. *Antimicrob Agents Chemother* 2015;59:2470–2473.
- 50. Sertic M, Parkes L, Mattiassi S, Pritzker K, Gardam M, Murphy K.** The efficacy of computed tomography-guided percutaneous spine biopsies in determining a causative organism in cases of suspected infection: a systematic review. *Can Assoc Radiol J* 2019;70:96–103.
- 51. Kasalak Ö, Wouthuyzen-Bakker M, Adams HJA, et al.** CT-guided biopsy in suspected spondylodiscitis: microbiological yield, impact on antimicrobial treatment, and relationship with outcome. *Skeletal Radiol* 2018;47:1383–1391.
- 52. Sehn JK, Gilula LA.** Percutaneous needle biopsy in diagnosis and identification of causative organisms in cases of suspected vertebral osteomyelitis. *Eur J Radiol* 2012;81:940–946.
- 53. Diffre C, Jousset C, Roux AL, et al.** Predictive factors for positive disco-vertebral biopsy culture in pyogenic vertebral osteomyelitis, and impact of fluoroscopic versus scanographic guidance. *BMC Infect Dis* 2020;20:512.
- 54. Enoch DA, Cargill JS, Laing R, Herbert S, Corrah TW, Brown NM.** Value of CT-guided biopsy in the diagnosis of septic discitis. *J Clin Pathol* 2008;61:750–753.
- 55. Terreaux W, Geoffroy M, Ohl X, et al.** Diagnostic contribution of a second percutaneous needle biopsy in patients with spontaneous diskitis and negative blood cultures and first biopsy. *Joint Bone Spine* 2016;83:715–719.
- 56. Kasalak Ö, Adams HJA, Jutte PC, et al.** Culture yield of repeat percutaneous image-guided biopsy after a negative initial biopsy in suspected spondylodiscitis: a systematic review. *Skeletal Radiol* 2018;47:1327–1335.
- 57. Kim CJ, Kang SJ, Choe PG, et al.** Which tissues are best for microbiological diagnosis in patients with pyogenic vertebral osteomyelitis undergoing needle biopsy? *Clin Microbiol Infect* 2015;21:931–935.
- 58. Chang CY, Simeone FJ, Nelson SB, Taneja AK, Huang AJ.** Is biopsying the paravertebral soft tissue as effective as biopsying the disk or vertebral endplate? 10-year retrospective review of CT-guided biopsy of diskitis-osteomyelitis. *AJR Am J Roentgenol* 2015;205:123–129.
- 59. Dowdell J, Brochin R, Kim J, et al.** Postoperative spine infection: diagnosis and management. *Global Spine J* 2018;8:375–435.
- 60. McDermott H, Bolger C, Humphreys H.** Postprocedural discitis of the vertebral spine: challenges in diagnosis, treatment and prevention. *J Hosp Infect* 2012;82:152–157.
- 61. Hu X, Lieberman IH.** Revision spine surgery in patients without clinical signs of infection: how often are there occult infections in removed hardware? *Eur Spine J* 2018;27:2491–2495.
- 62. Pumberger M, Bürger J, Strube P, Akgün D, Putzier M.** Unexpected positive cultures in presumed aseptic revision spine surgery using sonication. *Bone Joint J* 2019;101-B:621–624.
- 63. Shifflett GD, Bjerke-Kroll BT, Nwachukwu BU, et al.** Microbiologic profile of infections in presumed aseptic revision spine surgery. *Eur Spine J* 2016;25:3902–3907.
- 64. Steinhaus ME, Salzmann SN, Lovecchio F, et al.** Risk factors for positive cultures in presumed aseptic revision spine surgery. *Spine* 2019;44:177–184.
- 65. Armstrong DG, Boulton AJM, Bus SA.** Diabetic foot ulcers and their recurrence. *N Engl J Med* 2017;376:2367–2375.
- 66. Lavery LA, Ryan EC, Ahn J, et al.** The infected diabetic foot: re-evaluating the Infectious Diseases Society of America Diabetic Foot Infection Classification. *Clin Infect Dis* 2020;70:1573–1579.
- 67. Copeland-Halperin LR, Kaminsky AJ, Bluefield N, Miraliakbari R.** Sample procurement for cultures of infected wounds: a systematic review. *J Wound Care* 2016;25:S4–S6, S8–S10.
- 68. Levine NS, Lindberg RB, Mason AD Jr, Pruitt BA Jr, Colonel.** The quantitative swab culture and smear: a quick, simple method for determining the number of viable aerobic bacteria on open wounds. *J Trauma* 1976;16:89–94.
- 69. Nelson A, Wright-Hughes A, Backhouse MR, et al; CODIFI collaborators.** CODIFI (Concordance in Diabetic Foot Ulcer Infection): a cross-sectional study of wound swab versus tissue sampling in infected diabetic foot ulcers in England. *BMJ Open* 2018;8:e019437.

- 70. Senneville E, Melliez H, Beltrand E, et al.** Culture of percutaneous bone biopsy specimens for diagnosis of diabetic foot osteomyelitis: concordance with ulcer swab cultures. *Clin Infect Dis* 2006;42:57–62.
- 71. Chakraborti C, Le C, Yanofsky A.** Sensitivity of superficial cultures in lower extremity wounds. *J Hosp Med* 2010;5:415–420.
- 72. Perry CR, Pearson RL, Miller GA.** Accuracy of cultures of material from swabbing of the superficial aspect of the wound and needle biopsy in the preoperative assessment of osteomyelitis. *J Bone Joint Surg Am* 1991;73:745–749.
- 73. Kessler L, Piemont Y, Ortega F, et al.** Comparison of microbiological results of needle puncture vs. superficial swab in infected diabetic foot ulcer with osteomyelitis. *Diabet Med* 2006;23:99–102.
- 74. Manas AB, Taori S, Ahluwalia R, et al.** Admission time deep swab specimens compared with surgical bone sampling in hospitalized individuals with diabetic foot osteomyelitis and soft tissue infection. *Int J Low Extrem Wounds* 2020. doi:10.1177/1534734620916386 [Epub ahead of print].
- 75. Senneville E, Morant H, Descamps D, et al.** Needle puncture and transcutaneous bone biopsy cultures are inconsistent in patients with diabetes and suspected osteomyelitis of the foot. *Clin Infect Dis* 2009;48:888–893.
- 76. Schechter MC, Ali MK, Risk BB, Singer AD, Santamarina G, Rogers HK, et al.** Percutaneous bone biopsy for diabetic foot osteomyelitis: a systematic review and meta-analysis. *Open Forum Infect Dis* 2020;7:ofaa393.
- 77. Lipsky BA, Senneville E, Abbas ZG, Aragón-Sánchez J, Diggle M, Embil JM, et al.** International Working Group on the Diabetic Foot (IWGDF) Guideline on the diagnosis and treatment of foot infection in persons with diabetes 2019. <https://iwgdfguidelines.org/wp-content/uploads/2019/05/05-IWGDF-infection-guideline-2019.pdf> (date last accessed 6th March 2021).
- 78. Hingorani A, LaMuraglia GM, Henke P, et al.** The management of diabetic foot: a clinical practice guideline by the Society for Vascular Surgery in collaboration with the American Podiatric Medical Association and the Society for Vascular Medicine. *J Vasc Surg* 2016;63:3S–21S.
- 79. Lipsky BA, Berendt AR, Cornia PB, et al; Infectious Diseases Society of America.** 2012 Infectious Diseases Society of America clinical practice guideline for the diagnosis and treatment of diabetic foot infections. *Clin Infect Dis* 2012;54:e132–e173.
- 80. Kosmopoulou OA, Dumont IJ.** Feasibility of percutaneous bone biopsy as part of the management of diabetic foot osteomyelitis in a 100% neuropathic, Grade 3 IDSA/IWGDF population on an outpatient basis. *Int J Low Extrem Wounds* 2020;19:382–387.
- 81. Chen AF, Menz M, Cavanaugh PK, Parvizi J.** Method of intraoperative tissue sampling for culture has an effect on contamination risk. *Knee Surg Sports Traumatol Arthrosc.* 2016 Oct;24(10):3075–3079.
- 82. Hughes JG, Vetter EA, Patel R, et al.** Culture with BACTEC Peds Plus/F bottle compared with conventional methods for detection of bacteria in synovial fluid. *J Clin Microbiol* 2001;39:4468–4471.
- 83. Cohen D, Natshe A, Ben Chetrit E, Lebel E, Breuer GS.** Synovial fluid culture: agar plates vs. blood culture bottles for microbiological identification. *Clin Rheumatol* 2020;39:275–279.
- 84. Geller JA, MacCallum KP, Murtaugh TS, Patrick DA Jr, Liabaud B, Jonna VK.** Prospective comparison of blood culture bottles and conventional swabs for microbial identification of suspected periprosthetic joint infection. *J Arthroplasty* 2016;31:1779–1783.
- 85. Font-Vizcarra L, García S, Martínez-Pastor JC, Sierra JM, Soriano A.** Blood culture flasks for culturing synovial fluid in prosthetic joint infections. *Clin Orthop Relat Res* 2010;468:2238–2243.
- 86. Bémer P, Léger J, Tandé D, et al; Centre de Référence des Infections Ostéo-articulaires du Grand Ouest (CRIOGO) Study Team.** How many samples and how many culture media to diagnose a prosthetic joint infection: a clinical and microbiological prospective multicenter study. *J Clin Microbiol* 2016;54:385–391.
- 87. Larsen LH, Lange J, Xu Y, Schønheyder HC.** Optimizing culture methods for diagnosis of prosthetic joint infections: a summary of modifications and improvements reported since 1995. *J Med Microbiol* 2012;61:309–316.
- 88. Schafer P, Fink B, Sandow D, Margull A, Berger I, Frommelt L.** Prolonged bacterial culture to identify late periprosthetic joint infection: a promising strategy. *Clin Infect Dis* 2008;47:1403–1409.
- 89. Minassian AM, Newnham R, Kalimeris E, Bejon P, Atkins BL, Bowler IC.** Use of an automated blood culture system (BD BACTEC™) for diagnosis of prosthetic joint infections: easy and fast. *BMC Infect Dis* 2014;14:233.
- 90. Sanabria A, Røkeberg MEO, Johannessen M, Sollid JE, Simonsen GS, Hanssen AM.** Culturing periprosthetic tissue in BacT/Alert® Virtuo blood culture system leads to improved and faster detection of prosthetic joint infections. *BMC Infect Dis* 2019;19:607.
- 91. Li C, Ojeda-Thies C, Trampuz A.** Culture of periprosthetic tissue in blood culture bottles for diagnosing periprosthetic joint infection. *BMC Musculoskelet Disord* 2019;20:299.
- 92. Peel TN, Dylla BL, Hughes JG, Lynch DT, Greenwood-Quaintance KE, Cheng AC, et al.** Improved diagnosis of prosthetic joint infection by culturing periprosthetic tissue specimens in blood culture bottles. *mBio* 2016;7:e01776-15.
- 93. Hughes HC, Newnham R, Athanassou N, Atkins BL, Bejon P, Bowler IC.** Microbiological diagnosis of prosthetic joint infections: a prospective evaluation of four bacterial culture media in the routine laboratory. *Clin Microbiol Infect* 2011;17:1528–1530.
- 94. Duployez C, Wallet F, Migaud H, Senneville E, Loiez C.** Culturing periprosthetic tissues in BacT/Alert® Virtuo blood culture bottles for a short duration of post-operative empirical antibiotic therapy. *J Bone Jt Infect* 2020;5:145–150.
- 95. Trampuz A, Piper KE, Hanssen AD, et al.** Sonication of explanted prosthetic components in bags for diagnosis of prosthetic joint infection is associated with risk of contamination. *J Clin Microbiol* 2006;44:628–631.
- 96. Trampuz A, Piper KE, Jacobson MJ, Hanssen AD, Unni KK, Osmon DR, et al.** Sonication of removed hip and knee prostheses for diagnosis of infection. *N Engl J Med* 2007;357(7):654–663.