



Preoperative glenoid considerations for shoulder arthroplasty: a review

Stephen Gates
Brain Sager
Michael Khazzam

- Preoperative assessment of the glenoid in the setting of shoulder arthroplasty is critical to account for variations in glenoid morphology, wear, version, inclination, and glenohumeral subluxation.
- Three-dimensional computed tomography (3D CT) scan assessment of the morphology of glenoid erosion allows for a more accurate surgical decision-making process to correct deformity and restore the joint line.
- Newer technology has brought forth computer-assisted software for glenoid planning in shoulder arthroplasty and patient-specific instrumentation.
- There have been promising early findings, although further evaluation is needed to determine how this technology impacts implant survivorship, function, and patient-reported outcomes.

Keywords: glenoid classification; glenoid deformity; preoperative planning; shoulder arthroplasty; shoulder 3D CT scan

Cite this article: *EFORT Open Rev* 2020;5:126-137.
DOI: 10.1302/2058-5241.5.190011

Introduction

Thorough understanding of the impact of glenohumeral joint pathology on glenoid morphology is important in the predictability of implant survivorship and outcome following total shoulder arthroplasty. Preoperative radiographic evaluation of the glenoid has become pivotal in terms of proper surgical planning, implant choice, methods to correct deformity, and surgical technique. The volume of shoulder arthroplasty being performed continues increasing at a rate which is comparable to those for hip and knee arthroplasty procedures.¹ The purpose of this review is to provide a summary of current methods for assessment of the glenoid and preoperative planning strategies for total shoulder arthroplasty.

Radiographic imaging modalities

Plain radiographs

Evaluation of the glenohumeral joint begins with plain radiographs. The true anteroposterior (AP) view aids in determining the presence of arthritis, evidenced by joint space narrowing, osteophytes, subchondral sclerosis, and subchondral cysts. The plain radiograph provides a tremendous amount of information as to the aetiology of the degenerative process. For example, superior proximal humeral head migration in relation to the glenoid, as well as acetabularization of the undersurface of the acromion suggests arthrosis related to pathology involving the rotator cuff. Changes in arm position (internal and external rotation) can provide further visualization of the severity of proximal humeral head migration. It is important to obtain an axillary X-ray in which the glenoid is not obscured by overlap of the acromion. At times this can be difficult to consistently reproduce, and fluoroscopic imaging can be a useful tool to aid in obtaining this image. The axillary view aids in determining the presence of glenoid wear anteriorly or posteriorly, humeral head subluxation, or dislocation of the glenohumeral joint.

Computed tomography (CT)

Computed tomography (CT) scan is a very useful tool for characterization of glenoid morphology.^{2,3} CT scan provides an accurate and detailed assessment of the glenoid with regard to version, inclination, wear pattern and direction/location, bone quality, as well as integrity of the glenoid vault. Proper preoperative understanding of these factors provides information to guide implant choice as well as morphological aspects of the glenoid that affects implant survival.⁴⁻⁶

Initial characterization of glenoid bone loss pattern is performed using two-dimensional (2D) CT scan images. 2D CT scans can be reconstructed into different planes. They can also be used to create three-dimensional (3D) reconstructed images, which aid in understanding and

defining patient-specific glenoid anatomy and location of wear, as well as enhancing the precision of glenoid component positioning.^{7,8} Werner et al showed that measurements of glenoid version and inclination were more accurate with 3D reconstruction measurements compared with reformatted 2D CT scans. In fact, they noted that surgical planning and implant choice was altered for 7 of 50 shoulders after reassessing glenoid morphology via 3D reconstructive imaging.⁹

A recent radiographic analysis by Chalmers et al postulated that inclusion of only 8 cm of scapular width and 50% of scapular height is needed to ensure accurate glenoid measurements are made.¹⁰ Despite the study by Chalmers et al suggesting that the exclusion of the vertebral scapular border and inferior scapular angle is satisfactory to assess the glenoid, certain measurements discussed in this review rely on these and other anatomic landmarks. Additionally, 3D CT scan of the contralateral shoulder can be obtained in cases of ambiguity.

Magnetic resonance imaging (MRI)

With a higher tissue-contrast resolution than seen on CT scan, magnetic resonance imaging (MRI) provides a superior means for assessing soft tissue pathology, and is the gold standard for evaluation of rotator cuff disorders.¹¹ MRI has been used for preoperative assessment of glenoid version, avoiding the need to undertake the additional cost, time, and radiation associated with obtaining a CT scan in a patient who already has an adequate MRI.¹² Lowe et al compared MRI to CT for preoperative shoulder arthroplasty assessment, and found that MRI and CT were comparable for glenoid version measurements with less severe deformity types.¹³ However, MRI significantly under identified type B2 and over identified type C glenoid deformities when compared with CT, refuting the idea that MRI could replace the utility of a CT in certain circumstances.¹³

Glenoid measurements

Glenoid wear

Walch et al, in 1999 outlined a classification scheme of glenoid wear patterns seen in primary glenohumeral arthritis.² The prognostic value of the Walch classification has also been substantiated, with a higher Walch classification acting as a negative predictor for postoperative clinical function, as well as progression of posterior bone loss over time.^{14,15}

Friedman et al demonstrated that CT scans accurately revealed glenoid erosion patterns in patients with severe glenohumeral osteoarthritis.³ In the original study by Walch, glenoid morphology in the setting of primary glenohumeral arthritis was assigned as types A, B, or C glenoid wear.²

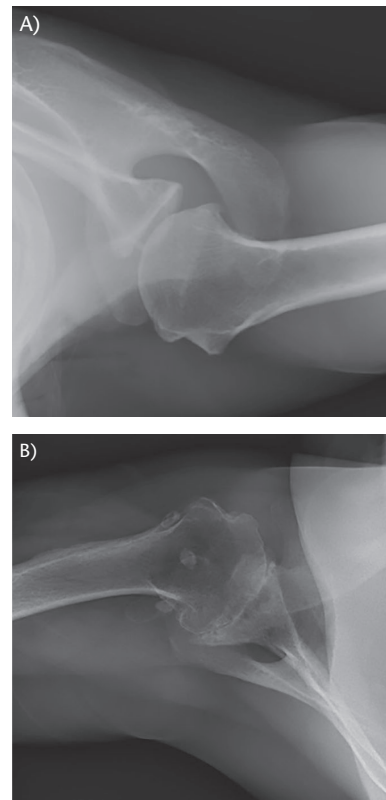


Fig. 1 (A) Type A1 glenoid on an axillary lateral radiograph of a left shoulder, characterized by a well-centred humeral head with mild, symmetric glenoid erosion in the absence of glenohumeral subluxation. (B) Type A2 glenoid on an axillary lateral radiograph of a right shoulder, characterized by deeper, symmetric glenoid erosion in which a line connecting the anterior and posterior glenoid rims would transect the humeral head.

Fifty-nine per cent of 113 shoulders evaluated using CT images were defined as type A, describing a humeral head well centred on the glenoid with symmetric erosion in the absence of humeral head subluxation on the glenoid (Fig. 1). This was further subclassified to A1 and A2, signifying minor glenoid erosion or deeper central erosion, respectively, with the latter being a typical finding of inflammatory arthropathy.^{2,16} A more recent study further clarifies the definition of the A2 glenoid as one in which a line connecting the anterior and posterior glenoid rims in the axial plane transects the humeral head, as would be seen with deeper central glenoid erosion.¹⁷

In contrast, 32% of shoulders were defined as type B, which described posterior subluxation of the humeral head on the glenoid, resulting in asymmetric glenoid loading and subsequent posterior arthritic wear patterns (Fig. 2). More specifically, B1 identified posterior wear without significant glenoid erosion, while B2 identified those with posterior glenoid erosion resulting in the characteristic biconcave glenoid.² The posterior glenoid erosion in the B2 results in biconcavity with the creation of a

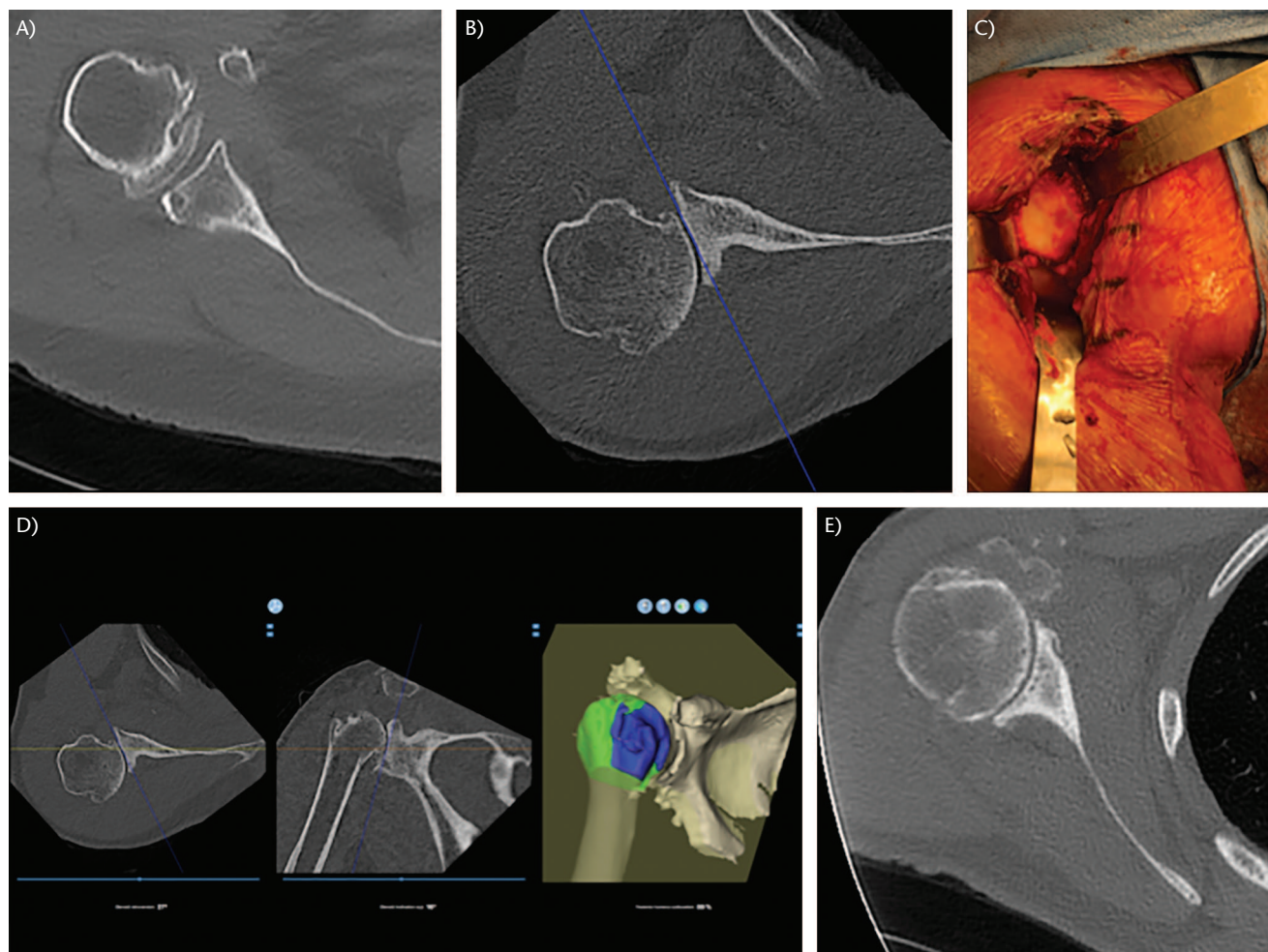


Fig. 2 (A) Type B1 glenoid on axial CT, characterized by posterior glenoid wear without significant glenoid erosion; note the subchondral cyst beneath the posterior glenoid articular surface. (B) Type B2 glenoid on axial CT, characterized by posterior subluxation of the humeral head on the glenoid, with subsequent posterior glenoid erosion and a characteristic biconcave appearance. (C) In vivo B2 glenoid during a right shoulder arthroplasty, with characteristic biconcave appearance with increased wear and sclerosis on posterior aspect of glenoid (left side of picture). (D) Type B2 glenoid uploaded into preoperative planning software, showing calculated glenoid version, glenoid inclination, and posterior humeral head subluxation measurements, respectively (BLUEPRINT, Wright Medical, Memphis, TN, USA). (E) Type B3 glenoid on axial CT, characterized by progression of posterior wear leading to an excessively retroverted, monoconcave glenoid.

neoglenoid which is posterior and inferior as well as the paleoglenoid which is the prepathologic joint line. Bercik et al used 3D CT reconstructions and analysed 129 shoulders to more clearly outline glenoid pathologic wear patterns in glenohumeral osteoarthritis. This included the addition of the B3 glenoid, which is defined as monoconcave with posterior wear, greater than 15 degrees of retroversion, and posterior humeral head subluxation greater than 70% of the humeral head related to the glenoid.¹⁷ The B3 glenoid is the natural progression of continued posterior glenoid wear of a B2 with loss of the paleoglenoid and enlargement of the neoglenoid. Chan et al further analysed 52 patients with B3 glenoids via 3D CT, and found mean values of 24 ± 7 degrees of retroversion, 8 ± 6

degrees of superior inclination, and 14 ± 4 mm of medialization.¹⁶ This study also illustrated that when glenohumeral subluxation is evaluated based on the glenoid plane, despite increasing glenoid erosion and retroversion, the humeral head appears concentric on the glenoid. This is in contrast to what is seen when referencing the scapular plane, where every 1 degree increase in glenoid retroversion translates to an equivalent 1% increase in humeral head subluxation.¹⁶

Nine per cent of Walch's original 113 shoulders were classified as type C, which is developmental dysplasia of the posterior glenoid (or posterior glenoid hypoplasia), characterized by greater than 25 degrees of retroversion (Fig. 3).² While this morphologic pattern can be difficult to

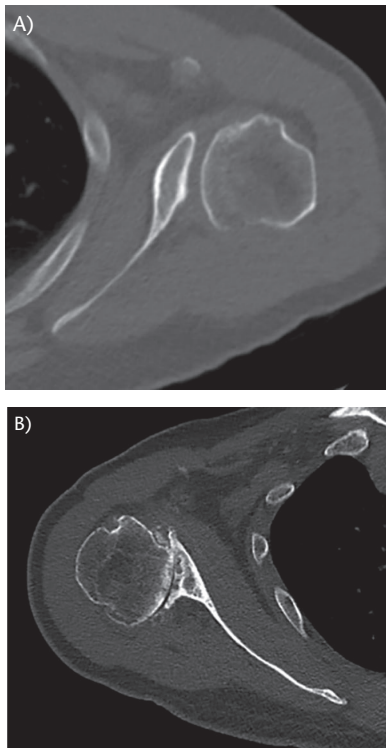


Fig. 3 (A) Type C1 glenoid on axial CT, characterized by dysplastic glenoid retroversion greater than 25 degrees. (B) Type C2 glenoid on axial CT, characterized by a dysplastic, high premorbid glenoid retroversion in addition to degenerative posterior glenoid wear resulting in biconcavity.

delineate from type A2 or B3 glenoids, initially described type C glenoids commonly have characteristics of generalized preserved joint space, minimal osteophytes, and absence of a posterior glenoid neck associated with posteroinferior glenoid hypoplasia.¹⁶ Type C glenoids have since been subdivided further. A C1 glenoid represents the aforementioned dysplastic glenoid retroversion, while Iannotti et al recently defined a C2 glenoid as one with congenitally high premorbid glenoid retroversion in addition to acquired posterior bone loss.¹⁸ This posterior bone loss results in a biconcave glenoid surface with associated posterior humeral head subluxation, a finding similar to that of the B2 glenoid. However, both premorbid (mean 19.4 degrees) and pathologic (mean 28.5 degrees) glenoid retroversion are significantly greater in type C2 glenoids when compared with B2.¹⁸

Bercik et al also introduced the idea of a rare type D glenoid, defined as one with glenoid anteversion or anterior humeral head subluxation and a Walch index less than 40%, described later (Fig. 4). With the addition of the B3 and D type glenoids, this study was able to show statistically significant improvement in both interobserver and intraobserver reliabilities on preoperative glenoid wear measurements.¹⁷

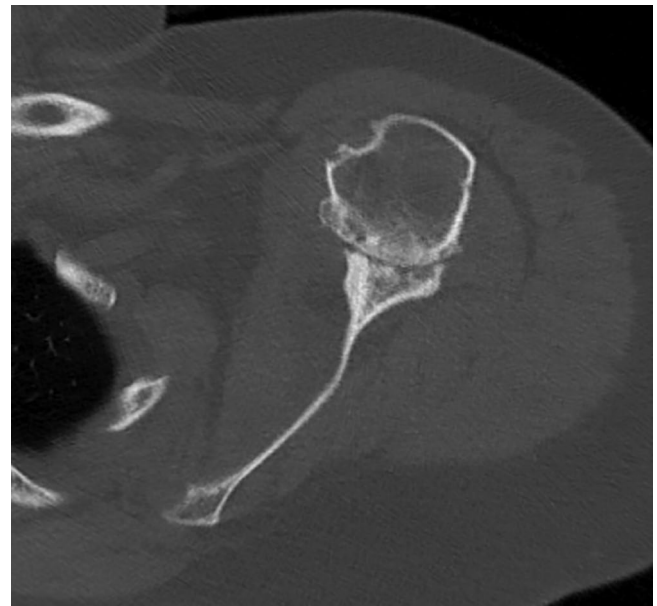


Fig. 4 Type D glenoid on axial CT, which, while rare, is characterized by glenoid anteversion.

Rotator cuff arthropathy creates glenoid wear in the coronal plane due to proximal humeral head migration. Lévine et al implemented the Favard classification (Fig. 5) to assess coronal plane glenoid erosion.¹⁹ Delineated as the E classification, a type E0 glenoid corresponds to superior humeral head migration without glenoid erosion, E1 with concentric glenoid erosion, E2 with superior erosion limited to the superior glenoid (biconcavity in the coronal plane), E3 with erosion extending to the inferior glenoid edge (significant superior inclination), and E4 with glenoid erosion isolated only to the inferior part of the glenoid.¹⁹ Identifying these erosion deformities has implications in glenoid bone loss management, appropriate implant placement, correction of superior inclination and joint line medialization, and prevention of scapular notching. Correction of this deformity avoids sites of scapular pillar impingement which can restrict shoulder range of motion in the setting of reverse shoulder arthroplasty.^{20,21}

Glenoid version

Preoperative glenoid version has a direct correlation to glenoid component survivorship and patient outcomes. Farron et al demonstrated that glenoid component placement into greater than 10 degrees of retroversion results in increased bone-cement interface micromotion and component loosening.²² Similarly, Shapiro et al, in a cadaveric study, found that excessive retroversion of 15 degrees results in eccentric glenoid loading, significantly decreased glenohumeral contact area, and increased contact pressure which leads to wear and loosening.²³ Augmented glenoid component designs provide options to correct

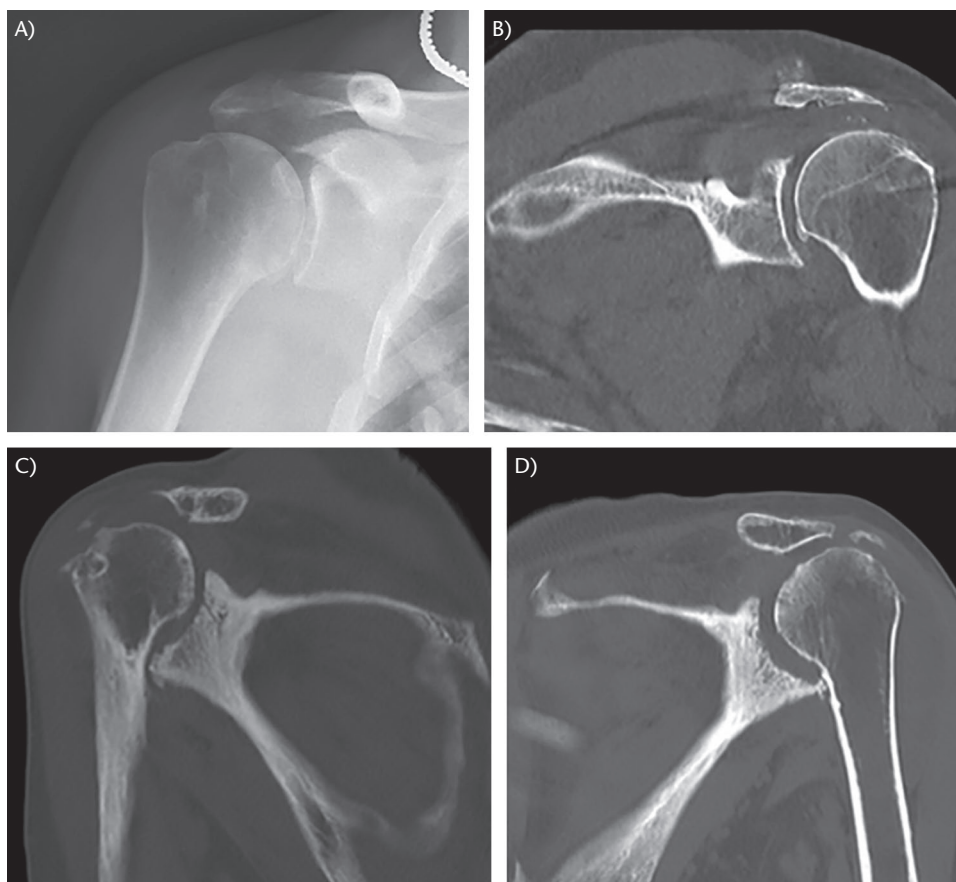


Fig. 5 Favard type E glenoids. (A) E0: superior humeral head migration without glenoid erosion, on true AP radiograph. (B) E1: concentric glenoid erosion, on coronal CT. (C) E2: superior erosion limited to the superior glenoid, on coronal CT. (D) E3: erosion extending to the inferior glenoid edge, on coronal CT.

version to prevent the adverse effects of excessively retroverted glenoid components.²⁴

Glenoid version is best assessed in the axial plane. Whereas axillary view shoulder radiographs can be used, they have been shown to overestimate glenoid retroversion by as much as 86% when compared with CT imaging.²⁵ Axial radiographs are technique dependent and frequently not consistent nor reproducible, making them a difficult tool to use reliably. Two-dimensional CT imaging, selecting the image just below the coracoid process ensures that a consistent measurement is obtained.²⁶ Several methods exist for evaluating glenoid version on the axial CT (Fig. 6). Friedman et al defined the glenoid version as the angle formed between the glenoid line and the line perpendicular to the scapular axis, defined as the line joining the medial edge of the scapula and the centre of the glenoid.³ The angle formed between the intersection of the scapular body and the glenoid surface is the method of assessing version based on the scapular body axis (scapular body method). An alternative axis has been proposed to measure glenoid version. Bouacida et al, developed the

glenoid hull plane in which version is measured between the glenoid line and a line perpendicular to that joining the centre of the glenoid and the point of the scapula where the anterior and posterior cortices meet medially, called the hull.²⁷

The glenoid line connects the anterior and posterior edges of the glenoid but can become more difficult to measure in the presence of glenoid wear and erosion. Three reference lines have been described. The paleoglenoid assumes the morphology of the native glenoid and does not consider posterior wear or erosion. The neoglenoid does consider posterior erosion, and its line is drawn from the anterior-most to posterior-most portions of the deformed glenoid facet. The intermediate glenoid describes a line drawn from the anterior to posterior edge of the glenoid regardless of wear or erosion.²⁶ Rouleau et al found that, especially when measuring glenoids with posterior wear, the interobserver and intraobserver reliability was highest when using Friedman's scapular plane and the intermediate glenoid when measuring glenoid version. The same study also found no advantage to 3D reconstructed

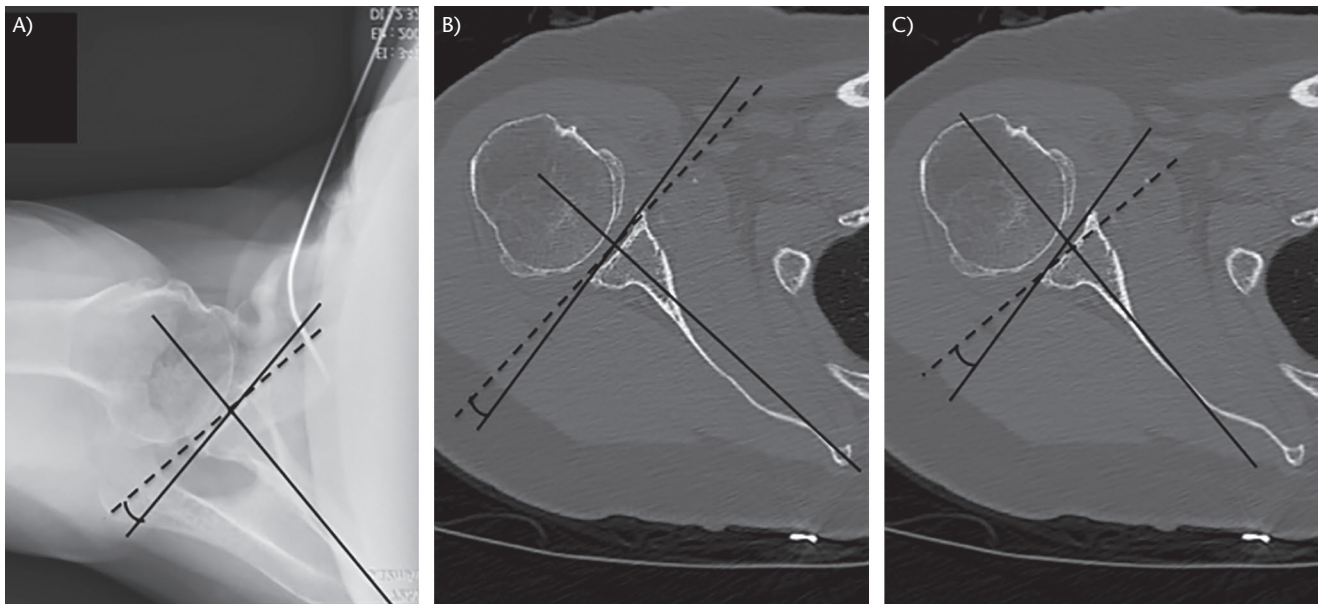


Fig. 6 (A) Glenoid version as measured on an axillary right shoulder radiograph using the Friedman method, where version is the angle between the glenoid line and the perpendicular (dashed) to the line joining the medial edge of the scapula and the centre of the glenoid (scapular axis). (B) Glenoid version as measured on axial CT using the Friedman method, where version is the angle between the glenoid line and the perpendicular (dashed) to the line joining the medial edge of the scapula and the centre of the glenoid (scapular axis). (C) Glenoid version as measured on axial CT using the glenoid hull method, where version is measured in a similar way to the Friedman method, but with the glenoid hull plane (the line between the centre of the glenoid and the point of the scapula where the anterior and posterior cortices meet medially) replacing the scapular axis.

CT scans over their 2D counterparts.²⁶ Alternatively, in a study by Walch et al, use of the neoglenoid in calculating retroversion best predicted postoperative complications of glenoid component loosening and periprosthetic dislocation.²⁸ More specifically, neoglenoid retroversion of greater than 27 degrees in biconcave glenoids led to a 44% risk of complication at an average six-year follow up.²⁸ Still, the extent of intermediate glenoid retroversion also significantly correlated with glenoid loosening and is commonly used to assess version.²⁸

Glenoid inclination

Glenoid inclination can be measured on AP shoulder radiographs, 2D CT scans, and 2D CT scans reformatted to the scapular plane. Daggett et al showed less accuracy and less reliability with beta angle measurements using AP radiographs when compared to 2D scapular plane reconstructions using 3D software measurement as the accurate accepted value.²⁹ Contrastingly, Maurer et al proposed that the beta angle was the most reproducible measurement for glenoid inclination on an AP radiograph, with strong reproducibility despite variations of up to 20 degrees of rotation.³⁰

Glenoid inclination is typically described as a positive number for superior inclination and a negative number

for inferior declination. Minimal clinical evidence exists to establish an ideal range, or the clinical manifestations in deviating from this range, but increased risk of glenoid component failure has been shown to be associated with components placed in superior inclination.^{29–31} Churchill et al defined glenoid inclination as the angle formed between the glenoid line (joining the superior and inferior glenoid rims) and that perpendicular to the line joining the medial angle of the scapula and the centre of the glenoid.³² Using the method described by Maurer et al, the beta angle is obtained from the intersection of the glenoid line and the tangential line through the floor of the supraspinous fossa (Fig. 7A).³⁰ Glenoid inclination is then calculated as the beta angle subtracted from 90, representing the line perpendicular to that which is tangential to the fossa.

Daggett et al showed a statistically significant correlation between glenoid inclination and a measurement named the critical shoulder angle (CSA).³³ The critical shoulder angle is defined as the intersection angle at the inferior glenoid margin between the glenoid line and the line drawn from the inferior bony margin of the glenoid to the lateral-most border of the acromion on AP radiographs (Fig. 7B).³⁴ The measurement takes into consideration both acromial coverage as well as glenoid inclination, and

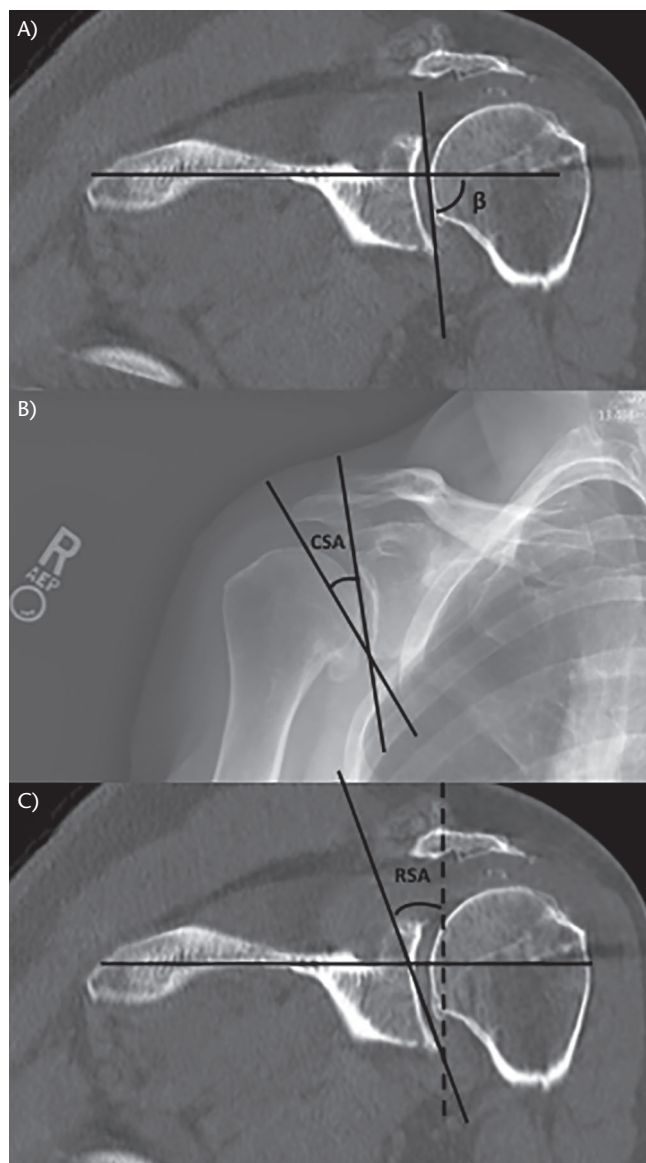


Fig. 7 (A) Glenoid inclination as measured on a coronal CT of a left shoulder using the beta angle, which is the angle formed by the intersection of the glenoid line and the tangential line through the floor of the supraspinous fossa. The value of inclination is then calculated as the beta angle subtracted from 90. (B) The critical shoulder angle (CSA) shown on a true shoulder anteroposterior radiograph, defined as the intersection angle at the inferior glenoid margin between the glenoid line and the line drawn from the inferior bony margin of the glenoid to the lateral-most border of the acromion. (C) The reverse shoulder (RSA) angle measured on a coronal CT of a left shoulder, defined as the angle between the perpendicular (dashed line) of the tangential line through the floor of the supraspinous fossa and the line through the inferior glenoid fossa (connecting the inferior glenoid rim to the intersection of the supraspinous fossa tangential line and the glenoid rim).

is predictive for recognizing shoulders with degenerative rotator cuff tears or primary osteoarthritis. This study showed a mean CSA of 33.1 degrees in an asymptomatic control group without arthritic changes and a normal rotator cuff, whereas a CSA greater than 35 degrees favoured rotator cuff pathology (84% positive predictive value) and a CSA less than 30 degrees favoured osteoarthritis (90% positive predictive value).³⁴ Translated to glenoid inclination, shoulders with massive rotator cuff tears demonstrate significantly increased glenoid inclination measurements relative to osteoarthritic shoulders, with measurements of 13.6 ± 4.6 degrees and 7.6 ± 5.01 degrees, respectively.³³

Boileau et al recently proposed the reverse shoulder arthroplasty (RSA) angle, which is the angle created from the line of the inferior glenoid fossa and the perpendicular of the tangential line through the floor of the supraspinous fossa (Fig. 7C). In considering only the inferior aspect of the glenoid fossa (where a shoulder arthroplasty component would be appropriately implanted), they argue that use of the RSA angle avoids underestimating the focal inclination at the location of baseplate implantation and prevents insufficient correction of superior tilt which occurs when considering solely the global glenoid inclination represented by the beta angle.³⁵ The subsequent use of trapezoidal-shaped angled bony-increased offset (BIO)-RSA techniques dictated by the RSA angle led to predictable correction of multiplanar glenoid deformity and good clinical outcomes.³⁵

Glenohumeral alignment

Increased preoperative posterior humeral head subluxation has been shown to be a significant risk factor associated with glenoid component loosening, and asymmetric polyethylene wear as a result of recurrent posterior humeral head subluxation following anatomic total shoulder arthroplasty.³⁶ Biomechanical testing shows that the degree of posterior humeral head subluxation is directly correlated to severity of posterior glenoid wear.^{27,37} Walch et al examined the preoperative radiographic predictors associated with an increase in postoperative complications following anatomic total shoulder arthroplasty (TSA) in patients with posterior glenoid erosion. This study retrospectively reviewed 92 shoulders that underwent preoperative CT arthrograms and subsequent anatomic total shoulder arthroplasties, and found a 16.3% (15/92) revision rate at six-year follow up.²⁸ Glenoid loosening was observed in 20.6% of shoulders and correlated with posterior humeral head subluxation, neoglenoid retroversion ($> 27^\circ$ retroversion associated with 44% risk of complication), intermediate glenoid retroversion $> 30^\circ$ (62% risk of complications),

and posterior glenoid erosion depth.²⁸ The authors concluded that intermediate glenoid retroversion of $> 30^\circ$ is associated with a $> 50\%$ risk of glenoid component loosening. Posterior humeral head subluxation of $> 80\%$ is associated with an 11% risk of posterior dislocation.²⁸ A 2003 multicentre case series showed that patients with posterior humeral head subluxation following anatomic shoulder arthroplasty had more pain, decreased active external rotation, and worse American Shoulder and Elbow Surgeons scores.³⁸

Jacxsens et al³⁹ examined posterior humeral head decentring in relation to the glenoid on preoperative CT scans in patients with glenohumeral joint osteoarthritis. The authors attempted to correlate glenohumeral subluxation index seen in 3D reconstructed CT scans to the Walch classification and measured humeral head subluxation as it relates to the glenoid surface, seen on the axial 2D CT image. In their method, humeral head subluxation is measured as per the Walch index; a ratio where a value between 45–55% defines a well-centred humeral head (Fig. 8A). Contrastingly, indexes of less than 45% or greater than 55% denote anterior or posterior subluxation, respectively.²

Bouacida et al compared the humeral head subluxation measurement method to the glenoid hull plane.²⁷ In their study, 2D CT scans reconstructed in both the anatomic scapular plane and glenoid hull plane compared 109 shoulders with glenohumeral osteoarthritis to 97 control shoulders without arthritis. The glenoid hull method describes the frontal plane as encompassing the hull and the Saller line; a line connecting the superior-most point of the glenoid rim to the inferior-most point of the glenoid rim. The axial plane is then reconstructed parallel to the floor of the supraspinatus fossa and perpendicularly through the middle of the Saller line seen in the sagittal plane. To measure the humeral head subluxation index in the hull plane, the line connecting the centre of the glenoid to the hull is used to obtain the ratio, as depicted in Fig. 8B.²⁷

Similar to Walch's original findings, Bouacida et al found that humeral head subluxation increased with increasing Walch classification in all planes with the exception of type C, which had less subluxation than that of B2. They also found that A2 glenoids based on the glenoid plane had significantly higher standard deviations for amount of humeral head subluxation, with 35% of type A2 glenoids showing greater than 75% humeral head subluxation in the glenoid hull plane. Further investigation revealed that A2 glenoids could be categorized as 'centric' type or 'eccentric' type, and that the hull method identified the former as in fact corresponding to a type B3 glenoid.²⁷ In this sense, the glenoid and scapular planes are suboptimal for differentiating the B3 glenoid, whereas the glenoid hull measurement discriminates

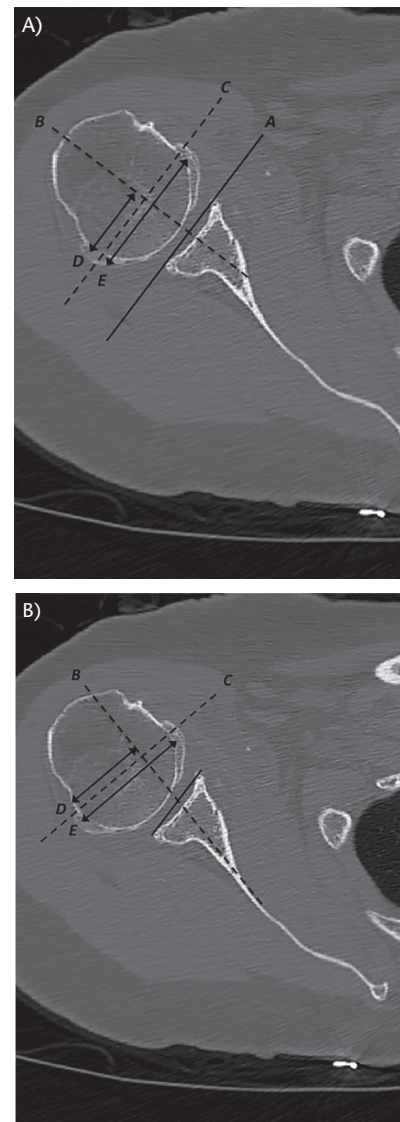


Fig. 8 (A) The Walch index for glenohumeral subluxation, defined as the ratio of line *D* to *E*, where line *A* refers to the glenoid line, *B* to its perpendicular which bisects the glenoid, *C* to a line parallel with *A* transecting the medial third of the humeral head, and lines *D* and *E* represent humeral head measurements along line *C* posterior to line *C* and from anterior-posterior humeral head, respectively. (B) Scapulohumeral subluxation index, measured using the glenoid hull plane. The measurement is again obtained by the ratio of line *D* to *E*, where line *B* is replaced by the line along the glenoid hull plane (connecting the centre of the glenoid and the point of the scapula where the anterior and posterior cortices meet medially) and line *C* transects the medial third of the humeral head and is perpendicular to line *B*. Lines *D* and *E* again represent humeral head measurements along line *C* posterior to line *C* and from anterior-posterior humeral head, respectively.

between true A2 glenoids (retroversion in hull plane of 7.5 ± 7.2 degrees) and B3 glenoids (retroversion in hull plane of 25.6 ± 6 degrees).²⁷

Patient-specific instrumentation (PSI) and preoperative planning software

Computer-assisted preoperative planning has emerged as a means of relying on quantitative information to facilitate intraoperative decision-making and hardware implantation.⁴⁰ Accurate glenoid component positioning, especially in the setting of significant deformity such as B2/B3 glenoid, is one of the more difficult intraoperative challenges which directly impacts implant survivorship as well as functional outcome.

In response to these challenges, software has been developed to help identify glenoid deformity as well as guide implant selection. These software programs are also useful to create patient-specific guides to improve the accuracy of implant positioning. Typically, the software utilizes a CT scan, from which a preoperative plan is designed by surgeons or company associated engineers. The plan is then shipped to the manufacturers, 3D patient-specific instrumentation is printed and returned to the surgeon for use intraoperatively.

Recent studies have focused on use of these preoperative models and their associated patient-specific instrumentation.⁴¹ Simulating glenoid component implantation using bone models created from patients with shoulder arthropathy, Iannotti et al demonstrated improved accuracy of glenoid guide pin position with both preoperative templating and a reusable, adjustable patient-specific guide.⁴² In their study, they reported statistically significant improvement in pin location, version, and inclination when comparing use of 3D preoperative planning software to use of 2D imaging alone. Similarly, the introduction of an adjustable patient-specific guide also led to a statistically significant improvement in pin positioning compared to the use of 3D software alone.⁴² A cadaveric study by Walch et al validated the finding of improved accuracy in glenoid component placement when patient-specific guides are used for guide pin insertion. Reported mean errors between the achieved pin placement and computed 3D software pin position were 1.05 millimetres of translation, 1.64 degrees of version, and 1.42 degrees of inclination.⁴³ Gauci et al further substantiated these findings in vivo, demonstrating reproducible and accurate orientation and positioning of the glenoid component in a series of 17 arthroplasty patients using available preoperative planning software and patient-specific guides.⁴⁴ A brief overview of available preoperative planning software is discussed here.

Codsi et al first described the glenoid vault model in 2008. It is a model that utilized normal cadaveric shoulders of various sizes to create a unique glenoid vault shape with various sizes depending on the size of the individual's scapula.⁴⁵ Scalise et al then analysed this system on arthritic shoulders with the contralateral limb as a control

and found a very close correlation.⁴⁶ Hendel et al compared patient-specific instrumentation produced from this glenoid vault model to standard surgical instrumentation and found that the patient-specific instrumentation allowed for a much more accurate placement of the glenoid implant in terms of inclination and medial-lateral offset. It also significantly improved the final version in patients with a preoperative retroversion of greater than 16 degrees.⁴⁷

The Match Point System (DJO, Austin, TX, USA) is a 3D planning program that can be employed for both anatomic and reverse shoulder arthroplasty. This system utilizes a clip that attaches to the patient's coracoid process to allow for more accurate placement during surgical implantation. This particular system was utilized by Levy et al and was shown to replicate the preoperative planned position within 2.6 degrees of glenoid version and 1.2 degrees of inferior tilt.⁴⁸ Similarly, Dallalana et al showed this system was able to place the glenoid within 1.8 degrees of the planned version and 1.3 degrees of the planned inclination.⁴⁹

Another commonly utilized piece of software, BLUE-PRINT 3D Planning Software (Wright Medical, Memphis, TN, USA), recommends utilizing five principles of glenoid placement for anatomic shoulder arthroplasty: subchondral bone preservation,⁵⁰ less than 10 degrees of glenoid retroversion,⁵¹ less than 10 degrees of glenoid superior inclination,⁵² 80% glenoid implant seating⁵³ and less than 80% of humeral head subluxation.³⁸ Daggett et al compared various imaging modalities in their ability to predict glenoid inclination and found 2D CT scan formatted in the scapular plane using BLUE-PRINT was the most accurate.²⁹ A comparison of measurements was made between the BLUEPRINT and Match Point systems and found no significant difference between the version and inclination measurements produced by the two systems.⁵⁴ Glenosys preoperative planning software (Imascap, Brest, France) uses a validated automated 3D segmentation method to allow angled measurements in simulating glenoid implantation.⁵⁵ Boileau et al recently substantiated the accuracy of the Glenosys system in measuring glenoid version and inclination against previously described and widely accepted manual or semi-automated methods, with no significant differences between the automated and non-automated measurements.⁵⁶

The Signature Glenoid Shoulder System (Zimmer-Biomet, Warsaw, IN, USA) is another technology used to create a patient-specific guide for improved guide pin placement for both anatomic and reverse shoulder arthroplasty. Throckmorton et al demonstrated that utilization of the Signature Glenoid Shoulder System (SGSS) statistically improved the glenoid positioning in both inclination

and version over conventional instrumentation.⁵⁷ On the contrary, Lau and Keith utilized this system for 11 consecutive patients undergoing shoulder arthroplasty and found that five of these had greater than 10 degrees of anteversion or retroversion on final implantation.⁵⁸

Certainly, the abundance of evidence supports the idea that 3D modelling and patient-specific instrumentation is useful for accurate placement of the glenoid component in shoulder arthroplasty. The software is new, however, and current literature may be susceptible to publication bias. Further evaluation must be performed to assess the efficacy of these programs, with subsequent comparison of the different programs to one another.

Conclusion

We recommend preoperative planning start with standardized radiographic series of the glenohumeral joint including AP, true AP, and an axillary view to evaluate glenoid version, inclination, wear pattern/bone loss, and relationship of the humeral head alignment with the glenoid. CT scan with 3D reconstruction provides additional detailed assessment of the glenoid morphology and allows for computer-assisted surgical planning. Preoperative radiographic evaluation of glenoid deformity in the setting of shoulder glenohumeral joint pathology helps the surgeon to plan how correct the glenoid deformity, implant choice, implant survivorship, and outcomes following shoulder arthroplasty. Myriad investigations have focused on defining measurements and preoperative tools to aid in providing increased reliability as well as reproducibility in the surgical planning of TSA.

AUTHOR INFORMATION

Department of Orthopaedic Surgery, Shoulder Service, University of Texas Southwestern Medical Center, Dallas, Texas, USA.

Correspondence should be sent to: Michael Khazzam, University of Texas Southwestern Medical Center, Department of Orthopaedic Surgery, Shoulder Service, 1801 Inwood Road, Dallas, Texas 75390, USA.
Email: Michael.khazzam@utsouthwestern.edu

ICMJE CONFLICT OF INTEREST STATEMENT

MK reports paid board membership of and consultancy for Wright Medical/Tornier outside the submitted work.

The other authors declare no conflict of interest relevant to this work.

FUNDING STATEMENT

No benefits in any form have been received or will be received from a commercial party related directly or indirectly to the subject of this article.

LICENCE

© 2020 The author(s)

This article is distributed under the terms of the Creative Commons Attribution-Non Commercial 4.0 International (CC BY-NC 4.0) licence (<https://creativecommons.org/licenses/by-nc/4.0/>) which permits non-commercial use, reproduction and distribution of the work without further permission provided the original work is attributed.

REFERENCES

1. Day JS, Lau E, Ong KL, Williams GR, Ramsey ML, Kurtz SM. Prevalence and projections of total shoulder and elbow arthroplasty in the United States to 2015. *J Shoulder Elbow Surg* 2010;19:1115–1120.
2. Walch G, Badet R, Boulahia A, Khoury A. Morphologic study of the glenoid in primary glenohumeral osteoarthritis. *J Arthroplasty* 1999;14:756–760.
3. Friedman RJ, Hawthorne KB, Genez BM. The use of computerized tomography in the measurement of glenoid version. *J Bone Joint Surg Am* 1992;74:1032–1037.
4. Jun BJ, Vasanji A, Ricchetti ET, et al. Quantification of regional variations in glenoid trabecular bone architecture and mineralization using clinical computed tomography images. *J Orthop Res* 2018;36: 85–96.
5. Terrier A, Obrist R, Becce F, Farron A. Cement stress predictions after anatomic total shoulder arthroplasty are correlated with preoperative glenoid bone quality. *J Shoulder Elbow Surg* 2017; 26: 1644–1652.
6. Lombardo DJ, Khan J, Prey B, Zhang L, Petersen-Fitts GR, Sabesan VJ. Quantitative assessment and characterization of glenoid bone loss in a spectrum of patients with glenohumeral osteoarthritis. *Musculoskelet Surg* 2016;100:179–185.
7. Hoenecke HR Jr, Hermida JC, Flores-Hernandez C, D'Lima DD. Accuracy of CT-based measurements of glenoid version for total shoulder arthroplasty. *J Shoulder Elbow Surg* 2010;19:166–171.
8. Kwon YW, Powell KA, Yum JK, Brems JJ, Iannotti JP. Use of three-dimensional computed tomography for the analysis of the glenoid anatomy. *J Shoulder Elbow Surg* 2005;14:85–90.
9. Werner BS, Hudek R, Burkhart KJ, Gohlke F. The influence of three-dimensional planning on decision-making in total shoulder arthroplasty. *J Shoulder Elbow Surg* 2017;26:1477–1483.
10. Chalmers PN, Salazar D, Chamberlain A, Keener JD. Radiographic characterization of the B2 glenoid: is inclusion of the entirety of the scapula necessary? *J Shoulder Elbow Surg* 2017;26:855–860.
11. Gyftopoulos S, Rosenberg ZS, Roberts CC, et al. ACR appropriateness criteria imaging after shoulder arthroplasty. *J Am Coll Radiol* 2016;13:1324–1336.
12. Aygün Ü, Duran T, Oktay O, Sahin H, Calik Y. Comparison of magnetic resonance imaging and computed tomography scans of the glenoid version in anterior dislocation of the shoulder. *Orthopedics* 2017;40:e687–e692.
13. Lowe JT, Testa EJ, Li X, Miller S, DeAngelis JP, Jawa A. Magnetic resonance imaging is comparable to computed tomography for determination of glenoid version but does not accurately distinguish between Walch B2 and C classifications. *J Shoulder Elbow Surg* 2017;26:669–673.
14. Leschinger T, Raiss P, Loew M, Zeifang F. Predictors of medium-term clinical outcomes after total shoulder arthroplasty. *Arch Orthop Trauma Surg* 2017;137:187–193.
15. Walker KE, Simcock XC, Jun BJ, Iannotti JP, Ricchetti ET. Progression of glenoid morphology in glenohumeral osteoarthritis. *J Bone Joint Surg Am* 2018;100:49–56.

- 16. Chan K, Knowles NK, Chaoui J, et al.** Characterization of the Walch B3 glenoid in primary osteoarthritis. *J Shoulder Elbow Surg* 2017;26:909–914.
- 17. Bercik MJ, Kruse K II, Yalozis M, Gauci MO, Chaoui J, Walch G.** A modification to the Walch classification of the glenoid in primary glenohumeral osteoarthritis using three-dimensional imaging. *J Shoulder Elbow Surg* 2016;25:1601–1606.
- 18. Iannotti JP, Jun BJ, Patterson TE, Ricchetti ET.** Quantitative measurement of osseous pathology in advanced glenohumeral osteoarthritis. *J Bone Joint Surg Am* 2017;99:1460–1468.
- 19. Lévine C, Boileau P, Favard L, et al.** Scapular notching in reverse shoulder arthroplasty. *J Shoulder Elbow Surg* 2008;17:925–935.
- 20. Lévine C, Garret J, Boileau P, Alami G, Favard L, Walch G.** Scapular notching in reverse shoulder arthroplasty: is it important to avoid it and how? *Clin Orthop Relat Res* 2011;469:2512–2520.
- 21. Laver L, Garrigues GE.** Avoiding superior tilt in reverse shoulder arthroplasty: a review of the literature and technical recommendations. *J Shoulder Elbow Surg* 2014;23:1582–1590.
- 22. Farron A, Terrier A, Büchler P.** Risks of loosening of a prosthetic glenoid implanted in retroversion. *J Shoulder Elbow Surg* 2006;15:521–526.
- 23. Shapiro TA, McGarry MH, Gupta R, Lee YS, Lee TQ.** Biomechanical effects of glenoid retroversion in total shoulder arthroplasty. *J Shoulder Elbow Surg* 2007;16: S90–S95.
- 24. Ting FS, Poon PC.** Perforation tolerance of glenoid implants to abnormal glenoid retroversion, anteversion, and medialization. *J Shoulder Elbow Surg* 2013;22:188–196.
- 25. Nyffeler RW, Jost B, Pfirrmann CW, Gerber C.** Measurement of glenoid version: conventional radiographs versus computed tomography scans. *J Shoulder Elbow Surg* 2003;12:493–496.
- 26. Rouleau DM, Kidder JF, Pons-Villanueva J, Dynamidis S, Defranco M, Walch G.** Glenoid version: how to measure it? Validity of different methods in two-dimensional computed tomography scans. *J Shoulder Elbow Surg* 2010;19:1230–1237.
- 27. Bouacida S, Gauci MO, Coulet B, et al.** Interest in the glenoid hull method for analyzing humeral subluxation in primary glenohumeral osteoarthritis. *J Shoulder Elbow Surg* 2017;26:1128–1136.
- 28. Walch G, Moraga C, Young A, Castellanos-Rosas J.** Results of anatomic nonconstrained prosthesis in primary osteoarthritis with biconcave glenoid. *J Shoulder Elbow Surg* 2012;21:1526–1533.
- 29. Daggett M, Werner B, Gauci MO, Chaoui J, Walch G.** Comparison of glenoid inclination angle using different clinical imaging modalities. *J Shoulder Elbow Surg* 2016;25:180–185.
- 30. Maurer A, Fucentese SF, Pfirrmann CW, et al.** Assessment of glenoid inclination on routine clinical radiographs and computed tomography examinations of the shoulder. *J Shoulder Elbow Surg* 2012;21:1096–1103.
- 31. Iannotti JP, Weiner S, Rodriguez E, et al.** Three-dimensional imaging and templating improve glenoid implant positioning. *J Bone Joint Surg Am* 2015;97:651–658.
- 32. Churchill RS, Brems JJ, Kotschi H.** Glenoid size, inclination, and version: an anatomic study. *J Shoulder Elbow Surg* 2001;10:327–332.
- 33. Daggett M, Werner B, Collin P, Gauci MO, Chaoui J, Walch G.** Correlation between glenoid inclination and critical shoulder angle: a radiographic and computed tomography study. *J Shoulder Elbow Surg* 2015;24:1948–1953.
- 34. Moor BK, Bouaicha S, Rothenfluh DA, Sukthankar A, Gerber C.** Is there an association between the individual anatomy of the scapula and the development of rotator cuff tears or osteoarthritis of the glenohumeral joint? A radiological study of the critical shoulder angle. *Bone Joint J* 2013;95-B:935–941.
- 35. Boileau P, Morin-Salvo N, Gauci MO, et al.** Angled BIO-RSA (bony-increased offset-reverse shoulder arthroplasty): a solution for the management of glenoid bone loss and erosion. *J Shoulder Elbow Surg* 2017;26:2133–2142.
- 36. Boileau P, Avidor C, Krishnan SG, Walch G, Kempf JF, Molé D.** Cemented polyethylene versus uncemented metal-backed glenoid components in total shoulder arthroplasty: a prospective, double-blind, randomized study. *J Shoulder Elbow Surg* 2002;11:351–359.
- 37. Bryce CD, Davison AC, Okita N, Lewis GS, Sharkey NA, Armstrong AD.** A biomechanical study of posterior glenoid bone loss and humeral head translation. *J Shoulder Elbow Surg* 2010;19:994–1002.
- 38. Iannotti JP, Norris TR.** Influence of preoperative factors on outcome of shoulder arthroplasty for glenohumeral osteoarthritis. *J Bone Joint Surg Am* 2003;85:251–258.
- 39. Jaxsens M, Van Tongel A, Henninger HB, Tashjian RZ, De Wilde L.** The three-dimensional glenohumeral subluxation index in primary osteoarthritis of the shoulder. *J Shoulder Elbow Surg* 2017;26:878–887.
- 40. Pearle AD, Kendoff D, Musahl V.** Perspectives on computer-assisted orthopaedic surgery: movement toward quantitative orthopaedic surgery. *J Bone Joint Surg Am* 2009;91:7–12.
- 41. Wylie JD, Tashjian RZ.** Planning software and patient-specific instruments in shoulder arthroplasty. *Curr Rev Musculoskelet Med* 2016;9:1–9.
- 42. Iannotti J, Baker J, Rodriguez E, et al.** Three-dimensional preoperative planning software and a novel information transfer technology improve glenoid component positioning. *J Bone Joint Surg Am* 2014;96:e71.
- 43. Walch G, Vezeridis PS, Boileau P, Deransart P, Chaoui J.** Three-dimensional planning and use of patient-specific guides improve glenoid component position: an in vitro study. *J Shoulder Elbow Surg* 2015;24:302–309.
- 44. Gauci MO, Boileau P, Baba M, Chaoui J, Walch G.** Patient-specific glenoid guides provide accuracy and reproducibility in total shoulder arthroplasty. *Bone Joint J* 2016;98-B:1080–1085.
- 45. Codsí MJ, Bennetts C, Gordiev K, et al.** Normal glenoid vault anatomy and validation of a novel glenoid implant shape. *J Shoulder Elbow Surg* 2008;17:471–478.
- 46. Scalise JJ, Codsí MJ, Bryan J, Iannotti JP.** The three-dimensional glenoid vault model can estimate normal glenoid version in osteoarthritis. *J Shoulder Elbow Surg* 2008;17:487–491.
- 47. Hendel MD, Bryan JA, Barsoum WK, et al.** Comparison of patient-specific instruments with standard surgical instruments in determining glenoid component position: a randomized prospective clinical trial. *J Bone Joint Surg Am* 2012;94:2167–2175.
- 48. Levy JC, Everding NG, Frankle MA, Keppler LJ.** Accuracy of patient-specific guided glenoid baseplate positioning for reverse shoulder arthroplasty. *J Shoulder Elbow Surg* 2014;23:1563–1567.
- 49. Dallalana RJ, McMahon RA, East B, Geraghty L.** Accuracy of patient-specific instrumentation in anatomic and reverse total shoulder arthroplasty. *Int J Shoulder Surg* 2016;10:59–66.
- 50. Walch G, Young AA, Boileau P, Loew M, Gazielly D, Molé D.** Patterns of loosening of polyethylene keeled glenoid components after shoulder arthroplasty for

primary osteoarthritis: results of a multicenter study with more than five years of follow-up. *J Bone Joint Surg Am* 2012;94:145–150.

51. Ho JC, Sabesan VJ, Iannotti JP. Glenoid component retroversion is associated with osteolysis. *J Bone Joint Surg Am* 2013;95:e82.

52. Wong AS, Gallo L, Kuhn JE, Carpenter JE, Hughes RE. The effect of glenoid inclination on superior humeral head migration. *J Shoulder Elbow Surg* 2003;12:360–364.

53. Dilisio MF, May NR, Vincent SA, et al. The association of incomplete glenoid component seating and periprosthetic glenoid radiolucencies after total shoulder arthroplasty. *J Shoulder Elbow Surg* 2016;25:442–447.

54. Levy J, Kurowicki J, Triplet J, Niedzielak T, Disla S. Accuracy of glenoid version and inclination: a comparison of surgicare and blueprint surgical planning software programs. *Bone Joint J* 2017;99:91.

55. Moineau G, Levigne C, Boileau P, Young A, Walch G; French Society for Shoulder & Elbow (SOFEC). Three-dimensional measurement method of arthritic glenoid cavity morphology: feasibility and reproducibility. *Orthop Traumatol Surg Res* 2012;98:S139–S145.

56. Boileau P, Cheval D, Gauci MO, Holzer N, Chaoui J, Walch G. Automated three-dimensional measurement of glenoid version and inclination in arthritic shoulders. *J Bone Joint Surg Am* 2018;100:57–65.

57. Throckmorton TW, Gulotta LV, Bonnarens FO, et al. Patient-specific targeting guides compared with traditional instrumentation for glenoid component placement in shoulder arthroplasty: a multi-surgeon study in 70 arthritic cadaver specimens. *J Shoulder Elbow Surg* 2015;24:965–971.

58. Lau SC, Keith PPA. Patient-specific instrumentation for total shoulder arthroplasty: not as accurate as it would seem. *J Shoulder Elbow Surg* 2018;27:90–95.