



Infection after fracture fixation

Sylvain Steinmetz¹

Diane Wernly¹

Kevin Moerenhout¹

Andrej Trampuz²

Olivier Borens¹

- Infection after fracture fixation is a feared complication in orthopaedic surgery leading to poor bone healing and loss of function.
- Early detection is essential and interdisciplinary care is mandatory.
- Eradication of infection is only possible through combined surgical and antibiotic treatment.
- Intraoperative tissue samples must be taken and are effective for guidance of the antibiotic regimen.
- Infection after fracture fixation is different from prosthetic joint infection (PJI) and needs a specific strategy.
- In this review, we define infection after fracture fixation, and outline the clinical, radiological and laboratory signs of these infections, as well as a treatment algorithm for optimal patient care.

Keywords: antibiotic therapy; biofilm; fracture fixation device; fracture-related infection; internal fixation infection; orthopaedic implant infection

Cite this article: *EFORT Open Rev* 2019;4:468-475.
DOI: 10.1302/2058-5241.4.180093

Introduction

Infection after fracture fixation (IAFF) in orthopaedic surgery is a dreaded complication, leading to non-union, loss of function, and even amputation. It is not only a source of morbidity and mortality,¹ but it also brings an important socio-economic burden.² The success rate in the treatment of IAFF is between 70% and 90%.³ Some studies report an incidence of IAFF for closed fractures of 1% to 2% with an incidence even reaching up to 30% in open fractures.⁴ However, the real incidence of IAFF is probably underestimated due to a lack of precise definition. When looking at the current literature, many studies have concentrated on prosthetic infections. Most of the applied concepts in the

treatment of IAFF are adaptations of algorithms found in prosthetic infections management. It is important to notice that those two identities must be distinguished. While the ultimate goal in the treatment of infected total joint is the eradication of the infection and a sterile implant, the goal of the treatment of an IAFF is the healing of the fracture and the avoiding of chronic osteomyelitis. Furthermore, after consolidation of the bone, the implant can be extricated, contrary to the prosthesis. This allows for a more permissive attitude, with use of suppressive antibiotics until retrieval of the implant. Diagnostics in IAFF can be complicated because identification of the germ is often only possible after intraoperative sampling, in contrast to prosthetic infections where joint aspiration can help preoperatively with diagnostics and establishment of a treatment plan.

Compared to patients presenting for elective surgery, traumatic patients have generally more soft tissue damage, with even direct contamination in case of open fractures. Those delicate cases often need multiple surgeries going from delayed definitive fixation to cutaneous coverage by plastic surgeons. The infection rate between a patient scheduled for elective surgery and the fracture patient is thus not equivalent. On the other hand, mechanic stability is required in order to prevent infection and gain definitive bone healing.^{5,6}

Definition

For a long time, no international definition of IAFF existed. Patient care was inspired by algorithms in prosthetic infection care. But after questioning of those algorithms by some surgeons, it became apparent that neither the guidelines of the CDC (Centers for Disease Control and Prevention), nor the guidelines of the prosthetic infections were optimal in patient care of IAFF. With the support of the *Arbeitsgemeinschaft für Osteosynthesefragen* (AO) Foundation, an international consensus has finally been found in 2018 fixing an organigram helping in decision taking in fracture-related infections (FRI) (Table 1).⁷

Table 1. Definition of infection after fracture-related infection, as proposed by Metsemakers et al.⁷

Confirmatory criteria	
	<p>Fistula, sinus or wound breakdown (probe to bone or implant). Purulent drainage from the wound or presence of pus during surgery. Phenotypically indistinguishable pathogens identified by culture from at least two separate deep tissue/implant (including sonication-fluid) specimens taken during an operative intervention. In case of tissues, multiple specimens should be taken, each with clean instruments (not superficial). In case of joint effusion near the fracture site, sterile puncture may be included as a single sample.³ Presence of pathogens in deep tissue, taken during an operative intervention, as confirmed by histopathological examination using specific staining techniques for bacteria or fungi.</p>
Suggestive criteria	
Clinical signs	<p>Any of:</p> <ul style="list-style-type: none"> - Pain, typically without weight bearing, increasing over time, new onset - Local redness - Local swelling - Increased local temperature - Fever (single oral temperature measurement of 38.3°C) - Persistent, increasing or new-onset wound drainage, beyond the first few days postoperatively, without solid alternative explanation - New onset of joint effusion in fracture patients. Infection after fracture fixation (IAFF) can present as an adjacent septic arthritis in: implant material which penetrates the joint capsule (e.g. femoral nailing), intra-articular fractures
Radiological signs	<p>Any of:</p> <ul style="list-style-type: none"> - Bone lysis (fracture site, around the implant) - Implant loosening - Sequestration - Non-union - Periosteal bone formation, at localizations other than the fracture site
Microbiologic sign	A pathogenic organism identified by culture from a single deep tissue/implant specimen taken during an operative intervention.
Laboratory signs	Elevated serum inflammatory markers: especially suggestive in a case of secondary rise (after an initial decrease), or a consistent elevation over a period of time (erythrocyte sedimentation rate, white blood cell count, C-reactive protein).

Classification

Even with a clear definition in mind, there are still a lot of different classifications available for IAFF. Willenegger and Roth classify IAFF simply according to time, following onset of patient symptoms, into three groups: early (less than 2 weeks), delayed (2–10 weeks), and late onset (more than 10 weeks) infection:⁸

- Early IAFFs present with classic signs of infection (rubor, calor, dolor, tumor and functio laesa), wound healing disturbances and systemic signs of infection such as fever. Within this period, it is considered that the causative bacteria may already have formed a biofilm, although this biofilm may still be in an ‘immature’ phase. Highly virulent organisms, like *Staphylococcus aureus* or gram-negative bacilli, are frequent causative agents of early infection.⁴
- Delayed infections are typically due to less virulent bacteria, such as *Staphylococcus epidermidis* or *Cutibacterium acnes*.⁴ In this situation the biofilm is mature and more resistant to antibiotic therapy. Patients with delayed infections can present with symptoms consistent with either early or late infections.
- Late infections are primarily caused by microorganisms of low virulence like *Staphylococcus epidermidis*.⁴ The compromised fracture healing is a frequent observation in late infections, as is osteomyelitis with sequestrum or involucrum.

Diagnosis

Clinical

Clinical diagnosis can now be made more easily, with the consensus definition in mind. One can use the confirmatory criteria such as fistula, sinus, wound breakdown, purulent drainage. New onset or excessive pain, local redness, local swelling, increased local temperature or fever are suggestive criteria.⁷ Fever is an interesting criterion with a sensitivity of 89%, specificity of 57%, positive predictive values of 28% and negative predictive values of 96%.⁹

Laboratory examination

When doubt subsists on clinical assessment, even though some suggestive criteria are present, laboratory examination is helpful as a new suggestive criterion and also helps us monitor treatment efficiency. This includes leukocytes count and C-Reactive Protein (CRP) dosage. New markers, such as Interleukine-6, combined with the CRP seem to be interesting in detecting low grade infection,⁷ but they are not to be used in primary intention.

Radiology

It is well known that X-rays have a low sensibility and specificity in diagnosing IAFF (soft tissue tumefaction, periosteal reaction), but it remains the first step in the bone assessment and for excluding other causes such as malreduction, malposition of the internal fixation or loss of

reduction. It also gives an indication on the bone healing process, which is a criterion in the patient care.

CT-scan is more precise when there is a suspicion of chronic IAFF in searching for sequestrers, involucrum or clear periosteal reaction. The presence of air is also an important sign at a distance from the surgery, as it can still be present in direct postoperative imagery. As for standard X-rays, the CT-scan brings information of the bone healing process.¹⁰

MRI can detect osseous or soft tissue oedema, but those parameters are also present in the days or weeks after surgery, rendering those signs mainly useful at a distance from the surgery. Due to metallic artefacts of the internal fixation, visualization of nearby structures can be problematic. Nowadays, specific techniques can reduce those artefacts.^{11,12}

Nuclear medicine is also a diagnostic tool with scintigraphy, associated or not with a CT-scan. This remains a good solution for detecting infected sites at distance. The principal advantages are early detection after infection has started and a good sensibility;¹¹ disadvantages are its low specificity and its residual contract uptake until one to two years after initial trauma.

Microbiological

A pathogenic microorganism grown in culture from a single deep tissue sample or implant (including sonication-fluid) taken during an operative intervention is a subjective criterion.⁷ In case of tissue sampling, multiple specimens (> 3) should be taken, each with clean instruments (no superficial tissue or sinus tract swabs).¹³ In cases of joint effusion arising in a joint adjacent to a fractured bone, a fluid sample obtained by sterile puncture is helpful.⁷

Sonication has the advantage of loosening bacteria off the surface of the implant and stimulating them back into a planktonic state making them available for culturing. A part of the internal fixation device, for example, a single screw, can be sent for sonication. The removed screw can be replaced by a new screw. These methods increase the percentage of positive cultures, in particular in patients for whom antibiotic treatment has already been initiated.¹⁴ Culture duration is generally between 5 and 14 days in order to balance the risk for missing a pathogen with difficult or slow growth from a simple contaminant. Another advantage of the culture is that an antibiogram can be completed. In case of doubt or in presence of contradictory results, polymerase chain reaction (PCR) analysis permits an identification of bacteria difficult to cultivate or bacteria in patients where antibiotics were initiated,¹⁵ but without giving an indication of the proliferative state of the bacteria, nor of the antibiogram (Figure 1).¹⁶

Treatment

Important points for treatment

- Eliminate other causes giving a possible similar picture as infection, namely hypersensitivity to fracture fixation devices.¹⁷
- Goals are treating the infection, healing the fracture, preserving soft tissues and obtaining optimal restitution of the function.
- Definitive and immediate treatment of the infection is not always the priority. Bone healing can be the primary objective, as the internal fixation device can be retrieved once consolidation is obtained. Suppressive treatment has thus a place in the treatment.¹⁸
- After suppressive treatment, the material must be retrieved in order to avoid risk of recrudescence of infection or chronic osteomyelitis.¹⁹

Surgical aspect

The first question is: 'did the fracture consolidate'? If the fracture has healed, treatment would be a debridement and complete retrieval of the internal fixation device, followed by two weeks of intravenous antibiotics, and four weeks of oral antibiotics to prevent osteomyelitis. The debridement must be done carefully and include the complete removal of necrotic/infected tissues and dead bone. It must be renewed if necessary and if possible by the same surgical team.

If the fracture has not healed completely, timing of initial infection onset is important. The biofilm appears after a few hours,²⁰ but this does not seem to always prevent the fracture callus from forming in an infectious context.^{21,24} In case of early infection (< 2 weeks), the following questions are:

- Is the implant stable?
- Is the reduction acceptable?
- Is skin closure possible?

If the criterion of acceptable reduction is fulfilled and the implant is stable with a safe cutaneous situation, an acceptable solution can be debridement with retention of the implants followed by 12 weeks of antibiotics, of which the first two weeks should be administered intravenously. If the implant is unstable with a poor reduction and soft tissues closure is not possible, the surgical option of material retrieval, temporary fixation (internal or external) with six weeks of antibiotic treatment (two weeks IV + two weeks per os (p.o.)) is an option, followed by new internal fixation at six weeks together with antibiotics (one week IV + five weeks p.o.) (Figure 2).

In case of late infection, the treatment goal can be eradication or suppression of the infection. It would be preferable

Multidisciplinary diagnostic algorithm for infection after fracture fixation (IAFF)

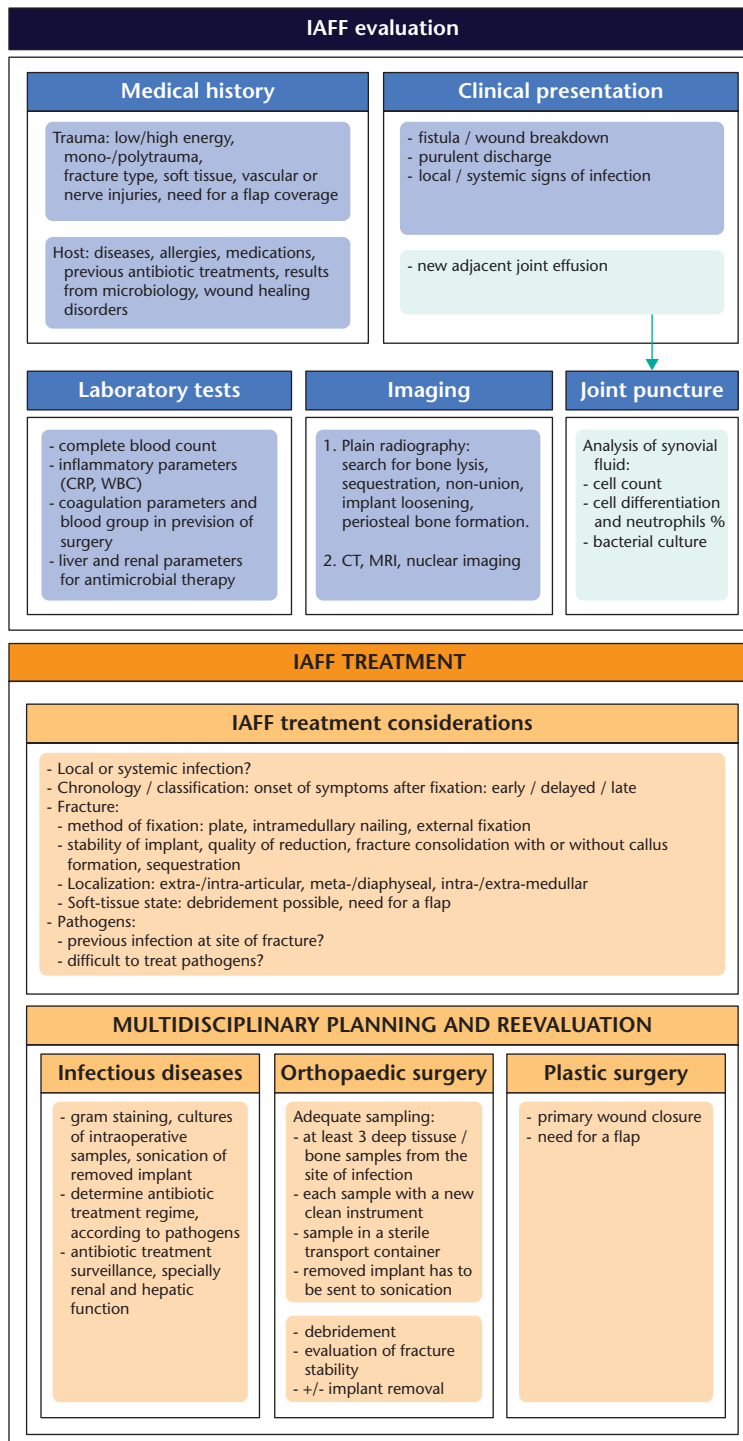


Fig. 1 Multidisciplinary diagnostic algorithm for infection after fracture fixation (IAFF), suggested by Metsemakers et al.7

to choose the option of eradication with difficult-to-treat germs (DTT) and if soft tissue quality is poor. If one of those two criteria is present, it is advised to make an exchange in two stages with debridement, six weeks of

antibiotics (two weeks IV + four weeks p.o.) with external or internal fixation, followed by a re-osteosynthesis and antibiotics (one week IV + five weeks p.o.). If none of these criteria are present, a one-stage exchange with 12 weeks

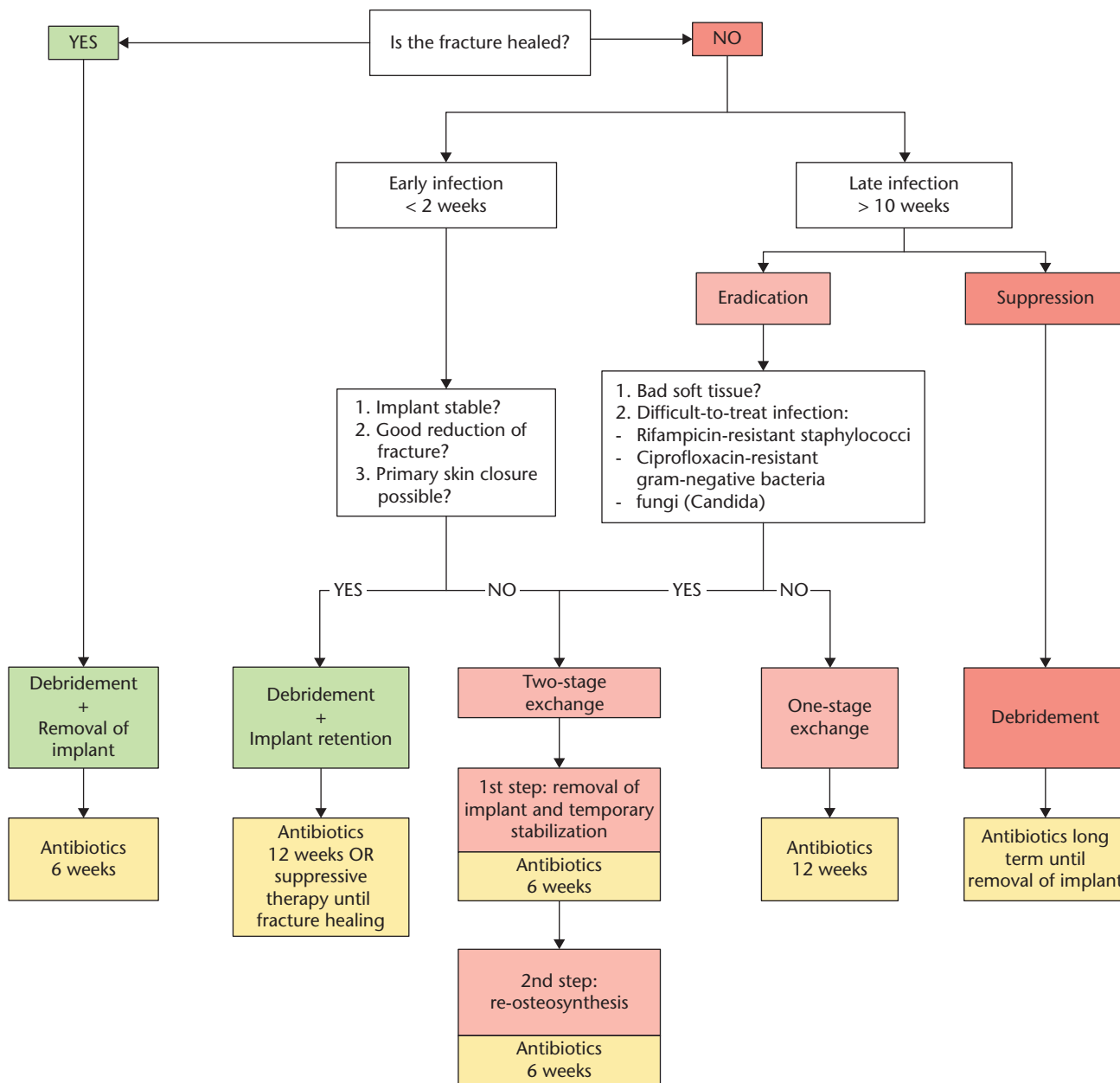


Fig. 2 Treatment algorithm for infection after fracture fixation.

of antibiotics should be the preferred treatment. The choice of suppressive therapy implies debridement, followed by two weeks of antibiotics IV, followed by a long course of oral antibiotics until final retrieval of the internal fixation device (Figure 2).

From a surgical perspective, the treatment of a late infection must be planned thoroughly using imagery searching for sequestrars and dead bone. Intraoperatively, the surgeon must evaluate bony bleeding in order to know its vitality. An important resection can give a significant loss of stability and necessitate more complicated

reconstruction methods such as the Masquelet induced-membrane technique or bone transport.

Antibiotic therapy

The antibiotic therapy must be systematically intravenous in the first instance, then adapted in function of the treatment option (suppressive or curative), the pathogen and the localization (osteitis, osteomyelitis or arthritis). Tables 2 and 3 can serve as red line in antibiotic therapy, but must be discussed with the infectious disease specialist.

Table 2. Antibiotic therapy table for infection after fracture infection suggested antibiotic eradication therapy according to microorganism

Microorganism	Antibiotic therapy	Dose (normal renal function)	Route
Staphylococcus spp.			
Methicillin-susceptible	2 weeks: - Flucloxacillin Followed by (according to susceptibility): Rifampicin +	2 g, every 6 h	IV
	- Levofloxacin or	450 mg, every 12 h	p.o.
	- Cotrimoxazole or	500 mg, every 12 h	p.o.
	- Doxycyclin or	960 mg, every 8 h	p.o.
		100 mg, every 12 h	p.o.
Methicillin-resistant	2 weeks: - Vancomycin or - Daptomycin or - Fosfomycin Followed by an oral rifampicin combination as above	15 mg/kg, every 12 h 6–8 mg/kg, every 24 h 5 g, every 8 h	IV IV IV
Rifampicin-resistant	IV treatment according to susceptibility for 2 weeks (as above), followed by long-term suppression for > 1 year		
Streptococcus spp.			
	2–4 weeks: - Penicillin G or - Ceftriaxone Followed by:	5 Mio IU, every 6 h 2 g, every 24 h 1000 mg, every 8 h	IV IV p.o.
	- Amoxicillin or - Levofloxacin	500 mg, every 12 h	p.o.
Enterococcus spp.			
Penicillin-susceptible	2–3 weeks: - Ampicillin + - Gentamicin +/- - Fosfomycin Followed by: - Amoxicillin	2 g, every 6 h 120 mg, every 24 h 5 g, every 8 h 1000 mg, every 8 h	IV IV IV p.o.
Penicillin-resistant	2–4 weeks: - Vancomycin or - Daptomycin + - Gentamicin or - Fosfomycin Followed by: - Linezolid	2 g, every 6 h 10 mg/kg, every 24 h 120 mg, every 24 h 5 g, every 8 h 600 mg, every 12 h	IV IV IV IV p.o.
Vancomycin resistant (VRE)	Individual. Removal of the implant or suppression until implant removal		
Gram-negative			
Enterobacteriaceae (E. coli, Klebsiella, Enterobacter etc.)	- Ciprofloxacin	750 mg, every 12 h	p.o.
Nonfermenteres (Pseudomonas aeruginosa, Acinetobacter spp.)	2–3 weeks: - Piperacillin/tazobactam or - Meropenem or - Ceftazidim + - Tobramycin or - Gentamicin or - Fosfomycin Followed by: - Ciprofloxacin	4.5 g, every 8 h 1 g, every 8 h 2 g, every 8 h 300 mg, every 24 h 240 mg, every 24 h 5 g, every 8 h 750 mg, every 12 h	IV IV IV IV IV IV p.o.
Ciprofloxacin-resistant	Depending on susceptibility (IV, alone or in combination): - Meropenem 2 g, every 8 h - Colisitin 3 Mio IU every 8 h - Fosfomycin 5 g, every 8 h		
Anaerobes			
Gram-positive (Propionibacterium, Peptostreptococcus, Finegoldia magna)	2 weeks: - Penicillin G or - Ceftriaxone Followed by: - Rifampicin + - (Levofloxacin or - Amoxicillin)	5 Mio IU, every 6 h 2 g, every 14 h 450 mg, every 12 h 500 mg, every 12 h 1000 mg, every 8 h	IV IV p.o. p.o. p.o.
Gram-negative (Bacteroides)	2 weeks: - Ampicillin/sulbactam or - Amoxicillin/clavulanic acid Followed by: - Metronidazol	3 g, every 8 h 2.2 g, every 8 h 500 mg, every 8 h	IV IV p.o.

(Continued)

Table 2. (Continued)

Microorganism	Antibiotic therapy	Dose (normal renal function)	Route
Candida spp.			
Fluconazole-susceptible	2 weeks: - Caspofungin Followed by: - Fluconazole (suppression for > 1 year)	70 mg, every 24 h 400 mg, every 24 h	IV p.o.
Fluconazole-resistant	Individual (e.g. with voriconazole 200 mg, every 12 h, p.o.); removal of the implant or long-term suppression		
Culture-negative	2 weeks: - Ampicillin/sulbactam or - Amoxicillin/clavulanic acid Followed by: - Rifampicin + - levofloxacin	3 g, every 8 h 2.2 g, every 8 h 450 mg, every 12 h 500 mg, every 12 h	IV IV p.o. p.o.

Note. IV, intravenously; p.o., per os.
Source: www.pro-implant-foundation.org.

Table 3. Antibiotic treatment according to pathogen for targeted eradication therapy

Microorganism	Suppressive therapy
Staphylococcus spp.	Cotrimoxazole or doxycycline or clindamycin
Streptococcus spp.	Amoxicillin or clindamycin or levofloxacin
Enterococcus spp.	Amoxicillin (or linezolid)
Anaerobes (gram-positive)	Clindamycin or amoxicillin
Anaerobes (gram-negative)	Metronidazole or clindamycin
Gram-negative organisms	Ciprofloxacin or cotrimoxazole
Fungi (Candida spp.)	Fluconazole

Source: www.pro-implant-foundation.org.

When implants are retained, a curative treatment is generally only efficient if a biofilm-active antibiotic is administered. Until now, only rifampicin has shown to be efficient against staphylococci and quinolones against Gram-negative bacteria.^{20,23} Rifampicin must at all times be associated with a second antibiotic as there is a rapid resistance to it. For the same reason, Rifampicin must never be initiated in the very beginning of the antibiotic treatment, and if possible after removal of the drain and once the wound is dry.²¹

The use of local antibiotic allows for high bactericidal doses in loco. This is even more of interest in the case of bad local blood flow or in patients unable to receive systemic antibiotics at usual dosage for various reasons.^{24,25} In some cases, acute renal failure has been described after use of local antibiotics.^{26,27} Research on post-traumatic osteomyelitis treatment has evolved to local optimal administration of antibiotics via poly methyl methacrylate (PMMA) cement beads impregnated with antibiotics. It is known that not all antibiotics are released from the cement,²² and that Vancomycin and gentamicin have a synergistic effect when mixed together in PMMA cement.²⁸ Absorbable materials, such as calcium sulphate, have the advantage of disposing of a broader range of antibiotics, but have the disadvantage of

contributing to prolonged leakage of the wound.²⁹ Another advantage of local bone fillers, besides the bactericidal effect, is the management of dead space in the presence of cavities or bone defects. At present, local antibiotics have failed to prove their efficacy.³⁰

Conclusion

In conclusion, IAFF is one of the most challenging complications in orthopaedic trauma surgery. It implies severe consequences not only for patients but also for the health care system. Nowadays, a clear definition, classification and treatment of IAFF based for a stepwise approach have been established. Awareness of this potential complication, early recognition of IAFF, intensive debridement and a multidisciplinary approach are keys to a successful treatment.

AUTHOR INFORMATION

¹Service of Orthopaedics and Traumatology, Lausanne University Hospital, Lausanne, Switzerland.

²Charité – Universitätsmedizin Berlin, corporate member of Freie Universität Berlin, Humboldt-Universität zu Berlin, Center for Musculoskeletal Surgery (CMSC), Berlin, Germany.

Correspondence should be sent to: Olivier Borens, CHUV - Department Orthopedics, Rue du Bugnon 46 BH 10, Lausanne VD 1011, Switzerland.
Email: olivier.borens@chuv.ch

FUNDING STATEMENT

No benefits in any form have been received or will be received from a commercial party related directly or indirectly to the subject of this article.

ICMJE CONFLICT OF INTEREST STATEMENT

AT reports grants from Zimmer Biomet paid to his institution outside the submitted work and travel/accommodation/meeting expenses unrelated to activities listed paid to him by Biocomposites.

Downloaded from Bioscientifica.com at 09/12/2024 03:17:59AM via Open Access. This article is distributed under the terms of the Creative Commons Attribution-Non Commercial 4.0 International (CC BY-NC 4.0) licence (<https://creativecommons.org/licenses/by-nc/4.0/>) which permits non-commercial use, reproduction and distribution of the work without further permission provided the original work is attributed. <https://creativecommons.org/licenses/by-nc/4.0/>

OB reports board membership paid to his institution by Orthopaedic Society, EBJS, AO Trauma Switzerland; consultancy paid to his institution by Medacta, Heraeus, Zimmer, Lima; grants/grants pending paid to his institution by Heraeus, Bonesupport, Matthys, AO Trauma Switzerland; payment for lectures including service on speakers bureaus by Medacta, Heraeus, Orthofix, Zimmer, all outside the permitted work. All other authors declare no conflict of interest.

LICENCE

© 2019 The author(s)

This article is distributed under the terms of the Creative Commons Attribution-Non Commercial 4.0 International (CC BY-NC 4.0) licence (<https://creativecommons.org/licenses/by-nc/4.0/>) which permits non-commercial use, reproduction and distribution of the work without further permission provided the original work is attributed.

REFERENCES

- Hak DJ, Fitzpatrick D, Bishop JA, et al. Delayed union and nonunions: epidemiology, clinical issues, and financial aspects. *Injury* 2014;45:53–57.
- Thakore RV, Greenberg SE, Shi H, et al. Surgical site infection in orthopedic trauma: a case-control study evaluating risk factors and cost. *J Clin Orthop Trauma* 2015;6:220–226.
- Tschudin-Sutter S, Frei R, Dangel M, et al. Validation of a treatment algorithm for orthopaedic implant-related infections with device-retention-results from a prospective observational cohort study. *Clin Microbiol Infect* 2016;22:457.e1–457.e9.
- Trampuz A, Zimmerli W. Diagnosis and treatment of infections associated with fracture-fixation devices. *Injury* 2006;37:559–566.
- Metsemakers WJ, Kuehl R, Moriarty TF, et al. Infection after fracture fixation: current surgical and microbiological concepts. *Injury* 2018;49:511–522.
- Worlock P, Slack R, Harvey L, Mawhinney R. The prevention of infection in open fractures: an experimental study of the effect of fracture stability. *Injury* 1994;25:31–38.
- Metsemakers WJ, Morgenstern M, McNally MA, et al. Fracture-related infection: a consensus on definition from an international expert group. *Injury* 2018;49:505–510.
- Willenegger H, Roth B. [Treatment tactics and late results in early infection following osteosynthesis]. *Unfallchirurgie* 1986;12:241–246.
- Steinmetz S, Uçkay I, Cohen C, Abrassart S. Fever and its association with infection in severely injured polytrauma patients. *M J Orth* 2016;1(2):11.
- Ettinger M, Calliess T, Kielstein JT, et al. Circulating biomarkers for discrimination between aseptic joint failure, low-grade infection, and high-grade septic failure. *Clin Infect Dis* 2015;61:332–341.
- Bühne KH, Bohndorf K. Imaging of posttraumatic osteomyelitis. *Semin Musculoskelet Radiol* 2004;8:199–204.
- Pineda C, Espinosa R, Pena A. Radiographic imaging in osteomyelitis: the role of plain radiography, computed tomography, ultrasonography, magnetic resonance imaging, and scintigraphy. *Semin Plast Surg* 2009;23:80–89.
- Atkins BL, Athanasou N, Deeks JJ, et al; The OSIRIS Collaborative Study Group. Prospective evaluation of criteria for microbiological diagnosis of prosthetic-joint infection at revision arthroplasty. *J Clin Microbiol* 1998;36:2932–2939.
- Yano MH, Klautau GB, da Silva CB, et al. Improved diagnosis of infection associated with osteosynthesis by use of sonication of fracture fixation implants. *J Clin Microbiol* 2014;52:4176–4182.
- Omar M, Suero EM, Liidakis E, et al. Diagnostic performance of swab PCR as an alternative to tissue culture methods for diagnosing infections associated with fracture fixation devices. *Injury* 2016;47:1421–1426.
- Tsuru A, Setoguchi T, Kawabata N, et al. Enrichment of bacteria samples by centrifugation improves the diagnosis of orthopaedics-related infections via real-time PCR amplification of the bacterial methicillin-resistance gene. *BMC Res Notes* 2015;8:288.
- Wernly D, Steinmetz S, Cherix S, Borens O. Allergie aux implants orthopédiques: mythe ou réalité? *Rev Med Suisse* 2018;14:2243–2247.
- Bilgili F, Balci HI, Karaytug K, et al. Can normal fracture healing be achieved when the implant is retained on the basis of infection? An experimental animal model. *Clin Orthop Relat Res* 2015;473:3190–3196.
- Rightmire E, Zurakowski D, Vrahas M. Acute infections after fracture repair: management with hardware in place. *Clin Orthop Relat Res* 2008;466:466–472.
- Aboltins CA, Dowsey MM, Buising KL, et al. Gram-negative prosthetic joint infection treated with debridement, prosthesis retention and antibiotic regimens including a fluoroquinolone. *Clin Microbiol Infect* 2011;17:862–867.
- Achermann Y, Eigenmann K, Ledergerber B, et al. Factors associated with rifampin resistance in staphylococcal periprosthetic joint infections (PJI): a matched case-control study. *Infection* 2013;41:431–437.
- van de Belt H, Neut D, Schenk W, van Horn JR, van der Mei HC, Busscher HJ. Gentamicin release from polymethylmethacrylate bone cements and *Staphylococcus aureus* biofilm formation. *Acta Orthop Scand* 2000;71:625–629.
- Zimmerli W, Widmer AF, Blatter M, Frei R, Ochsner PE; Foreign-Body Infection (FBI) Study Group. Role of rifampin for treatment of orthopedic implant-related staphylococcal infections: a randomized controlled trial. *JAMA* 1998;279:1537–1541.
- Walenkamp GH, Vree TB, van Rens TJ. Gentamicin-PMMA beads: pharmacokinetic and nephrotoxicological study. *Clin Orthop Relat Res* 1986;205:171–183.
- Springer BD, Lee GC, Osmon D, Haidukewych GJ, Hanssen AD, Jacobsky DJ. Systemic safety of high-dose antibiotic-loaded cement spacers after resection of an infected total knee arthroplasty. *Clin Orthop Relat Res* 2004;427:47–51.
- van Raaij TM, Visser LE, Vulto AG, Verhaar JA. Acute renal failure after local gentamicin treatment in an infected total knee arthroplasty. *J Arthroplasty* 2002;17:948–950.
- Patrick BN, Rivey MP, Allington DR. Acute renal failure associated with vancomycin- and tobramycin-laden cement in total hip arthroplasty. *Ann Pharmacother* 2006;40:2037–2042.
- Penner MJ, Masri BA, Duncan CP. Elution characteristics of vancomycin and tobramycin combined in acrylic bone-cement. *J Arthroplasty* 1996;11:939–944.
- Ferguson JY, Dudareva M, Riley ND, Stubbs D, Atkins BL, McNally MA. The use of a biodegradable antibiotic-loaded calcium sulphate carrier containing tobramycin for the treatment of chronic osteomyelitis: a series of 195 cases. *Bone Joint J* 2014;96-B:829–836.
- Anagnostakos K, Schröder K. Antibiotic-impregnated bone grafts in orthopaedic and trauma surgery: a systematic review of the literature. *Int J Biomater* 2012;2012:538061.