



# Bilateral total hip arthroplasty in ankylosing spondylitis: a systematic review

David Lin  
Alexander Charalambous  
Sammy A. Hanna

- Ankylosing Spondylitis (AS) can commonly involve the hip joint and cause significant mobility problems. Total hip arthroplasty (THA) on a single side alone will not restore mobility in patients with bilateral disease.
- We performed a systematic review of the available literature to determine the changes in objective outcome measures and complications of bilateral THA in patients with advanced AS. Four studies, a total of 114 THAs, were included in the study. The average patient age was 32.9 years and the average follow-up time was 59.5 months.
- All studies reported a significant improvement in hip function, patient satisfaction and patient mobility following bilateral THA. Harris Hip Score (HHS) improved by a mean of 60.6 points post-operatively.
- Complications included five intra-operative fractures (4.4%) and three transient nerve palsies (2.6%). There were two dislocations (1.8%) that were successfully managed with closed reduction. Seven hips required revision, with the most common cause being aseptic loosening. Twelve hips (10.5%) developed heterotopic ossification consistent with Brooker Class 1 or 2 with no reports of re-ankylosis.
- This review suggests that bilateral THA is a safe and effective treatment of advanced hip disease in AS. Attention must be paid to the highly demanding technical aspects of this procedure to reduce the risk of significant complications.
- Debate still exists on the ideal prosthesis, fixation method and approach to use but this review presents data from several series of uncemented prostheses that have good post-operative results.

**Keywords:** ankylosing spondylitis; bilateral; complications; functional outcome; total hip arthroplasty

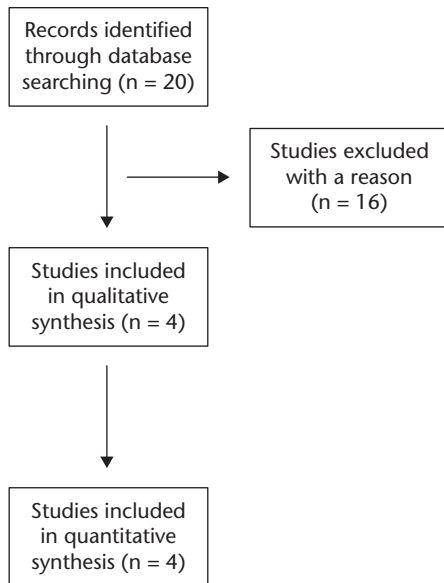
Cite this article: *EFORT Open Rev* 2019;4:476-481.  
DOI: 10.1302/2058-5241.4.180047

## Introduction

Ankylosing spondylitis (AS) is a chronic inflammatory-type arthritis that forms part of the group of spondyloarthritides. It primarily affects the spine and pelvis but peripheral arthritis and enthesitis are also common features.<sup>1</sup> The mean age of onset of symptoms is between 15 and 25 years and it is more common in males.<sup>2</sup> Approximately 0.1% to 1.8% of people are affected. Severe disability and functional impairment can result rapidly due to a combination of axial spine and hip involvement.<sup>1</sup>

Disease-modifying anti-rheumatic drugs (DMARDs) such as anti-tumour necrosis factor (TNF) agents can slow the progression of the disease but they have a limited role in treating advanced established arthritis of the joints.<sup>3</sup> When painful degenerative changes occur in the hip, total hip arthroplasty (THA) has been shown to alleviate pain and improve function in AS patients.<sup>4</sup> Total hip arthroplasty in AS patients is a challenging procedure owing to multiple factors. The approach and exposure of the hip can be difficult due to the presence of an ankylosed joint. There is a risk of implant malposition due to sagittal plane malrotation of the pelvis. Bone quality is affected by disuse osteopenia, resulting in an increased risk of fracture and there is a subsequent risk of re-ankylosis of the joint after arthroplasty.<sup>5,6</sup>

Among patients with hip disease, it has been estimated that between 50% and 90% have bilateral involvement.<sup>7</sup> Arthroplasty on a single side alone will not restore mobility and independence to this group of patients. There is, however, scarce data published regarding the outcome of bilateral THA in this group of patients. We performed a systematic review of the literature to determine the patient-reported functional outcomes and complications of bilateral THA in patients with advanced AS.



**Fig. 1** PRISMA flowchart illustrating the search strategy and number of records screened and included.

## Methods

### Search strategy

MEDLINE and EMBASE databases were searched on 17 August 2018 to identify relevant studies in the available English literature describing clinical and functional results of bilateral THA in patients with ankylosing spondylitis. Keywords used for the search were “bilateral” AND “total hip arthroplasty” OR “total hip replacement” AND “ankylosing spondylitis”. The reference lists of the relevant articles were explored to find additional papers.

### Eligibility criteria

The inclusion criteria consisted of papers describing operative complications, post-operative complications, objective clinician-measured outcomes and validated outcome measures such as a Harris Hip Score (HHS) in patients with AS undergoing bilateral total hip replacement (THR). Studies required a minimum follow-up of 12 months to be eligible, and individual case reports were excluded. Studies that did not comment on the fixation method or operative approach were also deemed not eligible, as this is an important factor to help form conclusions. Papers that did not distinguish functional outcomes or complications between a cohort of unilateral and bilateral THRs were excluded. Papers that described results of arthroplasty of the hip due to other causes of ankylosis such as trauma or other inflammatory diseases were similarly excluded from analysis. The included articles met the PICO criteria for systematic reviews (Population, Intervention, Comparison and Outcomes).

### Data extraction

The first and second authors (DL and AC) reviewed the titles and abstracts of the identified articles. After screening of the titles and abstracts, the full texts of the articles included were obtained and reviewed. Figure 1 represents a PRISMA flowchart illustrating the search strategy and number of records screened and included. Data on the number of patients, age, follow-up period, intra-operative complications, outcome measures and incidence of post-operative heterotopic ossification (HO) were extracted into a spreadsheet.

## Results

### Search results

A total of 20 relevant articles were identified. The abstracts of these articles were reviewed to determine whether they met the inclusion criteria. Initial screening identified eight potential studies. The full text of these eight studies was obtained and reviewed by the first and second authors independently. A subsequent four studies were then excluded. Some studies were large case series that did not differentiate functional outcome scores between their cohorts of bilateral and unilateral replacements.<sup>6,8,9</sup> The other case series included other inflammatory pathologies in the analysis.<sup>10</sup> This left four studies that met the PICO criteria for inclusion in the study.<sup>7,11–13</sup> The results are summarized in Table 1.

### Quality assessment

All studies were small to medium-size retrospective series ( $n = 24–34$ ) that described the clinical and functional outcomes of bilateral THA in patients with advanced AS.

### Cohort characteristics

The studies included a total of 114 THAs with an average patient age of 32.9 years (range 21–57 years). The patients were followed up on average for 59.5 months (range 12–170 months). Most patients had bilateral THAs on the same day with the exception of 17 patients from a single trial who had a staged procedure within 7–10 days after the index arthroplasty. Of the total THAs, five were performed via an anterior approach and the remaining 109 via a posterior approach. All patients received uncemented standard implants.

A significant proportion of the THAs (84/114) were performed on completely ankylosed hips, which represented three out of the four studies.<sup>7,12,13</sup>

### Functional outcome

All studies reported a significant improvement in hip function, patient satisfaction and patient mobility following bilateral THA. The mean post-operative HHS score was

**Table 1.** Summary of study results and demographics

Study	THA Number	Age (years)	Follow-up (months)	Type of implant and fixation	Complications	Heterotopic ossification prophylaxis & incidence post op.	Mean Harris Hip Score pre op.	Mean Harris Hip Score post op.
Bangjian et al, 2012 <sup>7</sup>	24	36.5 (26–50)	50.4 (12–72)	Standard, Zimmer USA Uncemented	Acetabular osteolysis from poly wear (2) Calcar fracture (1)	No prophylaxis 3 hips (Brooker class 1/2)	15.2 (10–42)	86.3 (72–96)
Ye et al, 2014 <sup>11</sup>	30	37.2 (28–52)	29.3 (15–40)	Standard, Undisclosed Uncemented	Femoral nerve palsy (1) Dislocation (1) Superficial infection (1)	Indomethacin None	24.8 (15–42)	83.8
Wang et al, 2014 <sup>12</sup>	26	33.7 (22–57)	128.4 (73–170)	Standard, Link Germany Uncemented	Peroneal nerve palsy (1) Calcar fracture (2) Acetabular osteolysis from poly wear (3) Aseptic loosening of cup (2) Aseptic loosening of stem (2)	Indomethacin 4 hips (Brooker Class 1/2)	22.1 (10–38)	91.7 (75–98)
Feng et al, 2016 <sup>13</sup>	34	24.2 (21–43)	30.0 (24–72)	Standard, Link Germany/ Zimmer USA Uncemented	Acetabular osteolysis from poly wear (3) Calcar fracture (2) Sciatic nerve palsy (1) Anterior dislocation (1)	Celecoxib 5 hips (Brooker Class 1/2)	23.7 (21–43)	65.8 (61–73)

Note. THA, total hip arthroplasty.

81.9 (range 65.8–91.7). Harris Hip Scores improved by a mean of 60.6 points (range 42.1–71.1 points) points post-operatively.

Half of the included studies measured range of movement both before and after the procedure. Feng et al reported an improvement in hip flexion from 0° to 134°. <sup>13</sup> Bangjian et al reported range of flexion increasing from 0° to 84°. <sup>7</sup>

Three out of four studies reported mobility measures pre and post-operatively. <sup>7,11,13</sup> Out of a total of 42 patients who required support for ambulation and transfers pre-operatively, 40 were able to mobilize independently unaided or with the aid of just one stick post-operatively.

### Complications

Complications included dislocation, intra-operative fracture, post-operative osteolysis and neuropraxia. There were two unilateral dislocations from separate studies and both were successfully managed with closed reductions. <sup>11,13</sup>

The five reported fractures were sustained during femoral stem insertion and were isolated to the femur. These were universally managed with cabling and restricted weight bearing post-operatively. In all cases, a standard, non-modular, stem was used.

Eight of the hips demonstrated evidence of osteolysis secondary to polyethylene wear. This mainly involved the acetabular component with two affecting the concurrent stem component. One acetabular cup required revision surgery and two required polyethylene liner exchange and bone grafting of the lesions.

Three transient nerve palsies were reported. The nerves involved were the sciatic (1), femoral (1) and peroneal nerves (1). Nerve recovery took between two weeks and six months.

### Revision rate

Only Wang et al reported any revisions in their series. A total of seven THAs (four patients) required revision surgery. <sup>12</sup> Three cups showed signs of osteolysis secondary to polyethylene wear. Of these three cups, two (one patient) required bone grafting and liner exchange at 137 and 116 months, with the third requiring revision at 103 months. Two patients had bilateral aseptic loosening of both components that required revision surgery (135, 141, 149 and 155 months). The authors do not comment on the underlying cause of aseptic loosening. The ten-year survival was, however, reported at 92.3% in this series.

### Heterotopic ossification formation and re-ankylosis

Ninety THAs received prophylaxis in the form of either Indomethacin or Celecoxib for a two-week duration and the remaining 24 THAs received no prophylaxis. In this review 12 THAs (10.5%) were noted to develop HO consistent with Brooker Class 1 or 2. No Brooker Class 3 or 4 HO was reported and there were no patients with a reported re-ankylosis. No re-operations for HO were reported.

## Discussion

Bilateral THA appears to be a successful procedure in AS patients with advanced hip disease. <sup>7,12,13</sup> There are marked improvements in functional outcomes in the form of HHS scores and range of motion in all the papers reviewed. The return to independent mobilization was also clearly reported in three of the four papers.

When compared to other studies that grouped bilateral and unilateral hip arthroplasty together, the improvement

in HSS is more marked in this series of bilateral THAs. For our combined bilateral THA cohort, the average improvement in HSS was 60.6 points (range 42.1–71.1 points). Bhan et al and Saglam et al reported improvements of 33.1 and 34.1 in their respective case series.<sup>6,9</sup> A possible reason for the improvement seen in our included studies is that the patient cohort started at a much lower functional baseline and had more advanced disease. The average pre-operative HHS was 21.35 in the four included studies and 48.05 in the two series.

Interestingly while pain is usually the main symptom leading to arthroplasty surgery, in this subgroup of young patients with advanced AS, it is usually the functional limitation that prompts surgical intervention. Post-operative pain is a recognized complication of THA but this was not significantly problematic for patients in this review.<sup>6</sup>

The other complications encountered in this review are again all recognized complications of THA. We found that our cohort of bilateral THA patients had a slightly higher incidence of nerve injury at 2.6% when compared to Bhan et al's study, which also looked at THA for bony ankylosis.<sup>6</sup> No specific comment on particular intra-operative difficulties was made to explain this. Interestingly the occurrence of the femoral nerve palsy did not occur in the study where an anterior approach to the hip was used.

There was also a slightly higher incidence of intra-operative fracture of 4.3% in our review compared to other series.<sup>6,7,8</sup> This is likely to be secondary to the universal implantation of uncemented stems into potentially abnormal bone. Joshi et al did not report any fractures in their series of cemented THAs.<sup>8</sup>

The two cases (1.75%) of dislocation recorded in this review were managed successfully with closed reduction. This rate is slightly lower in comparison to large reviews by Bahn et al and Joshi et al who reported rates of 4.3% (4/92) and 2.20% (4/181) respectively. Bahn et al employed a posterior approach and Joshi et al a direct lateral approach with trochanteric osteotomy.<sup>6,8</sup>

In this review 12 hips (10.5%) were noted to develop HO consistent with Brooker Class 1 or 2, and this rate is comparable to other studies that reported an incidence of 11.6% (21/181 hips) and 13% (12/92 hips).<sup>6,8</sup>

Revision is a key indicator of the success of arthroplasty. Of the papers in this review, only Wang et al reported complications that required revision of implants.<sup>12</sup> We suggest this is because the follow-up period was significantly longer than in the other three studies. Saglam et al reported an aseptic loosening rate of 7.6% at a mean follow-up of 5.4 years and postulated that associated spine stiffness and increased forces around the hip joint might be responsible.<sup>9</sup> It remains to be seen whether bilateral THA in this group of patients has a comparable revision rate and more long-term follow-up needs to be published for this question to be answered. However, the ten-year

survival rate of 92.3% presented by Wang et al is very good.<sup>12</sup>

The strength of our study is based on the comprehensive review of the available literature. The studies all used uncemented prosthesis and the vast majority (109/114) of operations were performed through a posterior approach. All studies also included a HHS. These factors allowed for direct comparison and pooling of the data to help formulate conclusions. We accept that the studies included do display some heterogeneity in terms of specific type of prosthesis used and follow-up time. We are confident, however, that the follow-up was long enough to pick up any early and medium-term complications of relevance. The variability in follow-up would influence the revision rate of the series included and we should make this clear.

Total hip arthroplasty in AS patients, in particular those with end-stage ankylosis, remains an extremely technically challenging procedure. Given the similarities in several of the case series encountered in this review paper, we present a structured approach to minimizing complications in these challenging patients.

#### *Pre-operative considerations*

Ankylosing spondylitis patients with advanced hip disease invariably have a degree of multisystemic involvement and their pre-operative optimization is crucial. Anaesthetic involvement should begin early as these patients can present specific challenges in the form of difficult airways, cardiovascular and respiratory issues.<sup>14</sup> DMARDs such as anti-TNF alpha agents should be stopped in conjunction with rheumatology advice as they have been shown to increase the risk of wound breakdown.<sup>3</sup> Our review revealed only one case of superficial wound infection post-operatively. Although the overall rate is low (0.9%), wound problems can threaten the underlying prosthesis and we suggest all is done to minimize the risks involved. Surgical planning in the form of a pre-operative CT scan with 3D reconstructions provides valuable information on the degree of pelvic malrotation that can cause errors in cup positioning. Some surgeons even advocate addressing the spinal component of the disease in the form lumbar pedicle subtraction osteotomy prior to arthroplasty to address this.<sup>15</sup>

#### *Intra-operative considerations*

The approach to the hip in advanced AS is challenging, especially in the ankylosed joint. Consider an approach that will protect the abductor function, which is invariably already weakened due to chronic disuse. There is usually a pre-existing degree of flexion, adduction and rotation deformity of the hip. This can make femoral exposure challenging. There is a subsequent risk of damage to the greater trochanter and posterior acetabular wall during

resection of the neck. Bangjian et al suggested a two-step technique of cutting the femoral neck to minimize this risk, although this was not taken up by other surgeons.<sup>7</sup> There has been a move away from trochanteric osteotomy, which, although improves exposure, has been shown to increase the incidence of HO formation.<sup>8,16</sup>

Identification of the original joint plane is also recognized as a problem in advanced disease and the use of intra-operative radiographs can be helpful for orientation. Feng et al described looking for the incomplete grey ossifying cartilage and foveal soft tissue as a landmark in advanced cases.<sup>13</sup> Ankylosing spondylitis patients have a degree of malrotation of the pelvis in the sagittal plane, which is exaggerated during the gait cycle.<sup>17</sup> Cervical and lumbar fusion is compensated for by hyperextension at the hip. This subsequently increases the anteversion of the cup. Cup positioning is especially challenging in these advanced cases of AS and we caution against excessive anteversion. Rivière et al have recently described the concept of a kinematically aligned THA where cup position is determined not by traditional Lewinnek safe zones but by 'functional orientation' of the cup.<sup>18</sup>

Another problem commonly encountered was the poor quality of acetabular bone. This was likely due to a degree of disuse osteopenia, and surgeons need to be especially aware that over-reaming in these cases can compromise the medial wall. Some authors describe leaving a spike of bone at the superior lateral acetabulum margin to provide purchase for a cementless cup.<sup>6</sup>

There is also debate as to the most ideal type of fixation in AS patients. On the basis of this review, uncemented implants are suitable for AS patients. These implants preserve bone stock leading to less difficulty in future revisions, which young AS patients undergoing THA are unfortunately predisposed to.<sup>9</sup> While all patients in this review received uncemented THAs, there are relatively large case series that have been published on the clinical effectiveness and safety of cemented stems in AS.<sup>8</sup> Joshi et al did not report any intra-operative fractures, compared to the 4.39% rate seen in our review. Other surgeons make an argument for using cemented stems based on femoral morphology and tended to use cement in the majority of Dorr Type C femurs.<sup>9</sup>

### Post-operative considerations

Heterotopic ossification formation and subsequent re-ankylosis of the hip remains a major concern in arthroplasty in AS patients.<sup>12,16</sup> Studies have estimated the incidence of HO formation as between 40% and 76%.<sup>5</sup>

Post-operative prophylaxis should be considered in this patient group, with a two-week course of Indomethacin being a cost-effective method against HO formation.<sup>12</sup> Initial fears over its effect on bony integration of the stem and cup components have been allayed by recent

work.<sup>19,20</sup> Studies have also proven the efficacy of a single dose of radiotherapy to prevent HO after THA surgery.<sup>21</sup>

## Conclusion

This review suggests that bilateral total hip arthroplasty is a safe and effective treatment of advanced hip disease in AS. It results in significant improvements in objective outcome measures such as HHS and patient mobility. We note that astute detail must be paid to the highly demanding technical aspects of this procedure. Debate still exists on the ideal prosthesis, fixation method and approach to use. This review presents data from several series of uncemented prostheses that have good post-operative results, but we do note the slightly increased risk of intra-operative fracture compared to series where a cemented implant is used. We suggest specific patient factors should be considered when performing this surgery on AS patients and informed decisions made during the pre-operative planning stage.

### AUTHOR INFORMATION

Trauma and Orthopaedic Surgery Department, Royal London Hospital, UK.

Correspondence should be sent to: Alexander Charalambous, Trauma and Orthopaedic Surgery Department, Royal London Hospital, Whitechapel Rd, Whitechapel, London E1 1BB, UK.  
Email: a.chara@doctors.org.uk

### ICMJE CONFLICT OF INTEREST STATEMENT

The authors declare no conflict of interest relevant to this work.

### FUNDING STATEMENT

No benefits in any form have been received or will be received from a commercial party related directly or indirectly to the subject of this article.

### LICENCE

© 2019 The author(s)

This article is distributed under the terms of the Creative Commons Attribution-Non Commercial 4.0 International (CC BY-NC 4.0) licence (<https://creativecommons.org/licenses/by-nc/4.0/>) which permits non-commercial use, reproduction and distribution of the work without further permission provided the original work is attributed.

### REFERENCES

1. He C, He X, Tong W, et al. The effect of total hip replacement on employment in patients with ankylosing spondylitis. *Clin Rheumatol* 2016;35:2975–2981.
2. Feldtkeller E, Khan MA, van der Heijde D, van der Linden S, Braun J. Age at disease onset and diagnosis delay in HLA-B27 negative vs. positive patients with ankylosing spondylitis. *Rheumatol Int* 2003;23:61–66.
3. Hou LQ, Jiang GX, Chen YF, et al. The comparative safety of TNF inhibitors in ankylosing spondylitis: a meta-analysis update of 14 randomized controlled trials. *Clin Rev Allergy Immunol* 2018;54:234–243.

Downloaded from Bioscientifica.com at 03/28/2025 12:30:07PM via Open Access. This article is distributed under the terms of the Creative Commons Attribution-Non Commercial 4.0 International (CC BY-NC 4.0) licence (<https://creativecommons.org/licenses/by-nc/4.0/>) which permits non-commercial use, reproduction and distribution of the work without further permission provided the original work is attributed. <https://creativecommons.org/licenses/by-nc/4.0/>

4. **Shanahan WR Jr, Kaprove RE, Major PA, Hunter T, Baragar FD.** Assessment of longterm benefit of total hip replacement in patients with ankylosing spondylitis. *J Rheumatol* 1982;9:101–104.
5. **Brinker MR, Rosenberg AG, Kull L, Cox DD.** Primary noncemented total hip arthroplasty in patients with ankylosing spondylitis: clinical and radiographic results at an average follow-up period of 6 years. *J Arthroplasty* 1996;11:802–812.
6. **Bhan S, Eachempati KK, Malhotra R.** Primary cementless total hip arthroplasty for bony ankylosis in patients with ankylosing spondylitis. *J Arthroplasty* 2008;23:859–866.
7. **Bangjian H, Peijian T, Ju L.** Bilateral synchronous total hip arthroplasty for ankylosed hips. *Int Orthop* 2012;36:697–701.
8. **Joshi AB, Markovic L, Hardinge K, Murphy JCM.** Total hip arthroplasty in ankylosing spondylitis: an analysis of 181 hips. *J Arthroplasty* 2002;17:427–433.
9. **Saglam Y, Ozturk I, Cakmak MF, Ozdemir M, Yazicioglu O.** Total hip arthroplasty in patients with ankylosing spondylitis: midterm radiologic and functional results. *Acta Orthop Traumatol Turc* 2016;50:443–447.
10. **Kim YL, Shin SI, Nam KW, Yoo JJ, Kim Y-M, Kim HJ.** Total hip arthroplasty for bilaterally ankylosed hips. *J Arthroplasty* 2007;22:1037–1041.
11. **Ye C, Liu R, Sun C, et al.** Cementless bilateral synchronous total hip arthroplasty in ankylosing spondylitis with hip ankylosis. *Int Orthop* 2014;38:2473–2476.
12. **Wang W, Huang G, Huang T, Wu R.** Bilaterally primary cementless total hip arthroplasty in patients with ankylosing spondylitis. *BMC Musculoskelet Disord* 2014;15:344.
13. **Feng D-X, Zhang K, Zhang Y-M, et al.** Bilaterally primary cementless total hip arthroplasty for severe hip ankylosis with ankylosing spondylitis. *Orthop Surg* 2016;8:352–359.
14. **Talikota AT, Dinesh K, Kumar A, Goolappa.** Ankylosing spondylitis: a challenge to anaesthesiologists due to difficulties in airway management and systemic involvement of disease. *Indian J Anaesth* 2010;54:70–71.
15. **Hu J, Qian BP, Qiu Y, et al.** Can acetabular orientation be restored by lumbar pedicle subtraction osteotomy in ankylosing spondylitis patients with thoracolumbar kyphosis? *Eur Spine J* 2017;26:1826–1832.
16. **Sweeney S, Gupta R, Taylor G, Calin A.** Total hip arthroplasty in ankylosing spondylitis: outcome in 340 patients. *J Rheumatol* 2001;28:1862–1866.
17. **Tang WM, Chiu KY.** Primary total hip arthroplasty in patients with ankylosing spondylitis. *J Arthroplasty* 2000;15:52–58.
18. **Rivière C, Lazennec J-Y, Van Der Straeten C, Auvinet E, Cobb J, Muirhead-Allwood S.** The influence of spine-hip relations on total hip replacement: a systematic review. *Orthop Traumatol Surg Res* 2017;103:559–568.
19. **Trnka HJ, Zenz P, Zembsch A, Easley M, Ritschl P, Salzer M.** Stable bony integration with and without short-term indomethacin prophylaxis: a 5-year follow-up. *Arch Orthop Trauma Surg* 1999;119:456–460.
20. **Wurnig C, Schwameis E, Bitzan P, Kainberger F.** Six-year results of a cementless stem with prophylaxis against heterotopic bone. *Clin Orthop Relat Res* 1999;361:150–158.
21. **Healy WL, Lo TC, DeSimone AA, Rask B, Pfeifer BA.** Single-dose irradiation for the prevention of heterotopic ossification after total hip arthroplasty: a comparison of doses of five hundred and fifty and seven hundred centigray. *J Bone Joint Surg Am* 1995;77:590–595.