



# Plaster, splint, brace, tape or functional mobilization after first-time patellar dislocation: what's the evidence?

Daan Vermeulen  
Mara Rosa van der Valk  
Laurens Kaas

- With an incidence of 5.8 per 100,000 per year, patellar dislocations are commonly seen in the emergency department. Surprisingly, there are only a few studies available that focus on the results of the different non-surgical treatment options after first-time patellar dislocation. The aim of this review is to provide an overview of the most recent and relevant studies on the rationales and results of the non-surgical treatment for first-time patellar dislocation.
- Patellar instability mainly affects young and active patients, with a peak incidence of 29 per 100,000 per year in adolescents. The medial patellofemoral ligament, a main passive restraint for lateral translation of the patella, is torn in lateral patellofemoral dislocations. Treatment of first-time patellar dislocation can be either conservative or surgical.
- There are two options in conservative management of first-time patellar dislocation: immobilization using a cylinder cast or removable splint, or, second, functional mobilization after applying a brace or patellar tape.
- The current available literature of conservative treatment after a first-time patellar dislocation is little and of low quality of evidence. Conclusions should be drawn with care, new research focussing on non-surgical treatment is therefore strongly needed.

**Keywords:** patella; patellar dislocation; patellar instability

Cite this article: *EFORT Open Rev* 2019;4:110-114.  
DOI: 10.1302/2058-5241.4.180016

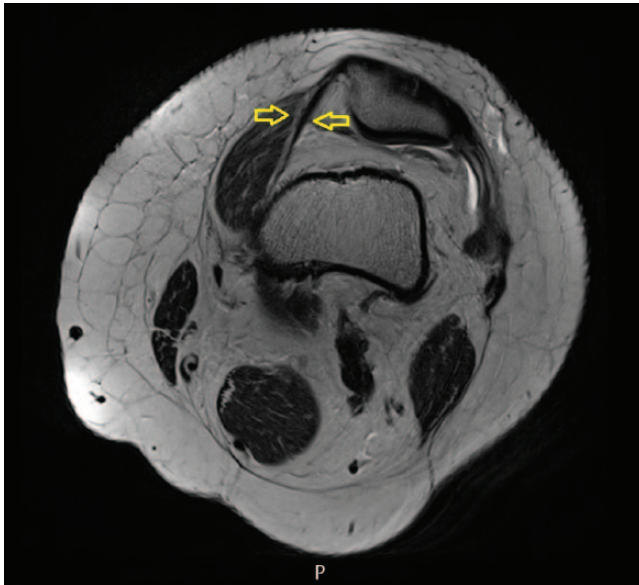
## Introduction

With an incidence of 5.8 per 100,000 per year, patellar dislocations are commonly seen in the emergency department.<sup>1</sup>

Over the past two decades, several studies and reviews have been published on the subject of whether these first-time dislocations should be treated surgically or non-surgically.<sup>2</sup> Surprisingly, there are only a few studies available that focus on the results of non-surgical treatment after first-time patellar dislocation.<sup>3</sup> Comparison of the results of our surgical endeavours for the treatment of first-time patellar dislocation with a non-surgical treatment is difficult beforehand, as there is no evidence available on the optimal non-surgical treatment to address this pathology. The aim of this review is to provide an overview of the most recent and relevant studies on the rationales and results of the non-surgical treatment for first-time patellar dislocation. In 2012, van Gemert et al concluded in their systematic review that only one relevant study comparing conservative treatment with a cylinder cast, brace and posterior splint was available.<sup>3</sup>

## Anatomy and pathophysiology

The patellofemoral joint consists of the patella and the femoral trochlea. This joint obtains its stability by osseous structures, ligaments and muscles. The grooved form of the trochlea prevents the patella from dislocation, as well as the medial patellofemoral ligament (MPFL, see Fig. 1) and the vastus medialis oblique.<sup>4</sup> These structures each provide stability in another part of the range of motion from extension to flexion. In full extension, the patella is located proximally to the trochlea and stability is dependent on ligaments and muscles, mostly the MPFL. In this position, the patella is most vulnerable to dislocation.<sup>5</sup> In the first 10–30 degrees of flexion, the patella enters the trochlea and is stabilized by the grooved shape.<sup>(4,5)</sup> In a patella alta, this trajectory outside of the trochlea is even longer, therefore this causes a higher risk of dislocation.



**Fig. 1** Medial patellofemoral ligament (MPFL) in transverse MRI image.

In trochlear dysplasia, mainly the proximal flattening of this groove can cause patellar subluxations and luxations. In further flexion, the tibia rotates internally which results in a more favourable Q-angle and the quadriceps cause a force directing posteriorly, giving more stability to the patella femoral joint.<sup>5</sup>

Patellar dislocation mainly affects young and active patients, with a peak incidence of 29 per 100,000 per year in adolescents.<sup>1</sup> Lateral patellar dislocation is usually a result of slight flexion combined with valgus stress (93%) without a direct blow on the patella. The other 7% is caused by a direct force being applied to the medial side of the patella.<sup>6</sup> This usually happens during sports or other physical activity.<sup>6</sup> Many risk factors are known, such as patella alta, trochlear dysplasia, excessive lateral patellar tilt an excessive tibial tuberosity–trochlear groove (TT–TG) distance, lateral tibial rotation due to increased femoral anteversion and general hyperlaxity.<sup>4</sup> The medial patellofemoral ligament (MPFL), a main passive restraint for lateral translation of the patella, is torn in lateral patellofemoral dislocations.<sup>7</sup> The incidence of concomitant injury to the patellar cartilage is high, at 95% of all dislocations.<sup>8</sup> After reduction, which is usually spontaneous, standard radiographs should be acquired. MRI of the knee is advised in case of substantial effusion of the knee to evaluate presence of an osteochondral fragment or loose body and to evaluate the extent of injury to the medial soft tissues.<sup>7,9</sup> Recurrence rates after first-time patellar dislocation are reported to be between 17% and 44%.<sup>1,10</sup>

Treatment of first-time patellar dislocation can be either conservative or surgical. Surgical interventions include proximal soft tissue patellar realignment procedures (such

as an MPFL reconstruction), procedures to solve trochlear dysplasia and realignment procedures distal to the patella and femoral osteotomies to correct malrotation. The choice of surgical intervention will be influenced by individual anatomical abnormalities such as trochlear dysplasia, a patella alta and an increased TT–TG distance, and concomitant injuries, such as avulsion or osteochondral fracture.<sup>4</sup> Non-surgical treatment options include bracing, taping and immobilization, combined with physiotherapy. A recent Cochrane review by Smith et al. concluded that there is some evidence to support surgical over non-surgical treatment for the short term, but the quality of evidence is very low.<sup>2</sup> The choice of type of conservative treatment after first-time patellar dislocation is the subject of debate. In 2012, van Gemert et al concluded in their systematic review that only one relevant study comparing conservative treatment with a cylinder cast, brace and posterior splint was available.<sup>3</sup> In a study by Maënpää, the redislocation rate was significantly higher in the brace group (0.29 per follow-up year), compared to the cylinder cast and posterior splint groups (respectively 0.12 and 0.08 per follow-up year,  $p < 0.05$ ). However, level of evidence was low due to a small study population, difference in duration of immobilization between groups and use of old brace types.<sup>10</sup>

## Search strategy

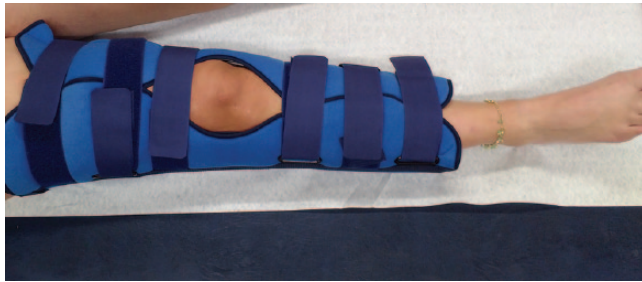A systematic search in the PubMed and Cochrane databases was performed. Search terms included synonyms for patella, dislocation, conservative treatment and the different conservative treatment modalities. Cross-references of the included articles were screened for additional publications. The following selection criteria were followed: study design – retrospective, prospective, randomized controlled trial or systematic review – comparison of different conservative treatment modalities, primary patellar dislocation, and in either English or Dutch. After removal of duplicates, the search yielded in 503 articles. No additional articles were identified by screening the cross-references. The titles and abstracts of these articles were screened, after which 25 articles remained. This selection was screened in full text, which resulted in seven articles remaining for inclusion, which are discussed below.

## Non-surgical treatment options

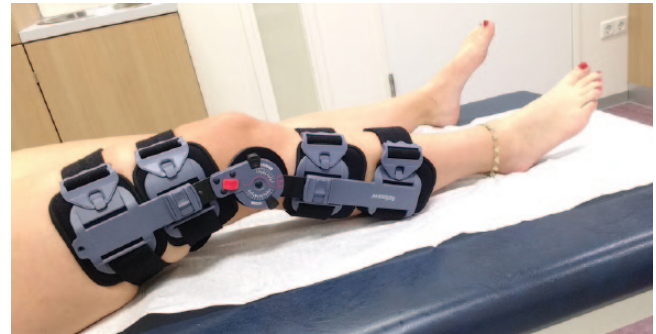The different modalities of conservative treatment for first-time patellar dislocation can roughly be classified into two groups. One is immobilization using a cylinder cast or removable splint, the other is functional mobilization after treatment using a brace, patellar tape or no external device at all. Braces or patellar tapes can also be

**Table 1.** Overview of the relevant literature: redislocation rates and functional outcomes between the different conservative treatment options

| Author                          | Year | No of patients | Redislocation |        |       |      | Kujala score |        |       |      | Lysholm knee score |      |
|---------------------------------|------|----------------|---------------|--------|-------|------|--------------|--------|-------|------|--------------------|------|
|                                 |      |                | Cast          | Splint | Brace | Tape | Cast         | Splint | Brace | Tape | Cast               | Tape |
| Mäenpää and Lehto <sup>10</sup> | 1997 | 100            | 38%           | 47%    | 57%   | —    | 80           | 82     | 74    | —    | —                  |      |
| Rood et al <sup>16</sup>        | 2012 | 18             | 0%            | —      | —     | 0%   | —            | —      | —     | 100  | 76                 |      |



**Fig. 2** Removable posterior splint.



**Fig. 3** Flexion-limited brace.

applied in the rehabilitation phase after a period of immobilization. In this section, the rationales and results of the options for conservative treatment are discussed in more detail.

*Immobilization with plaster*

An ankle to inguinal cylinder plaster-of-Paris cast for six weeks has historically been the treatment of choice for first patellar dislocation. However, the duration differs greatly.<sup>11,12</sup> The hypothesis is that immobilization permits fibrosis and repair of the ruptured or stretched medial retinaculum and soft tissues, because there is no excessive stress placed upon the damaged tissue and the joint.<sup>12,13</sup> A major down-side is the muscle atrophy that is associated with such a long period of immobilization, in particular atrophy of the vastus medialis oblique, which is an important stabilizer of the patellofemoral joint.<sup>4,14</sup> Therefore, physiotherapy is frequently required to strengthen the quadriceps muscles after immobilization.<sup>2,15</sup> Beside that, long immobilization also leads to weakness of the insertion of ligaments, as well as limitation movement of the joint by the formation of adhesions in and around the joint.<sup>10,12,16</sup> Furthermore, it is well known that lengthened immobilization has a detrimental effect on cartilage quality and thickness. In a study with paraplegics, it was discovered that the cartilage thickness decreases significantly in patients who stood or walked for less than 1 hour a day compared to controls.<sup>17</sup> In another recent study with mice it was shown that macroscopic visible thinning of the cartilage was already present after one week of immobilization.<sup>18</sup> Therefore it is proposed that early mobilization prevents adverse events and can reduce pain and stiffness after treatment.<sup>10,12</sup>

*Immobilization with a removable posterior splint*

Removable splints are patient friendly, as they can be removed for hygiene (see Fig. 2). These are said to have a slightly better result in terms of post-treatment loss of flexion.<sup>10</sup> However, patient compliance can be lower compared to for a fixed cylinder plaster because of the removable character of the splint. In comparative post-treatment apprehension tests, both the cylinder plaster and the splint show the same percentage of positive apprehension tests (53%) and in terms of redislocation of the patella after treatment, the splint does not differ significantly from the cylinder plaster.<sup>10</sup> Looking at the Kujala score, there is no significant difference reported between a plaster cast and a posterior splint. Brace immobilization shows a non-significantly lower Kujala score (see Table 1).<sup>10</sup>

When comparing the different articles describing immobilization, it stands out that the length of immobilization varies greatly, as the literature does not give clear guidance about how long the immobilization period should be. For instance, Mäenpää and Lehto let the physician decide the duration of treatment, with an average of 4 weeks (SD 1) in plaster cast and 3 weeks (SD 2) in a posterior splint, while Rood et al immobilized patients for six weeks.<sup>10,16</sup> This impedes a proper comparison between the published studies.

*Brace*

After a period of usually two weeks of immobilization to reduce pain and swelling, a knee brace can also be applied. The knee brace is a flexion-limited brace (see Fig. 3), sometimes with the possibility of applying a

medially directed force to the lateral side of the patella, thus preventing the patella from luxation and aiding in its normal alignment and tracking. The advantage of the knee brace is that it enables the patient to use the joint while stabilizing and preventing the patella from dislocation, especially in the first 30 degrees of flexion when the patella is not contained by the trochlea.<sup>19</sup> In the study of Becher et al, it is shown that there was a significant decrease in patellar tilt angle and patellar height ratio (in terms of the Caton-Deschamps Index, Insall-Salvati Index and the Patellochlear Index) with a brace, using an MRI and scanning the knee with and without a brace in extension, in 15 degrees and in 30 degrees of flexion. The patellar tilt angle was prominently reduced in 15 and 30 degrees of flexion.<sup>19</sup> Kaewkongnok et al compared the dislocation rate between two, four or six weeks of brace fixation (fixed in 20–30° of flexion) in 601 patients after a first-time patellar dislocation. They did not find significant differences in recurrence between the different groups.<sup>20</sup>

Furthermore, patients report that they prefer early mobilization over lengthened immobilization.<sup>12</sup> Because of the early and 'accelerated' approach it is said that pain and stiffness are reduced while optimizing muscle strength.<sup>12</sup> With this, the proprioception of the joint is also improved.<sup>20</sup> A reported downside to the brace is that it leads to slightly more redislocation of the patella after the treatment period has ended (0.29 per follow-up year) compared to immobilization treatment (0.12 per follow-up year) (see Table 1).<sup>10</sup>

### Tape

Patellar taping was introduced by McConnell and was postulated to improve patellofemoral tracking.<sup>21</sup> Some MRI studies showed that patellar taping reduces patellofemoral malalignment,<sup>22,23</sup> although this effect is disputed by other studies.<sup>24,25</sup> Taping of the patella is usually performed in the rehabilitation phase after an initial other non-surgical treatment after patellar dislocation. Although not frequently used, taping for six weeks is described as a primary treatment after patellar dislocation. It allows early functional rehabilitation, it is easy to apply and it is cheap. As a minor downside, taping can cause irritation of the skin.<sup>16</sup> In a small trial by Rood et al, 18 patients were randomized between tape bandage and cylinder cast. Taping resulted in a significantly better Lysholm score at 6 and 12 weeks follow-up ( $p = 0.001$ ). The difference remained until five years of follow-up ( $p = 0.008$ ). There were no cases of redislocation, although, due to the small population, it is difficult to draw conclusions.<sup>16</sup>

### Functional after-treatment

Immediate functional treatment after patellar dislocation prevents the side effects of an immobilization period. Also,

increased strength of healed ligaments have been described in mobilization of injured extremities, and cell division and collagen synthesis is reported to occur more quickly in mobilized extremities compared to immobilized extremities.<sup>26</sup> However, the healing potential of the MPFL has never been thoroughly investigated. As an extra-articular ligament, such as the medial collateral ligament of the knee, a ruptured MPFL can result in some healing and potential lengthening of the ligament.<sup>27</sup>

In a cohort study by Garth et al, 59 athletic patients with 69 patellar dislocations were included, with an average follow-up of 47 months. Treatment consisted of a functional rehabilitation programme. Good to excellent results were achieved in 66% of the patients; redislocation occurred in 26%. Anatomic predisposition and onset of bilateral instability at a young age were associated with a less favourable outcome in this study.<sup>26</sup>

## Conclusion

The current available literature of conservative treatment after a first-time patellar dislocation is little and of low quality of evidence. Conclusions should be drawn with care, new research focussing on non-surgical treatment is therefore strongly needed.

### AUTHOR INFORMATION

<sup>1</sup>Department of Orthopaedic Surgery, St. Antonius Hospital, Nieuwegein, Utrecht, The Netherlands.

Correspondence should be sent to: L.Kaas, Department of Orthopaedic Surgery, St. Antonius Hospital, P.O. Box 2500, 3430 EM Nieuwegein, The Netherlands.  
Email: orthopedie-research@antoniusziekenhuis.nl

### FUNDING STATEMENT

No benefits in any form have been received or will be received from a commercial party related directly or indirectly to the subject of this article.

### ICMJE CONFLICT OF INTEREST STATEMENT

None declared.

### LICENCE

© 2019 The author(s)

This article is distributed under the terms of the Creative Commons Attribution-Non Commercial 4.0 International (CC BY-NC 4.0) licence (<https://creativecommons.org/licenses/by-nc/4.0/>) which permits non-commercial use, reproduction and distribution of the work without further permission provided the original work is attributed.

### REFERENCES

1. Fithian DC, Paxton EW, Stone ML, et al. Epidemiology and natural history of acute patellar dislocation. *Am J Sports Med* 2004;32:1114–1121.
2. Smith TO, Donell S, Song F, Hing CB. Surgical versus non-surgical interventions for treating patellar dislocation. *Cochrane Database Syst Rev* 2015;CD008106.

3. **van Gemert JP, de Vree LM, Hessels RA, Gaakeer MI.** Patellar dislocation: cylinder cast, splint or brace? An evidence-based review of the literature. *Int J Emerg Med* 2012;5:45-1380-5-45.
4. **Duthon VB.** Acute traumatic patellar dislocation. *Orthop Traumatol Surg Res* 2015;101(suppl):S59-S67.
5. **Zaffagnini S, Grassi A, Zocco G, Rosa MA, Signorelli C, Muccioli GMM.** The patellofemoral joint: from dysplasia to dislocation. *EFORT Open Rev* 2017;2:204-214.
6. **Sillanpaa P, Mattila VM, Iivonen T, Visuri T, Pihlajamaki H.** Incidence and risk factors of acute traumatic primary patellar dislocation. *Med Sci Sports Exerc* 2008;40:606-611.
7. **Lattermann C, Arendt EA, Andrich J, Jones M.** Extensor mechanism Injuries. In: Boyer MI. *AAOS Comprehensive Orthopaedic Review*. Second ed. Rosemont: American Academy of Orthopaedic Surgeons, 2014:1367-1378.
8. **Nomura E, Inoue M, Kurimura M.** Chondral and osteochondral injuries associated with acute patellar dislocation. *Arthroscopy* 2003;19:717-721.
9. **Duerr RA, Chauhan A, Frank DA, DeMeo PJ, Akhavan S.** An algorithm for diagnosing and treating primary and recurrent patellar instability. *JBJS Rev* 2016;4:01874474-201609000-00003.
10. **Mäenpää H, Lehto MU.** Patellar dislocation: the long-term results of nonoperative management in 100 patients. *Am J Sports Med* 1997;25(2):213-217.
11. **Smith TO, Davies L, Donell ST.** Immobilization regime following lateral patellar dislocation: a systematic review and meta-analysis of the current evidence base. *Eur J Trauma Emerg Surg* 2010;36:353-360.
12. **Armstrong BM, Hall M, Crawford E, Smith TO.** A feasibility study for a pragmatic randomised controlled trial comparing cast immobilisation versus no immobilisation for patients following first-time patellar dislocation. *Knee* 2012;19:696-702.
13. **Kiviluoto O, Santavirta S, Pasila M.** Recurrences after conservative treatment of acute dislocation of the patella. *Ital J Sports Traumatol* 1986;8:159-162.
14. **Tesch PA, von Walden F, Gustafsson T, Linnehan RM, Trappe TA.** Skeletal muscle proteolysis in response to short-term unloading in humans. *J Appl Physiol* (1985) 2008 Sep;105:902-906.
15. **Clark BC, Manini TM, Hoffman RL, Russ DW.** Restoration of voluntary muscle strength after 3 weeks of cast immobilization is suppressed in women compared with men. *Arch Phys Med Rehabil* 2009;90:178-180.
16. **Rood A, Boons H, Ploegmakers J, van der Stappen W, Koëter S.** Tape versus cast for non-operative treatment of primary patellar dislocation: a randomized controlled trial. *Arch Orthop Trauma Surg* 2012;132:1199-1203.
17. **Vanwaseele B, Lucchinetti E, Stüssi E.** The effects of immobilization on the characteristics of articular cartilage: current concepts and future directions. *Osteoarthritis Cartilage* 2002;10:408-419.
18. **Nagai M, Aoyama T, Ito A, et al.** Alteration of cartilage surface collagen fibers differs locally after immobilization of knee joints in rats. *J Anat* 2015;226:447-457.
19. **Becher C, Schumacher T, Fleischer B, Ettinger M, Smith T, Ostermeier S.** The effects of a dynamic patellar realignment brace on disease determinants for patellofemoral instability in the upright weight-bearing condition. *J Orthop Surg Res* 2015;10:126.
20. **Kaewkongnok B, Bøvling A, Milandt N, Møllenberg C, Viberg B, Blønd L.** Does different duration of non-operative immobilization have an effect on the redislocation rate of primary patellar dislocation? A retrospective multicenter cohort study. *Knee* 2018;25:51-58.
21. **McConnell J.** The management of chondromalacia patellae: a long term solution. *Aust J Physiother* 1986;32:215-223.
22. **Crossley KM, Marino GP, Macilquham MD, Schache AG, Hinman RS.** Can patellar tape reduce the patellar malalignment and pain associated with patellofemoral osteoarthritis? *Arthritis Rheum* 2009;61:1719-1725.
23. **Worrell T, Ingersoll CD, Bockrath-Pugliese K, Minis P.** Effect of patellar taping and bracing on patellar position as determined by MRI in patients with patellofemoral pain. *J Athl Train* 1998;33:16-20.
24. **Bockrath K, Wooden C, Worrell T, Ingersoll CD, Farr J.** Effects of patella taping on patella position and perceived pain. *Med Sci Sports Exerc* 1993;25:989-992.
25. **Gigante A, Pasquinelli FM, Paladini P, Ulisse S, Greco F.** The effects of patellar taping on patellofemoral incongruence: a computed tomography study. *Am J Sports Med* 2001;29:88-92.
26. **Garth WP Jr, Pomphrey M Jr, Merrill K.** Functional treatment of patellar dislocation in an athletic population. *Am J Sports Med* 1996;24:785-791.
27. **Arendt EA, Fithian DC, Cohen E.** Current concepts of lateral patella dislocation. *Clin Sports Med* 2002;21:499-519.