



SLAP lesions: current controversies

Filippo Familiari¹

Gazi Huri²

Roberto Simonetta³

Edward G. McFarland⁴

- Knowledge of the pertinent anatomy, pathogenesis, clinical presentation and treatment of the spectrum of injuries involving the superior glenoid labrum and biceps origin is required in treating the patient with a superior labrum anterior and posterior (SLAP) tear.
- Despite the plethora of literature regarding SLAP lesions, their clinical diagnosis remains challenging for a number of reasons.
 - First, the diagnostic value of many of the available physical examination tests is inconsistent and ambiguous.
 - Second, SLAP lesions most commonly occur concomitantly with other shoulder injuries.
 - Third, SLAP lesions have no specific associated pain pattern.
- Outcomes following surgical treatment of SLAP tears vary depending on the method of treatment, associated pathology and patient characteristics.
- Biceps tenodesis has been receiving increasing attention as a possible treatment for SLAP tears.

Keywords: SLAP; tenodesis; repair; controversies; aetiology; examination; treatment

Cite this article: *EFORT Open Rev* 2019;4:25-32.

DOI: 10.1302/2058-5241.4.180033

Introduction

Lesions of the superior labrum anterior and posterior (SLAP) to the biceps tendon were first recognized as a pathologic entity by Andrews et al¹ and later further characterized and classified by Snyder et al² into four types on the basis of the amount of damage to the labrum and the amount of destabilization of the biceps anchor (Fig. 1). Maffet et al³ expanded the classification to types V to VII (Fig. 2). In 2011, Modarresi et al⁴ listed ten different types of SLAP lesions.

The incidence and aetiology of SLAP lesions remain uncertain. Snyder et al⁵ evaluated 2375 shoulder

arthroscopies, and 140 (6%) of them revealed a SLAP lesion. Maffet et al³ reported that 84 (12%) of 712 patients examined arthroscopically had a SLAP lesion, and Handberg et al⁶ reported that 32 (6%) of 530 patients had such a lesion. One review of the clinical presentation of SLAP tears highlighted the variable clinical features of these lesions.⁷ Of 544 shoulder arthroscopy procedures performed, 139 (26%) revealed a SLAP lesion. One hundred and three (74%) of the SLAP lesions were type I, 29 (21%) were type II, one (0.7%) was type III and six (4%) were type IV. Of these tears, 88% were found to have co-existent shoulder pathology. Type-II lesions in patients who were aged ≤ 40 years were associated with a Bankart lesion, whereas those in patients aged > 40 years were associated with a supraspinatus tear and osteoarthritis of the humeral head. Type-III and type-IV lesions were associated with a high-demand occupation and a Bankart lesion.

This review highlights the current state of the literature on key debates in the pertinent anatomy, pathogenesis, clinical presentation and treatment of the spectrum of injuries involving the superior glenoid labrum and biceps origin that is required in treating the patient with a SLAP tear. The emerging role of biceps tenodesis for primary treatment of SLAP tears and also for failed SLAP repairs will be reviewed.

Anatomy

The vascular supply of the glenoid labrum arises from the suprascapular artery, the circumflex scapular branch of the subscapular artery and the posterior humeral circumflex artery (8). Vascularity is decreased in the anterior, anterosuperior and superior parts of the labrum, thus making them more vulnerable to injuries and having impaired healing potential.

The labrum in the superior half of the glenoid is typically triangular but may be meniscoid with no transition from labrum to cartilage. In addition, the labrum above the glenoid equator is more mobile, often but not always with loose attachments to the glenoid rim.⁸ Typically,

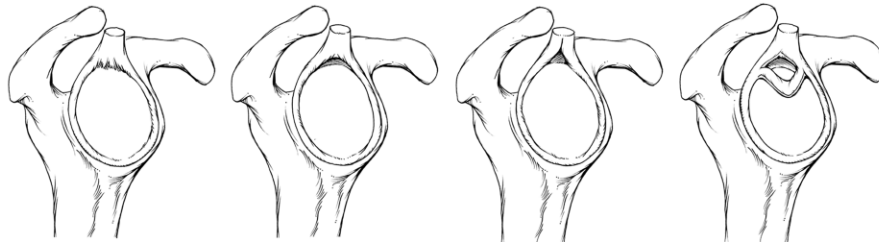


Fig. 1 a) Type-I SLAP tear: superior labral fraying with localized degeneration. b) Type-II SLAP tear: detachment of the superior labrum/biceps anchor from the glenoid. c) Type-III SLAP tear: bucket-handle type tear of the superior labrum with an intact biceps anchor. d) Type-IV SLAP tear: bucket-handle tear of the superior labrum with extension of the labral tear into the biceps tendon. © JHU 2018/AAM

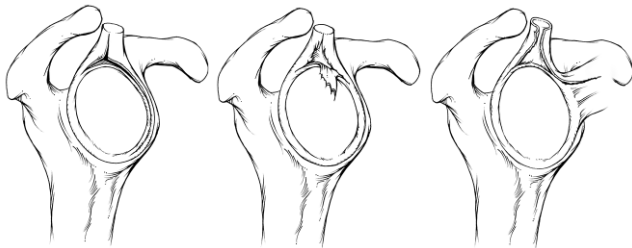


Fig. 2 a) Type-V SLAP tear: SLAP tear combined with a Bankart lesion. b) Type-VI SLAP tear: SLAP tear combined with an unstable flap tear of the labrum. c) Type-VII SLAP tear: SLAP tear with continuation to the middle glenohumeral ligament origin. © JHU 2018/AAM

about 50% of the biceps tendon fibres attach to the superior glenoid tubercle while the remaining 50% attach to varying degrees to the labrum anterior and posterior to the superior glenoid tubercle.⁹ Moreover, it has been shown that the long head of the biceps does not send fibres anteriorly beyond the anterior edge of the supraglenoid tubercle.¹⁰ It may have an entirely posterior, a posterior-dominant, or an equally anterior and posterior attachment into the superior labrum. In most shoulders, the biceps has either an entirely posterior or a posterior-dominant labral insertion; however, 17% to 37% of shoulders have an equal distribution of fibres inserting into the anterior and posterior aspects of the labrum.^{9,11}

The variable relationship between the anterosuperior labrum and the glenohumeral ligaments has important implications for the evaluation and treatment of SLAP lesions. These normal variants include a sublabral foramen or absence of the anterosuperior labrum, both of which are often noted in conjunction with a cord-like middle glenohumeral ligament (MGHL). One study found three variations of the anterosuperior labral anatomy in 73 of 546 patients (13.4%) undergoing shoulder arthroscopy. These included a sublabral foramen (3.3%), a sublabral foramen with a cord-like MGHL (8.6%) and an absent anterosuperior labrum with a cord-like MGHL (i.e. Buford complex, 1.5%).¹² Errant repair of either of these variants of the anterosuperior labrum or attachment of the

MGHL to the glenoid may result in significant loss of external rotation.

Aetiology

There are several controversies about the pathophysiology of SLAP tears. While SLAP tears are known to be caused by both macro-trauma and micro-trauma, the exact forces which create these lesions remain unknown and therefore also controversial. Several injury mechanisms have been proposed for the pathogenesis of SLAP tears. Commonly recognized mechanisms include: traction injury to the arm; direct compression loads, such as an axial load of a fall on an outstretched arm; and, lastly, repetitive overhead activities, such as throwing a ball or overhead motions. A cadaver study has shown that SLAP tears are more commonly created when the shoulder is forward flexed compared with when it is in an extended position.¹³ Moreover, direct traction injury to the biceps tendon has also been suggested as an aetiology of SLAP lesions. A cadaver study by Bey et al found that traction on the biceps tendon is capable of producing type-II SLAP lesions, and that inferior subluxation significantly facilitates the generation of type-II SLAP lesions.¹⁴ The stability of the biceps anchor and the pattern of injury to the superior labrum/biceps complex are dependent on shoulder position during the phases of overhead throwing. Kuhn et al, in a cadaver study, evaluated the effect of two arm positions, late cocking and early deceleration, on the propensity to the force required to produce SLAP tears. They found that the superior labral complex lesions demonstrated 20% less strength in the late cocking phase than in the early deceleration phase.¹⁵ Another study by Shepard et al examined the ultimate strength of the biceps anchor and the generation of a SLAP lesion when the biceps tendon is loaded in line with its fibres (i.e. shoulder deceleration) as opposed to when it is loaded posteriorly in a peel-back fashion (i.e. late cocking phase of throwing).¹⁶ The authors found that the biceps anchor was significantly weaker when loaded with a posterior vector as seen in the late cocking phase, as compared with biceps loading in

Table 1. Specificity and sensitivity of different tests in patients with type-II SLAP lesions

Test	Specificity (%)	Sensitivity (%)
Yergason's test	92.7	13
Pain provocative test	89.9	17.4
Anterior slide test	83.5	13
Crank test	82.6	8.7
Speed's test	67.9	47.8
Relocation test	51.4	43.5
Neer test	51.4	47.8
Active compression test	48.6	65.2
Hawkins test	30.3	65.2
Dynamic labral shear test	78	51

line with its fibres made to simulate an eccentric biceps load. A posterior-directed force resulted in the generation of a lesion resembling a type-II SLAP lesion. Another study evaluated the force applied to the anterior and posterior portions of the superior labrum by measuring the strain in conditions closely simulating the throwing motion.¹⁷ Only during the late cocking phase, when the arm was in maximal external rotation, was the increase in strain statistically significant throughout the superior labrum and the strain on the posterior portion significantly greater than that on the anterior portion of the labrum. In contrast, a finite element analysis of the superior half of the glenoid labrum of the stages of throwing during simulated biceps loading showed that the maximum principal stress was greatest in the deceleration phase of the throwing motion.¹⁸ The authors theorized that deceleration might be the most likely phase of throwing to cause a SLAP lesion, especially for those athletes with a long head of the biceps tendon originating anteriorly. These studies suggest that the anatomic orientation of the biceps tendon during loading may be one of the most important factors in the pathogenesis of SLAP tears.

Other theories of the aetiology of SLAP tears exist in overhead athletes. One of these is that 'internal impingement' occurs with the arm in abduction and external rotation. The theory is that posterior capsular contracture is associated with increased external rotation in the late cocking phase of throwing. This leads to contact of the greater tuberosity to the posterior and superior labrum which, over time, results in SLAP tears. This cascade of events results in a torsional 'peel-back' of the posterosuperior labrum, which eventually leads to labrum failure as seen in SLAP lesions. They suggested that these are three variants of type-II SLAP lesions based upon the aetiology.

Controversies about examination

Despite the plethora of literature regarding SLAP lesions, their clinical diagnosis remains challenging for a number of reasons.¹⁹ First, although many physical examination tests are available to assist in diagnosing SLAP lesions,²⁰⁻²⁵

the diagnostic value of many of these tests is inconsistent and ambiguous.^{23,26-31} Several provocative tests for SLAP tears have been described: O'Brien (i.e. active compression test);²⁴ anterior slide;²² biceps load (I and II);^{32,33} pain provocation;³⁴ crank;³⁵ Jobe relocation;²¹ forced shoulder abduction and elbow flexion;³⁶ and resisted supination-external rotation.³⁷ However, none of these tests has been found to be highly accurate for diagnosis of SLAP tears (Table 1). Recently, Sodha et al¹⁹ evaluated the clinical utility of the dynamic labral shear test (DLST) for diagnosing SLAP lesions in a prospective, consecutive case series including 774 patients (610 with no SLAP lesion but with other shoulder abnormalities, nine with isolated SLAP lesion (ISL) and 155 with a SLAP lesion and another shoulder abnormality (CSL)) who underwent diagnostic arthroscopy and a pre-operative DLST. The DLST was positive for 40% of patients in the control group, 78% in the ISL group and 57% in the CSL group. In the ISL group, the DLST had a sensitivity of 78%, specificity of 51%, positive predictive value (PPV) of 2%, negative predictive value (NPV) of 100%, odds ratio (OR) of 3.58 and diagnostic accuracy (DA) of 51%. In comparison, the ORs were 1.09 for the active compression test, 1.30 for the lift-off test and 1.53 for the relocation test, which were not significantly different from each other. For diagnosing a SLAP lesion existing in a joint with other associated injury, the DLST had a sensitivity of 57%, specificity of 52%, PPV of 23%, NPV of 83%, OR of 1.4 and DA of 53%. Interestingly, combining all four tests did not improve the OR for detecting ISLs or CSLs. The authors concluded that with an OR of 3.58, the DLST was sensitive but not specific for detecting ISLs.

The second reason SLAP lesions are difficult to examine accurately is that most SLAP lesions occur concomitantly with other shoulder injuries (e.g. glenohumeral instability, rotator cuff tears, biceps tendon ruptures). As demonstrated with the DLST above, the OR and clinical utility decrease when there are co-existing pathologies. Another reason SLAP lesions are difficult to diagnose is that they typically have no specific associated pain pattern; this may be compounded in patients who may be unable to describe accurately the location of their pain or provide a precise history.³⁸ Pain may be sharp or aching and may be located deep within the shoulder. The pain may localize or radiate to the anterior or posterior aspects of the shoulder, mimicking symptoms from biceps pathology, anterior and posterior labral tears, or acromioclavicular joint disease. Typically, the symptoms are worse with heavy lifting, pushing and overhead motions, but these, too, are non-specific findings. Therefore, clinicians must rely on a combination of history, physical examination and magnetic resonance imaging findings to make a preoperative diagnosis. Because of this uncertainty, diagnostic arthroscopy is necessary to positively identify a SLAP lesion.

Controversies about treatment

The initial treatment for a patient with what might be considered to be a SLAP lesion is non-operative treatment. Pain relief and clinical outcome improvement can be expected after non-operative treatment of superior labral tears, especially in young, active patients.³⁹ Patients with history of trauma, mechanical symptoms and demand for overhead activities are less likely to benefit.⁴⁰ Since the history, examination and even imaging may be inexact and not diagnostic, and because SLAP lesions are not proven to cause degeneration of the shoulder to any degree, the main reason for operative treatment is the failure of non-operative treatment. Other factors, especially the age of the patient, the type of sports activity, the level of participation by the individual (recreational, amateur, professional) and the degree of the symptoms are major considerations when discussing operative treatment.

The enthusiasm for repair of SLAP tears has increased with the development of arthroscopic systems designed for repair of these lesions. Onyekwelu et al⁴¹ reviewed and analysed the data of the Statewide Planning and Research Cooperative Systems (SPARCS) database from the New York State Department of Health to compare the incidence of arthroscopic SLAP lesion repairs relative to other outpatient surgical procedures. From 2002 to 2010, the number of arthroscopic SLAP repairs increased by 464%, from 765 to 4313. This represented a population-based incidence of 4.0/100 000 in 2002 and 22.3/100 000 in 2010. The mean age of patients undergoing arthroscopic SLAP repair was 37 ± 4 years in 2002 and 40 ± 14 years in 2010. These data suggest a substantial increase in the number of arthroscopic SLAP repairs compared with the rising rate of outpatient orthopaedic surgical procedures and a significant increase in the age of patients who are being treated with arthroscopic SLAP repairs. Similarly, Vogel et al⁴² analysed three different databases (part A, the SPARCS database; part B, the California Office of Statewide Health Planning and Development ambulatory surgery database; and part C, the American Board of Orthopaedic Surgery (ABOS) database) over a period of ten years to determine the SLAP repair incidence compared with all orthopaedic procedures. In part A, from 2002 to 2009, there was a 238% increase in SLAP repair volume compared with a 125% increase in all orthopaedic procedures. In part B, from 2005 to 2009, there was a 20.2% increase in SLAP repair volume compared with a decrease of 13.6% in all orthopaedic procedures. In part C, among candidates performing at least one SLAP repair, there was no statistically significant difference in likelihood of performing a SLAP repair in 2010 compared with 2003. This suggests that SLAP lesions may have been over-treated with surgical repair; it also suggests that part II ABOS candidates had become more aware of the need to narrow indications for

this procedure. A query of the ABOS certification examination database was performed from 2002 to 2011 to determine the rates of SLAP repair, biceps tenodesis and biceps tenotomy for patients with isolated SLAP tears.⁴³ Practice trends for orthopaedic board candidates indicated that the proportion of SLAP repairs decreased over time with an expected increase in biceps tenodesis and tenotomy, especially in older patients.

This increase in the number of diagnosed SLAP tears that are treated with arthroscopic repair is interesting because the ideal treatment for SLAP tears has not been elucidated; several studies have shown increasing risk of complications and poor outcomes with the inability to return to sport, particularly in older patients or overhead-throwing athletes. Erickson et al⁴⁴ evaluated the records of four sports or shoulder/elbow fellowship trained orthopaedic surgeons to determine the trends in SLAP repairs over time, including patient age, and percentage of SLAP repairs *versus* other common shoulder arthroscopic procedures between 2004 and 2014. There were 9765 patients who underwent arthroscopic shoulder procedures between 2004 and 2014. Of these, 619 underwent a SLAP repair (6.3%); the average age was 31.2 ± 11.9 . The age of patients undergoing SLAP repair significantly decreased over time. Most SLAP repairs were performed on type-II SLAP tears. The percentage of SLAP repairs compared with the total number of shoulder arthroscopic surgeries and total number of patients who underwent SLAP repair significantly decreased over time. Conversely, the number and percentage of biceps tenodeses increased over time.

A systematic review of papers reporting surgical treatment of a SLAP lesion was performed to define the arthroscopic indications for surgery; surgical aspects, including type, location, and number of anchors and sutures; criteria used to determine completeness of the repair; and postoperative rehabilitation details.⁴⁵ Of the 26 included papers (12 focusing on isolated SLAP repair and 14 focusing on combined SLAP repair with other lesions), 54% did not report indications for surgery. Reporting of the type of anchor and suture material was inconsistent. For example, only 35% of the studies reported some variation of 12:00 placement, but 31% did not report the position of placement. Similarly, 89% of the studies did not report the criteria for determining completeness of the repair; 85% reported general post-operative rehabilitation guidelines, but only 4% reported in-depth details. This systematic review demonstrated a wide variability in the reported surgical variables, which hampered comparison between papers and their outcomes. Moreover, these findings may be some of the factors responsible for the variability in treatment outcomes reported by the studies and suggest that efforts could be directed towards consistency in documenting and reporting surgical indications, surgical

techniques, surgical endpoints and efficacious rehabilitation programs.

Brockmeyer et al⁴⁶ proposed a treatment algorithm for SLAP lesions based upon the type of lesion, age of patient, concomitant lesions and functional requirements, as well as sport activity level of the patient, and distinction between normal variations and degenerative changes in the SLAP complex and 'true' SLAP lesions. The authors proposed the following treatment algorithm:

- type I: non-operative treatment or arthroscopic debridement;
- type II: SLAP repair or biceps tenotomy/tenodesis;
- type III: resection of the instable bucket-handle tear;
- type IV: SLAP repair (biceps tenotomy/tenodesis if > 50% of biceps tendon is affected);
- type V: Bankart repair and SLAP repair;
- type VI: resection of the flap and SLAP repair; and
- type VII: refixation of the anterosuperior labrum and SLAP repair.

Results after repair of type-II lesions depend on the method of fixation and patient demands. Even though the use of biodegradable tacks has not been popular since the 1990s, surgical success rates were reported from 71% to 88%.⁴⁷⁻⁴⁹ However, one study reported persistent night pain in > 40% of such patients and return to play in only 48% of athletes treated with these devices.⁴⁷ Another study of bioabsorbable tacks placed using a trans-rotator cuff approach showed an average L'Insalata score of 87 and average American Shoulder and Elbow Surgeons score of 87.2; however, only 44% of patients were able to return to full athletic activity.²⁴

More consistent clinical results have been achieved with the use of suture anchors. Domb et al⁵⁰ compared three commonly used suture anchor configurations for repair of type-II SLAP lesions. Type-II SLAP lesions were created and repaired via three suture anchor configurations: a single simple suture anterior to the biceps; two simple sutures, one anterior and one posterior to the biceps; and a single mattress suture through the biceps anchor. When type-II SLAP lesions were subjected to cyclic traction, the load to strain failure was greater with a single anchor and mattress suture than with one or two anchors with simple sutures around the labrum. McCulloch et al⁵¹ examined whether there was a difference in external rotation between type-II SLAP repairs consisting of anchors placed only posterior to the biceps insertion compared with repairs with an additional anchor placed anterior to the biceps. The authors reported that placement of an anterior anchor had the greatest effect on external rotation, whereas presence of one or two anchors posteriorly did not affect glenohumeral rotation. Interestingly, knotless anchor repairs of type-II SLAP lesions

restore glenohumeral rotation as well as simple suture arthroscopic repair techniques without over-constraining the shoulder. In addition, the initial fixation strength of knotless anchor repairs of type-II SLAP lesions is similar to that of simple suture repairs.⁵²

Although pain relief and return of function can be expected following SLAP repair, full return to sports participation is less predictable. Morgan et al⁵³ reported 97% good to excellent clinical results and an 84% return to sport rate in a series of 102 suture anchor SLAP repairs (average patient age 33 years (15 to 72)). In this series, the presence of rotator cuff pathology had a negative impact on clinical outcome. Another series reported 94% good to excellent results in 34 patients (average patient age 26 years (16 to 35)) at an average of 33 months following surgery.⁵⁴ Although return to pre-injury level of function was reported to be 91%, only 22% of patients were able to return to the same level of sporting activity. Another study reported the results of 40 overhead athletes (average patient age 24 years (15 to 36)) following SLAP repair using suture anchors.⁵⁵ Using the Rowe scale, 90% of patients had good to excellent results, and 75% returned to their pre-injury sport level. One recent report showed good clinical results in a series of 58 patients (average patient age 45.5 years (20 to 68)) after SLAP repair using a trans-rotator cuff portal.⁵⁶ Post-operative CT arthrography demonstrated dye leakage into the subacromial space in three patients and partial-thickness rotator cuff tear in six. None of these patients was affected by this finding, although concern with this surgical approach remains.

There are few studies which prospectively randomize patients to SLAP repair or to biceps tenodesis. Boileau et al⁵⁷ evaluated ten patients (ten men) with an average age of 37 years (19 to 57) who had a SLAP repair performed with suture anchors and compared this group to 15 patients (nine men and six women) with an average age of 52 years (28 to 64) who underwent arthroscopic biceps tenodesis performed with an absorbable interference screw to the proximal humerus. In the SLAP repair group, the Constant score improved from 65 to 83 points; however, 60% of the patients were disappointed because of persistent pain or inability to return to their previous level of sports participation. In the tenodesis group, the Constant score improved from 59 to 89 points, and 93% were satisfied or very satisfied. Thirteen patients (87%) were able to return to their previous level of sports participation following biceps tenodesis, compared with only 20% after SLAP repair. Four patients with failed SLAP repairs underwent subsequent biceps tenodesis, resulting in a successful outcome and a full return to their previous level of sports activity. The authors concluded that arthroscopic biceps tenodesis can be considered an effective alternative to the repair of a type-II SLAP lesion, allowing

patients to return to a presurgical level of activity and sports participation.

Furthermore, biceps tenodesis may provide a viable alternative for the salvage of failed SLAP repairs. Ek et al⁵⁸ performed a retrospective analysis of 25 patients who had surgery for an isolated type-II SLAP lesion between 2008 and 2011. Fifteen patients underwent biceps tenodesis (average patient age 47 years (30 to 59)), with a mean follow-up of 31 months (26 to 43); ten patients underwent SLAP repair (average patient age 31 years (21 to 43)), with a mean follow-up of 35 months (25 to 52). At latest follow-up, both groups showed significant improvements in subjective shoulder value and visual analogue scale score for pain. No difference was observed in American Shoulder and Elbow Surgeons score (93.0 vs 93.5), patient satisfaction (93% vs 90%) or return to pre-injury sporting level (73% vs 60%). Analysis of the indications for treatment demonstrated that, in the large majority of 'older' patients (aged > 35 years) and patients who showed degenerative or frayed labrums, a tenodesis was performed. SLAP repairs were performed in younger and more active patients who had healthy-appearing labral tissue. There was only one failure in the tenodesis group; in the SLAP repair group, there were two cases of post-operative stiffness; all were treated successfully non-operatively. The authors concluded that both biceps tenodesis and SLAP repair can provide good to excellent results if performed selectively in patients with isolated type-II SLAP lesions.

While several studies suggest that patients below a certain age have symptoms with overhead sports or who are high-calibre athletes should have SLAP repairs, the effect of biceps tenodesis in this younger population is not well documented. As a result, some reviews suggest that SLAP repairs should be performed for patients aged < 25 years and some aged < 30 years. A study of professional baseball players by Chalmers et al⁵⁹ found that those who undergo biceps tenodesis have a 35% rate of return to their prior level of play. While pitchers have only a 17% rate of return to play, position players have an 80% rate of return to play. Of those who returned, all returned to their prior level of play. The pitchers who returned had no significant change in performance statistics.

Conclusions

Knowledge of the pertinent anatomy, pathogenesis, clinical presentation and treatment of the spectrum of injuries involving the superior glenoid labrum and biceps origin is required in treating the patient with a SLAP tear. Despite the plethora of literature regarding SLAP lesions, their clinical diagnosis remains challenging for a number of reasons. Outcomes following surgical treatment of SLAP tears vary depending on the method of treatment,

associated pathology and patient characteristics. Biceps tenodesis has been receiving increasing attention as a possible treatment for SLAP tears.

AUTHOR INFORMATION

¹Department of Orthopaedic and Traumatology, Villa del Sole Clinic, Catanzaro, Italy.

²Department of Orthopaedic and Traumatology, Hacettepe University, Ankara, Turkey.

³Cure Ortopediche Traumatologiche Messina, Italy.

⁴Department of Orthopaedic Surgery, The Johns Hopkins University, Baltimore, MD, USA.

Correspondence should be sent to: E. G. McFarland, The Johns Hopkins University, Division of Shoulder and Elbow Surgery, 10753 Falls Road, Pavilion II, Suite 215, Lutherville, MD 21093, USA.
Email: emcfar1@jhmi.edu

ICMJE CONFLICT OF INTEREST STATEMENT

None declared.

FUNDING STATEMENT

No benefits in any form have been received or will be received from a commercial party related directly or indirectly to the subject of this article.

LICENCE

© 2019 The author(s)

This article is distributed under the terms of the Creative Commons Attribution-Non Commercial 4.0 International (CC BY-NC 4.0) licence (<https://creativecommons.org/licenses/by-nc/4.0/>) which permits non-commercial use, reproduction and distribution of the work without further permission provided the original work is attributed.

REFERENCES

1. Andrews JR, Carson WG Jr, McLeod WD. Glenoid labrum tears related to the long head of the biceps. *Am J Sports Med* 1985;13:337–41.
2. Snyder SJ, Karzel RP, Del Pizzo W, Ferkel RD, Friedman MJ. SLAP lesions of the shoulder. *Arthroscopy* 1990;6:274–9.
3. Maffet MW, Gartsman GM, Moseley B. Superior labrum-biceps tendon complex lesions of the shoulder. *Am J Sports Med* 1995;23:93–8.
4. Modarresi S, Motamedi D, Jude CM. Superior labral anteroposterior lesions of the shoulder: part 2, mechanisms and classification. *AJR Am J Roentgenol* 2011;197:604–11.
5. Snyder SJ, Banas MP, Karzel RP. An analysis of 140 injuries to the superior glenoid labrum. *J Shoulder Elbow Surg* 1995;4:243–8.
6. Handelberg F, Willems S, Shahabpour M, Huskin JP, Kuta J. SLAP lesions: a retrospective multicenter study. *Arthroscopy* 1998;14:856–62.
7. Kim TK, Queale WS, Cosgarea AJ, McFarland EG. Clinical features of the different types of SLAP lesions: an analysis of one hundred and thirty-nine cases. *J Bone Joint Surg [Am]* 2003;85-A:66–71.
8. Cooper DE, Arnoczky SP, O'Brien SJ, et al. Anatomy, histology, and vascularity of the glenoid labrum. An anatomical study. *J Bone Joint Surg [Am]* 1992;74-A:46–52.

- 9. Vangness CT Jr, Jorgenson SS, Watson T, Johnson DL.** The origin of the long head of the biceps from the scapula and glenoid labrum. An anatomical study of 100 shoulders. *J Bone Joint Surg [Br]* 1994;76:951–4.
- 10. Arai R, Kobayashi M, Harada H, et al.** Anatomical study for SLAP lesion repair. *Knee Surg Sports Traumatol Arthrosc* 2014;22:435–41.
- 11. Tuoheti Y, Itoi E, Minagawa H, et al.** Attachment types of the long head of the biceps tendon to the glenoid labrum and their relationships with the glenohumeral ligaments. *Arthroscopy* 2005;21:1242–9.
- 12. Rao AG, Kim TK, Chronopoulos E, McFarland EG.** Anatomical variants in the anterosuperior aspect of the glenoid labrum: a statistical analysis of seventy-three cases. *J Bone Joint Surg [Am]* 2003;85-A:653–9.
- 13. Clavert P, Bonnet F, Kempf JF, et al.** Contribution to the study of the pathogenesis of type II superior labrum anterior-posterior lesions: a cadaveric model of a fall on the outstretched hand. *J Shoulder Elbow Surg* 2004;13:45–50.
- 14. Bey MJ, Elders GJ, Huston LJ, et al.** The mechanism of creation of superior labrum, anterior, and posterior lesions in a dynamic biomechanical model of the shoulder: the role of inferior subluxation. *J Shoulder Elbow Surg* 1998;7:397–401.
- 15. Kuhn JE, Lindholm SR, Huston LJ, Soslowsky LJ, Blasler RB.** Failure of the biceps superior labral complex: a cadaveric biomechanical investigation comparing the late cocking and early deceleration positions of throwing. *Arthroscopy* 2003;19:373–9.
- 16. Shepard MF, Dugas JR, Zeng N, Andrews JR.** Differences in the ultimate strength of the biceps anchor and the generation of type II superior labral anterior posterior lesions in a cadaveric model. *Am J Sports Med* 2004;32:1197–1201.
- 17. Pradhan RL, Itoi E, Hatakeyama Y, Urayama M, Sato K.** Superior labral strain during the throwing motion. A cadaveric study. *Am J Sports Med* 2001;29:488–92.
- 18. Yeh ML, Lintner D, Luo ZP.** Stress distribution in the superior labrum during throwing motion. *Am J Sports Med* 2005;33:395–401.
- 19. Sodha S, Srikumaran U, Choi K, Borade AU, McFarland EG.** Clinical assessment of the dynamic labral shear test for superior labrum anterior and posterior lesions. *Am J Sports Med* 2017;45:775–81.
- 20. Bennett WF.** Specificity of the Speed's test: arthroscopic technique for evaluating the biceps tendon at the level of the bicipital groove. *Arthroscopy* 1998;14:789–96.
- 21. Hamner DL, Pink MM, Jobe FW.** A modification of the relocation test: arthroscopic findings associated with a positive test. *J Shoulder Elbow Surg* 2000;9:263–7.
- 22. Kibler WB.** Specificity and sensitivity of the anterior slide test in throwing athletes with superior glenoid labral tears. *Arthroscopy* 1995;11:296–300.
- 23. McFarland EG, Kim TK, Savino RM.** Clinical assessment of three common tests for superior labral anterior-posterior lesions. *Am J Sports Med* 2002;30:810–5.
- 24. O'Brien SJ, Pagnani MJ, Fealy S, McGlynn SR, Wilson JB.** The active compression test: a new and effective test for diagnosing labral tears and acromioclavicular joint abnormality. *Am J Sports Med* 1998;26:610–3.
- 25. Tokish JM, Decker MJ, Ellis HB, Torry MR, Hawkins RJ.** The belly-press test for the physical examination of the subscapularis muscle: electromyographic validation and comparison to the lift-off test. *J Shoulder Elbow Surg* 2003;12:427–30.
- 26. Calvert E, Chambers GK, Regan W, Hawkins RH, Leith JM.** Special physical examination tests for superior labrum anterior posterior shoulder tears are clinically limited and invalid: a diagnostic systematic review. *J Clin Epidemiol* 2009;62:558–63.
- 27. Dessaur WA, Magarey ME.** Diagnostic accuracy of clinical tests for superior labral anterior posterior lesions: a systematic review. *J Orthop Sports Phys Ther* 2008;38:341–52.
- 28. Hegedus EJ, Goode A, Campbell S, et al.** Physical examination tests of the shoulder: a systematic review with meta-analysis of individual tests. *Br J Sports Med* 2008;42:80–92. discussion.
- 29. Hegedus EJ, Goode AP, Cook CE, et al.** Which physical examination tests provide clinicians with the most value when examining the shoulder? Update of a systematic review with meta-analysis of individual tests. *Br J Sports Med* 2012;46:964–78.
- 30. Karlsson J.** Physical examination tests are not valid for diagnosing SLAP tears: a review. *Clin J Sport Med* 2010;20:134–5.
- 31. Sandrey MA.** Special physical examination tests for superior labrum anterior-posterior shoulder tears: an examination of clinical usefulness. *J Athl Train* 2013;48:856–8.
- 32. Kim SH, Ha KI, Ahn JH, Kim SH, Choi HJ.** Biceps load test II: A clinical test for SLAP lesions of the shoulder. *Arthroscopy* 2001;17:160–4.
- 33. Kim SH, Ha KI, Han KY.** Biceps load test: a clinical test for superior labrum anterior and posterior lesions in shoulders with recurrent anterior dislocations. *Am J Sports Med* 1999;27:300–3.
- 34. Mimori K, Muneta T, Nakagawa T, Shinomiya K.** A new pain provocation test for superior labral tears of the shoulder. *Am J Sports Med* 1999;27:137–42.
- 35. Liu SH, Henry MH, Nuccion SL.** A prospective evaluation of a new physical examination in predicting glenoid labral tears. *Am J Sports Med* 1996;24:721–5.
- 36. Nakagawa S, Yoneda M, Hayashida K, et al.** Forced shoulder abduction and elbow flexion test: a new simple clinical test to detect superior labral injury in the throwing shoulder. *Arthroscopy* 2005;21:1290–5.
- 37. Myers TH, Zemanovic JR, Andrews JR.** The resisted supination external rotation test: a new test for the diagnosis of superior labral anterior posterior lesions. *Am J Sports Med* 2005;33:1315–20.
- 38. Bedi A, Allen AA.** Superior labral lesions anterior to posterior—evaluation and arthroscopic management. *Clin Sports Med* 2008;27:607–30.
- 39. Edwards SL, Lee JA, Bell JE, et al.** Nonoperative treatment of superior labrum anterior posterior tears: improvements in pain, function, and quality of life. *Am J Sports Med* 2010;38:1456–61.
- 40. Jang SH, Seo JG, Jang HS, Jung JE, Kim JG.** Predictive factors associated with failure of nonoperative treatment of superior labrum anterior-posterior tears. *J Shoulder Elbow Surg* 2016;25:428–34.
- 41. Onyekwelu I, Khatib O, Zuckerman JD, Rokito AS, Kwon YW.** The rising incidence of arthroscopic superior labrum anterior and posterior (SLAP) repairs. *J Shoulder Elbow Surg* 2012;21:728–31.
- 42. Vogel LA, Moen TC, Macaulay AA, et al.** Superior labrum anterior-to-posterior repair incidence: a longitudinal investigation of community and academic databases. *J Shoulder Elbow Surg* 2014;23:e119–26.
- 43. Patterson BM, Creighton RA, Spang JT, Roberson JR, Kamath GV.** Surgical trends in the treatment of superior labrum anterior and posterior lesions of the shoulder: analysis of data from the American Board of Orthopaedic Surgery certification examination database. *Am J Sports Med* 2014;42:1904–10.
- 44. Erickson BJ, Jain A, Abrams GD, et al.** SLAP lesions: trends in treatment. *Arthroscopy* 2016;32:976–81.

- 45. Kibler WB, Sciascia A.** Current practice for the surgical treatment of SLAP lesions: A systematic review. *Arthroscopy* 2016;32:669–83.
- 46. Brockmeyer M, Tompkins M, Kohn DM, Lorbach O.** SLAP lesions: a treatment algorithm. *Knee Surg Sports Traumatol Arthrosc* 2016;24:447–55.
- 47. Cohen DB, Coleman S, Drakos MC, et al.** Outcomes of isolated type II SLAP lesions treated with arthroscopic fixation using a bioabsorbable tack. *Arthroscopy* 2006;22:136–42.
- 48. Rhee YG, Lee DH, Lim CT.** Unstable isolated SLAP lesion: clinical presentation and outcome of arthroscopic fixation. *Arthroscopy* 2005;21:1099.
- 49. Samani JE, Marston SB, Buss DD.** Arthroscopic stabilization of type II SLAP lesions using an absorbable tack. *Arthroscopy* 2001;17:19–24.
- 50. Domb BG, Ehteshami JR, Shindle MK, et al.** Biomechanical comparison of 3 suture anchor configurations for repair of type II SLAP lesions. *Arthroscopy* 2007;23:135–40.
- 51. McCulloch PC, Andrews WJ, Alexander J, et al.** The effect on external rotation of an anchor placed anterior to the biceps in type 2 SLAP repairs in a cadaveric throwing model. *Arthroscopy* 2013;29:18–24.
- 52. Uggen C, Wei A, Glousman RE, et al.** Biomechanical comparison of knotless anchor repair versus simple suture repair for type II SLAP lesions. *Arthroscopy* 2009;25:1085–92.
- 53. Morgan CD, Burkhart SS, Palmeri M, Gillespie M.** Type II SLAP lesions: three subtypes and their relationships to superior instability and rotator cuff tears. *Arthroscopy* 1998;14:553–65.
- 54. Kim SH, Ha KI, Kim SH, Choi HJ.** Results of arthroscopic treatment of superior labral lesions. *J Bone Joint Surg [Am]* 2002;84-A:981–5.
- 55. Ide J, Maeda S, Takagi K.** Sports activity after arthroscopic superior labral repair using suture anchors in overhead-throwing athletes. *Am J Sports Med* 2005;33:507–14.
- 56. Oh JH, Kim SH, Lee HK, Jo KH, Bae KJ.** Trans-rotator cuff portal is safe for arthroscopic superior labral anterior and posterior lesion repair: clinical and radiological analysis of 58 SLAP lesions. *Am J Sports Med* 2008;36:1913–21.
- 57. Boileau P, Parratte S, Chuinard C, et al.** Arthroscopic treatment of isolated type II SLAP lesions: biceps tenodesis as an alternative to reinsertion. *Am J Sports Med* 2009;37:929–36.
- 58. Ek ET, Shi LL, Tompson JD, Freehill MT, Warner JJ.** Surgical treatment of isolated type II superior labrum anterior-posterior (SLAP) lesions: repair versus biceps tenodesis. *J Shoulder Elbow Surg* 2014;23:1059–65.
- 59. Chalmers PN, Erickson BJ, Verma NN, D’Angelo J, Romeo AA.** Incidence and return to play after biceps tenodesis in professional baseball players. *Arthroscopy* 2018;34:747–51.