



Turf toe: a clinical update

Ali-Asgar Najefi
Luckshmana Jeyaseelan
Matthew Welck

- Turf toe is a condition that describes injury to the plantar metatarsophalangeal-sesamoid complex of the great toe.
- It is a relatively rare and debilitating condition, particularly seen in American footballers after the introduction of harder, artificial ‘turf’ surfaces.
- Turf toe represents a significant injury to the hallux and requires a high index of suspicion.
- If unrecognized, it can lead to chronic problems including reduced push-off strength, persistent pain, progressive deformity and eventual joint degeneration.
- Patients with chronic injuries may have worse outcomes, and therefore early, accurate diagnosis and initiation of treatment play a vital role.
- A multidisciplinary team approach is key for successful return to sport.

Keywords: hallux; plantar plate; rehabilitation; rugby; football; push off; sesamoid

Cite this article: *EFORT Open Rev* 2018;3:501-506.
DOI: 10.1302/2058-5241.3.180012

Background

Turf toe injury was first described in 1976 by Bowers and Martin at the University of West Virginia.¹ It describes a hyperextension injury to the hallux metatarsophalangeal (MTP) joint that injures the plantar soft tissue structures of the MTP joint.

The name originated following the increase in these injuries seen in American footballers after the introduction of firm artificial playing surfaces and flexible footwear.¹

Epidemiology

The overall incidence of turf toe injuries in American national college football players is 0.062 per 1000 athlete-exposures.² There is an average of 10.1 days lost due to injury. Rodeo et al found that in a survey of 80 active

professional American football players, 45% had suffered turf toe injuries in their professional careers, with 83% occurring on artificial turf.³ Clanton and Ford found that foot injuries were the third leading cause of missed playing time and that a large portion of these injuries involved the hallux MTP joint.⁴

There has been an apparent increase in the occurrence of turf toe injuries, possibly due to the use of more flexible, lighter shoes or changes in surface–cleat interaction.⁵ A further reason for this increase may be greater awareness of the injury and earlier identification by athletic trainers and physicians. George et al showed a significantly higher injury rate on third-generation artificial surfaces compared with natural grass;² however, a study of high school athletes comparing injuries on modern artificial turf with injuries on natural grass showed no difference in injury patterns.⁶

In rugby players, a prospective study following rugby players over four seasons showed that turf toe accounts for 11% of all foot injuries, which is equivalent to 0.4% of players affected per season. On average, these patients took 22 days to return to full fitness. The one patient in the series with a ruptured plantar plate required 89 days for recovery.⁷

Mechanism of injury

The majority of turf toe injuries occur as a result of contact with the playing surface or contact with another player.² This essentially causes an axial load, on a hyperextended MTP joint, with fixed equinus at the ankle. The load drives the hallux MTP joint into hyperextension, which leads to attenuation or disruption of the plantar capsular ligamentous complex supporting the joint.⁸ The plantar plate complex is designed to resist dorsiflexion of the first MTP joint, but these tissues can be torn, with the degree of damage dependent on the severity of injury and forces to the joint (Fig. 1).

Depending on the position of the hallux at the time of injury, variations from the classic hyperextension injury can occur. If the force vector on the great toe at the time of

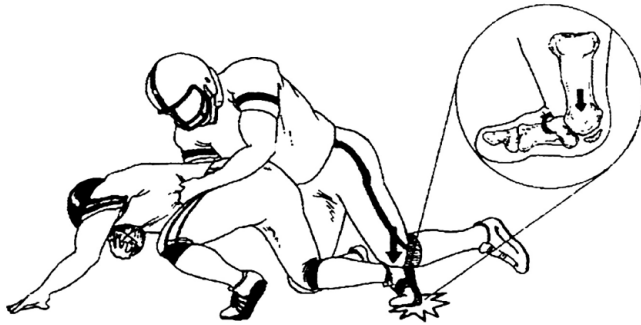


Fig. 1 Mechanism of injury to cause a turf toe - an axial load, on a hyperextended MTP joint, with fixed equinus at the ankle.

impact has a medial component to it, greater injury occurs to the medial and plantar-medial ligamentous structures, as well as the tibial sesamoid complex. As a result, there is a relative contracture of the lateral structures (lateral sesamoid complex and adductor hallucis), leading to a traumatic hallux valgus and bunion deformity.⁹⁻¹¹

Pathogenesis/Anatomy

Most of the stability of the hallux MTP joint comes from the capsule, ligaments and short flexor complex. Fan-shaped medial and lateral collateral ligaments provide valgus and varus stability, respectively. Each collateral comprises a collateral component between the first metatarsal and proximal phalanx and a metatarso-sesamoid slip.

The plantar plate is the thickened plantar capsule that courses from a weaker attachment on the metatarsal head to a firm attachment on the proximal phalanx.

The hallux MTP joint has a number of dynamic stabilizers. They are the short flexor complex (the flexor hallucis brevis (FHB) and the sesamoids embedded in the FHB tendons), the adductor hallucis and the abductor hallucis tendons.¹² The FHB tendon inserts on the proximal phalanx in confluence with the plantar plate. As the FHB moves distally toward its insertion, the tendon envelops the medial (tibial) and lateral (fibular) sesamoids.

The hallux sesamoid bones are paired ossicles of the foot. They function as a fulcrum to increase the leverage of both flexor hallucis brevis and longus. The medial sesamoid is typically larger than the lateral sesamoid and sits more distal. The medial sesamoid is frequently bipartite and the lateral sesamoid is occasionally so. The hallux sesamoids elevate the first metatarsal head, providing a moment arm that augments plantar flexion of the first MTP joint.^{13,14} The flexor hallucis longus (FHL) tendon courses plantar to the metatarsal head, between the sesamoids in a separate sheath. At the level of the sesamoids, the abductor hallucis and adductor hallucis tendons conjoin with the medial and lateral heads of the FHB, respectively.

In normal gait, the capsular ligamentous complex of the hallux MTP joint must withstand 40% to 60% of body weight. This can increase to two to three times the body weight in baseline athletic activity and can reach as much as eight times the body weight with a running jump.¹⁵ Injury to this complex may decrease first MTP joint competence and push-off strength, which can affect performance.^{5,11,16,17}

Sesamoid injury has been described to occur alongside turf toe injury.^{18,19} Sesamoids may fracture or the synchondrosis may be injured if the sesamoids are bipartite or tripartite. A pre-existing bipartite sesamoid bone may predispose the patient to this injury after frequent high intensity stresses.²⁰ Rodeo et al reported on four cases of bipartite sesamoids in athletes.²¹ Three of the four cases were managed conservatively with observation but went on to have the distal pole of the sesamoid resected following progressive diastasis of the sesamoid. One patient had an acute repair of the capsule. Each of their cases had 3 to 5 mm of diastasis visible on initial post-injury radiographs signifying acute injury to the bi- or tripartite sesamoids.²¹

Classification

A classification system has been modified over several years but was initially proposed by Clanton and Ford.⁴

Grade 1: Ligamentous complex sprain. Attenuation of plantar structures with localized swelling and minimal ecchymosis. It represents a micro-tear of the ligament. The first MTP joint is still competent and can resist dorsiflexion. Treatment for this is symptomatic and return to sport is expected within a week.

Grade 2: Partial ligamentous tear. Injuries include partial tear of the plantar structures with moderate swelling and restricted motion.

Grade 3: Complete ligamentous tear. Injuries are of complete disruption to the plantar structures with hallux flexion weakness and instability. This may occur with a dorsal dislocation. There may also be concomitant injury to the articular surface of the MTP joint as the proximal phalanx impacts or shears across the articular surface of the metatarsal head.²² Surgery is often indicated in this group, especially with higher-level athletes. Recovery can take up to six months.^{17,23}

Clinical presentation

A thorough, targeted history and examination provide important clues to the diagnosis.

These injuries frequently occur on artificial playing surfaces, thought to be attributed to the fact that these surfaces are often harder. The patient usually describes a mechanism of injury that includes first MTP joint hyperextension and

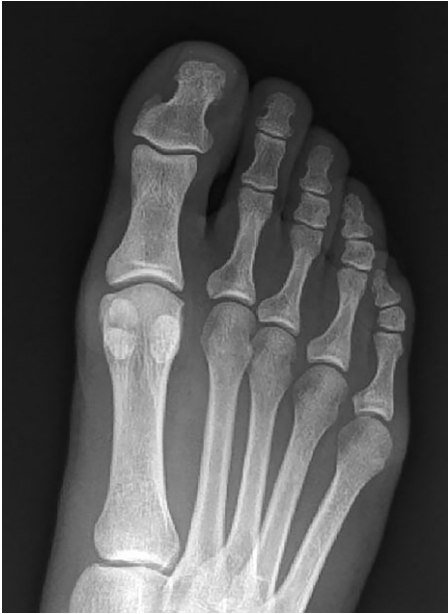

Fig. 2 Normal AP radiograph of the right foot. It demonstrates the larger size of the medial sesamoid compared with the lateral sesamoid and it sits more distal. The medial hallux sesamoid is frequently bipartite.

may recall sustaining a compressive axial load while the ankle was plantar flexed and the hallux extended.

The patient will complain of pain, stiffness of the MTP joint and swelling. They may describe weakness in push-off. Clinical assessment begins with inspection of the great toe for swelling, ecchymosis or malalignment, as well as palpation of the collateral ligaments, dorsal capsule and plantar sesamoid complex. Localizing pain proximal to the sesamoids suggests a strain of the FHB musculotendinous junction and not an unstable turf toe injury, which typically occurs distal to the sesamoids.

Strength should be assessed with a focus on the FHL and FHB. The FHL tendon is responsible for flexing the MTP joint but attaches to the distal phalanx and also flexes the interphalangeal (IP) joint. Isolated FHB strength assessment should be attempted by stabilizing the IP joint in neutral position and then instructing the patient to flex the MTP joint against resistance applied to the proximal phalanx. A decrease in active flexion strength, compared with the contralateral side, might suggest a disruption of the FHB or plantar plate.

Stability testing should be performed by examining anteroposterior (AP) translation and varus-valgus stability. The vertical Lachman test for the first MTP joint is conducted by stabilizing the first metatarsal superiorly and inferiorly with one hand while applying an anterior and posterior translational force to the proximal phalanx to feel for dorsal or plantar subluxation. A positive Lachman test demonstrates AP instability.¹²

Investigations

Standard weight-bearing AP, lateral and sesamoid axial radiographs should be obtained (Fig. 2). The bony structures in the radiographs are frequently normal. A small fleck of bone from the proximal phalanx or distal sesamoid may indicate a capsular disruption or avulsion. Comparison radiographs of the contralateral foot are useful to compare sesamoid location beneath the first metatarsal head. Patients with a plantar plate rupture will have proximal migration of one or both sesamoids.^{20,24} Sesamoid retraction of 3 mm or greater (compared with the intact side) has a high likelihood of having sustained a significant injury to the ligaments of the plantar plate complex.²⁵

A forced dorsiflexion lateral view of the hallux MTP joint should be obtained if there is clinical suspicion of plantar plate injury. With complete disruption of the plantar plate the sesamoids will not track distally with great toe extension, remaining beneath the metatarsal head. Fluoroscopy can demonstrate the inability of the sesamoids to track distally with extension at the MTP joint. Sesamoid motion can be compared with the contralateral side.^{16,23}

MRI is a useful and accurate tool for evaluating plantar plate injuries (Fig. 3). The normal plantar plate appears as a dense band of low signal connecting the hallux sesamoids (or the metatarsal head in the case of the lesser metatarsals) to the plantar base of the proximal phalanx and is seen best on sagittal and short-axis images. MRI findings in plantar plate injury vary with the severity and acuity of the injury. Full-thickness plantar plate tears will appear as focal discontinuity of the plantar plate with retraction and a fluid gap (Fig. 4), whereas sprains and partial thickness tears may show either thinning or thickening with indistinctness of the plantar plate.^{24,26}

Management

Non-operative treatment

The early stages of treatment are similar in all grades of injury. Rest, ice, compression and elevation can be applied to help reduce pain and swelling. Anti-inflammatory medications can also be used to help relieve acute symptoms.

Grade 1 injury usually allows return to athletic competition as tolerated, with little or no loss of playing time. After the acute phase of injury, the great toe will benefit from taping in a slightly plantar-flexed position to limit motion and provide compression. The athlete should use a stiff-soled shoe with a turf toe plate insert or a custom orthotic with a Morton's extension to limit hallux motion.¹² If the injury is more medially based and there is concern of a traumatic hallux valgus, a toe separator between the hallux and second toes can provide further support.

For Grade 2 injuries, symptomatic treatment is warranted and may include a walking boot and protected

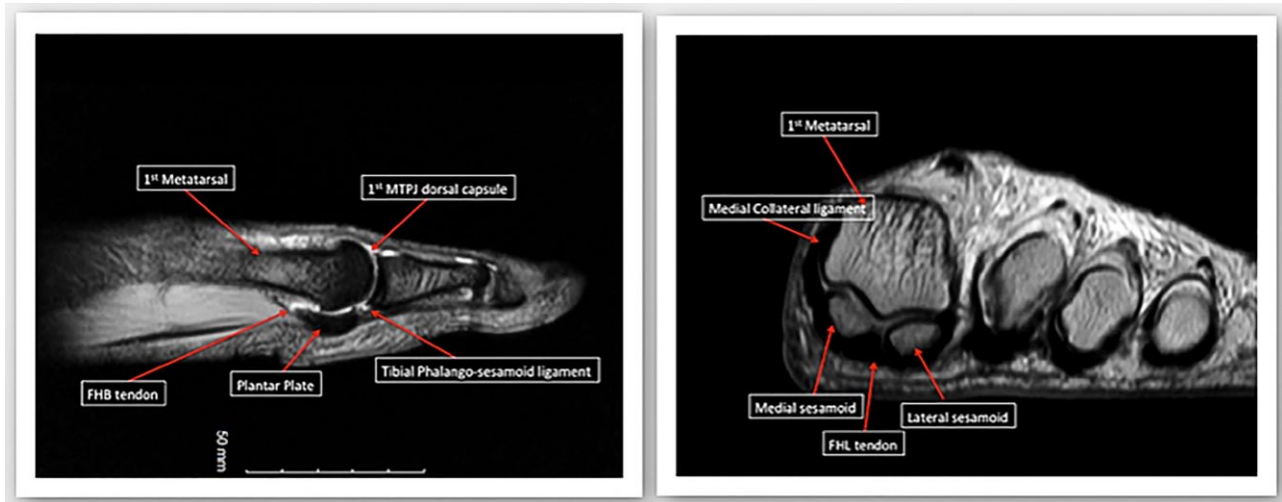


Fig. 3 Normal MRI images of the first MTP joint. The left image shows a sagittal T2 image and the right is a proton density-weighted coronal image. The plantar plate is the greatly thickened plantar capsule. The hallux MTP joint is dynamically stabilized by the short flexor complex (the FHB and the sesamoids embedded in the FHB tendons), the adductor hallucis and the abductor hallucis tendons. The FHB tendon inserts on the proximal phalanx in confluence with the plantar plate. As the FHB moves distally toward its insertion, the tendon envelops the medial (tibial) and lateral (fibular) sesamoids. The flexor hallucis longus tendon courses plantar to the metatarsal head, between the sesamoids in a separate sheath.

weight-bearing. If the capsule has a substantial injury as seen on MRI but no instability on provocative testing, then casting for four to six weeks with the MTP joint in plantar flexion may be prudent. At three to five days post-injury, gentle range of motion can begin, with passive plantar flexion to prevent sesamoid adhesions while protecting the injured and healing plantar soft tissues.¹⁶ The patient should be carefully followed in these early stages of recovery because deformity can progress with athletic activity. Low-impact exercise, such as bicycling, elliptical training and hydrotherapy, can be attempted with toe protection. Cortisone or anaesthetic agents are not advised.^{16,27,28} There is some evidence to support biological therapies (such as platelet-rich plasma (PRP) and autologous conditioned plasma (ACP) injections).²⁹ Once the toe can tolerate low-impact exercise, the athlete can progress to higher impact activities, followed by explosive or push-off activities. Footwear should be adjusted to include the use of a turf toe plate or Morton's extension.²⁸

Grade 3 injury may require eight weeks or longer of recovery and immobilization. The hallux MTP should have 50° to 60° of painless passive dorsiflexion before running or explosive activities are attempted.³⁰ It may take up to six months for complete resolution of symptoms.

Surgical treatment

Fewer than 2% of turf toe injuries require operative intervention.²

In complete plantar plate ruptures, a dual-incision technique allows access to the medial and lateral aspects

of the plantar capsular ligamentous complex.⁵ Other techniques have described stabilizing the first MTP joint by anchoring the plantar plate to the extensor hallucis longus tendon.³¹ Other approaches include a medial 'J' incision together with plantar incisions.¹⁶

The capsular disruption typically occurs distal to the sesamoid bones. If this is the only injury, the plantar soft-tissue structures can be primarily repaired end-to-end with non-absorbable sutures. Bone tunnels can also be used to directly attach the plantar plate to the base of the proximal phalanx.³² If a traumatic hallux valgus occurs with a primarily medial soft-tissue injury, a lateral release can be performed either percutaneously, or via the dorsal approach, to balance the hallux MTP joint.

If the sesamoid is fractured or fragmented, one pole of the sesamoid should be preserved, if possible. A smaller distal pole is amenable to excision. A drill hole in the larger proximal pole may allow soft-tissue repair to the sesamoid bone. If complete sesamoidectomy is necessary, then the abductor hallucis tendon should be transferred into the soft-tissue defect of the excised sesamoid to provide collagen to the site of injury and allow the abductor to function as a plantar restraint to dorsiflexion while augmenting flexion at the MTP joint.²³

Chronic presentation

Missed diagnoses can lead to unrestrained dorsiflexion of the injured toe. This can lead to longitudinal tears of the FHL tendon, hallux rigidus from repetitive joint impaction, progressive hallux valgus or varus deformity, or a cock-up toe with a hallux IP joint flexion contracture.

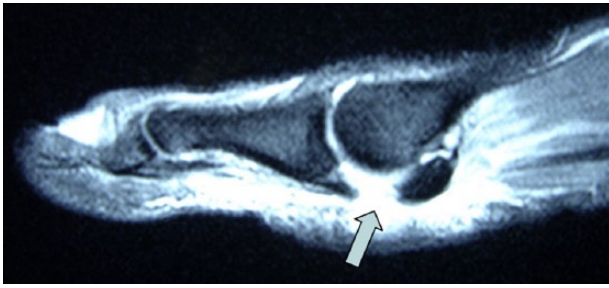


Fig. 4 A sagittal T2 MR image demonstrating a grade 3 turf toe injury.

Surgical intervention includes fasciotomy or tendon lengthening. A Girdlestone-Taylor transfer can be performed for cock-up deformities; FHL can be transferred to the proximal phalanx (via drill hole and biotenodesis screw) or FHL can be split and re-approximated to the dorsal extensor complex. An IP fusion can be performed if the contracture is fixed. Surgical options for hallux rigidus include cheilectomy and more definitive options such as arthroplasty or fusion.⁵

Prognosis

Clanton and Ford reported on surgical and non-surgical patients with a five-year follow-up: 50% described persistent symptoms of pain and stiffness at the hallux MTP joint.⁴ Brophy et al measured hallux MTP range of motion after recovery from turf toe injury, reporting a statistically significant decrease in dorsiflexion compared with uninjured toes.³³

Anderson described 19 high-level competitive athletes with disabling turf toe injuries. Nine required operative repair and seven of these returned to full athletic participation with restoration of plantar stability. No complications from surgery were reported.²³

One case report in an elite footballer showed that early surgical intervention and attentive rehabilitation ensured return to first team playing after only 5.5 months. At the two-years eight-month follow-up, the patient was still playing competitive elite-level first team football.²⁰

Faltus et al described five cases: two were grade 2 injuries and three were grade 3 injuries which required surgical repair. Recovery from the conservatively managed grade 2 athletes showed a return to elite-level sport in two to three months. In those who underwent surgical repair, return to sport was in four to five months.²⁸

Drakos et al reported two cases managed surgically with repair of the plantar plate and FHL and soft-tissue repair to the sesamoids.¹² Both of these patients had a return to sport in six months. One patient had a grade 2 tear which was conservatively managed; he returned to sport in five months.

Conclusion

Turf toe is a rare and debilitating condition that requires a high index of suspicion on presentation to prevent missed injuries and chronic sequelae. They require accurate diagnosis and early definitive management. Grade 1 and 2 injuries have better outcomes and earlier return to sport.

There is a paucity of literature that evaluates the benefits of surgery over conservative interventions. A recent systematic review presented at the International Sports Science and Sports Medicine Conference 2017 by Hainsworth et al aimed to address in what circumstances operative intervention is indeed superior to conservative management of turf toe in adults.³⁴ The primary outcome measure was the time to return to pre-injury activity with the secondary outcome of the time to symptom resolution. Seven studies met the inclusion criteria. Three patients were successfully managed conservatively, returning to athletic activity, on average, at 12 weeks. Seventeen patients underwent surgical intervention with an average return to athletic activity at 18 weeks. Operative intervention was shown to give a successful outcome in patients with grade 3 turf toe injuries or those who have failed conservative management. However, it was felt that there was insufficient evidence to determine whether operative intervention is superior to conservative management.

Athletes with reduced dorsiflexion of the first toe after turf toe injury may be at greater risk of earlier first MTP joint arthritis. Further work is needed to investigate whether this injury can be prevented in this cohort of patients.³³ Furthermore, the timing of surgery has not been investigated. It is reasonable to assume that patients with chronic injuries may have a worse outcome, and therefore it is essential to diagnose and treat this problem early. Appropriate clinical decision-making and a multidisciplinary team approach are key for a safe return to sport.

AUTHOR INFORMATION

Foot & Ankle Unit, Royal National Orthopaedic Hospital, UK.

Correspondence should be sent to: A. Najefi, Foot & Ankle Unit, Royal National Orthopaedic Hospital NHS Trust, Stanmore, Middlesex, HA7 4LP, UK.

Email: anajefi@doctors.org.uk

ICMJE CONFLICT OF INTEREST STATEMENT

None declared.

FUNDING STATEMENT

No benefits in any form have been received or will be received from a commercial party related directly or indirectly to the subject of this article.

LICENCE

© 2018 The author(s)

This article is distributed under the terms of the Creative Commons Attribution-Non Commercial 4.0 International (CC BY-NC 4.0) licence (<https://creativecommons.org/licenses/by-nc/4.0/>) which permits non-commercial use, reproduction and distribution of the work without further permission provided the original work is attributed.

REFERENCES

1. **Bowers KD, Martin RB.** Turf-toe: a shoe-surface related football injury. *Med Sci Sports* 1976;8:81-83.
2. **George E, Harris HS, Dragoo JL, Hunt KJ.** Incidence and risk factors for turf toe injuries in intercollegiate football: data from the National Collegiate Athletic Association Injury Surveillance System. *Foot Ankle Int* 2013;35:108-115.
3. **Rodeo SA, O'Brien SJ, Warren RF, Barnes R, Wickiewicz TL.** Turf toe: diagnosis and treatment. *Phys Sportsmed* 1989;17:132-147.
4. **Clanton TO, Ford JJ.** Turf toe injury. *Clin Sports Med* 1994;13:731-741.
5. **McCormick JJ, Anderson RB.** The great toe: failed turf toe, chronic turf toe, and complicated sesamoid injuries. *Foot Ankle Clin* 2009;14:135-150.
6. **Meyers MCBB.** Incidence, causes, and severity of high school football injuries on FieldTurf versus natural grass: a 5-year prospective study. *Am J Sports Med* 2004;32:1626-1638.
7. **Pearce CJ, Brooks JHM, Kemp SPT, Calder JDF.** The epidemiology of foot injuries in professional rugby union players. *Foot Ankle Surg* 2011;17:113-118.
8. **Mullen JE, O'Malley MJ.** Sprains - Residual instability of subtalar, Lisfranc joints, and turf toe. *Clin Sports Med* 2004;23:97-121.
9. **Douglas DP, Davidson DM, Robinson JE, et al.** Rupture of the medial collateral ligament of the first metatarsophalangeal joint in a professional soccer player. *J Foot Ankle Surg* 1997;36:388-390.
10. **Fabeck LG, Zekhnini C, Farrokh D, et al.** Traumatic hallux valgus following rupture of the medial collateral ligament of the first metatarsophalangeal joint: a case report. *J Foot Ankle Surg* 2002;41:125-128.
11. **Watson TS, Anderson RB, Davis WH.** Periarticular injuries to the hallux metatarsophalangeal joint in athletes. *Foot Ankle Clin* 2000;5:687-713.
12. **Drakos MC, Fiore R, Murphy C, DiGiovanni CW.** Plantar-plate disruptions: "the severe turf-toe injury." Three cases in contact athletes. *J Athl Train* 2015;50:553-560.
13. **Aper RL, Saltzman CL, Brown TD.** The effect of hallux sesamoid excision on the flexor hallucis longus moment arm. *Clin Orthop Relat Res* 1996;(325):209-217.
14. **Cohen BE.** Hallux sesamoid disorders. *Foot Ankle Clin* 2009;14:91-104.
15. **Stokes IA, Hutton WC, Stott JR, et al.** Forces under the hallux valgus foot before and after surgery. *Clin Orthop Relat Res* 1979;(142):64-72.
16. **McCormick JJ, Anderson RB.** Turf toe: anatomy, diagnosis, and treatment. *Sports Health* 2010;2:487-494.
17. **Coughlin MJ, Kemp TJ, Hirose CB.** Turf toe: soft tissue and osteocartilaginous injury to the first metatarsophalangeal joint. *Phys Sportsmed* 2010;38:91-100.
18. **Mouhsine E, Leyvraz PF, Borens O, et al.** Acute fractures of medial and lateral great toe sesamoids in an athlete. *Knee Surg Sports Traumatol Arthrosc* 2004;12:463-464.
19. **Pagenstert GI, Valderrabano VHB.** Medial sesamoid nonunion combined with hallux valgus in athletes: a report of two cases. *Foot Ankle Int* 2006;27:135-140.
20. **Roche AJ, Calder JD.** An atraumatic turf toe in an elite soccer player - A stress related phenomenon? *Foot Ankle Surg* 2014;20:71-73.
21. **Rodeo SA, Warren RF, O'Brien SJ, et al.** Diastasis of bipartite sesamoids of the first metatarsophalangeal joint. *Foot Ankle* 1993;14:425-434.
22. **Nihal A, Trepman E, Nag D.** First ray disorders in athletes. *Sports Med Arthrosc Rev* 2009;17:160-166.
23. **Anderson R.** Turf toe injuries of the hallux metatarsophalangeal joint. *Tech Foot Ankle Surg* 2002;1:102-111.
24. **Schein AJ, Skalski MR, Patel DB, et al.** Turf toe and sesamoiditis: what the radiologist needs to know. *Clin Imaging* 2015;39:380-389.
25. **Waldrop NE 3rd, Zirker CA, Wijdicks CA, Laprade RF, Clanton TO.** Radiographic evaluation of plantar plate injury: an in vitro biomechanical study. *Foot Ankle Int* 2013;34:403-408.
26. **Crain JM, Phanco JP, Stidham K.** MR imaging of turf toe. *Magn Reson Imaging Clin N Am* 2008;16:93-103
27. **Chinn L, Hertel J.** Rehabilitation of foot and ankle injuries in athletes. *Clin Sport Med* 2010;29:157-167.
28. **Faltus J, Mullenix K, Moorman CT, Beatty K, Easley ME.** Case series of first metatarsophalangeal joint injuries in division 1 college athletes. *Sports Health* 2014;6:519-526.
29. **Mares AV, Schreiter R, van Eck CF, Blanc R, Musahl V.** Management of athletic turf toe using biologics. *Oper Tech Orthop* 2016;26:117-121.
30. **McCormick JJ, Anderson RB.** Rehabilitation following turf toe injury and plantar plate repair. *Clin Sports Med* 2010;29:313-323.
31. **Lui TH.** Stabilization of first metatarsophalangeal instability with plantar plate tenodesis. *Foot Ankle Surg* 2008;14:211-214.
32. **Doty JF C, MJ.** Turf toe repair: a technical note. *Foot Ankle Spec* 2013;6:452-456.
33. **Brophy RH, Gamradt SC, Ellis SJ, et al.** Effect of turf toe on foot contact pressures in professional American football players. *Foot Ankle Int* 2009;30:405-409.
34. **Hainsworth L, McKinley J.** The management of turf toe – a systematic review. *Br J Sport Med* 2017;B51:A7.3-A8.