



Arthroscopic management of articular and peri-articular fractures of the upper limb

Luca Dei Giudici¹
 Andrea Faini¹
 Luca Garro²
 Agostino Tucciarone²
 Antonio Gigante¹

- The management of articular fractures is always a matter of concern. Each articular fracture is different from the other, whatever the classification system used and the surgical or non-surgical indications employed by the surgeon. The main goals remain anatomical reduction, stable fixation, loose body removal and minimal invasiveness.
- Open procedures are a compromise. Unfortunately, it is not always possible to meet every treatment goal perfectly, since associated lesions can pass unnoticed or delay treatment, and even in a 'best-case' scenario there can be complications in the long term.
- In the last few decades, arthroscopic joint surgery has undergone an exponential evolution, expanding its application in the trauma field with the development of arthroscopic and arthroscopically-assisted reduction and internal fixation (ARIF) techniques. The main advantages are an accurate diagnosis of the fracture and associated soft-tissue involvement, the potential for concomitant treatments, anatomical reduction and minimal invasiveness.
- ARIF techniques have been applied to treat fractures affecting several joints: shoulder, elbow, wrist, hip, knee and ankle.
- The purpose of this paper is to provide a review of the most recent literature concerning arthroscopic and arthroscopically-assisted reduction and internal fixation for articular and peri-articular fractures of the upper limb, to analyse the results and suggest the best clinical applications.
- ARIF is an approach with excellent results in treating upper-limb articular and peri-articular fractures; it can be used in every joint and allows treatment of both the bony structure and soft-tissues.
- Post-operative outcomes are generally good or excellent. While under some circumstances ARIF is better than a

conventional approach, the results are still beneficial due to the consistent range of movement recovery and shorter rehabilitation time.

- The main limitation of this technique is the steep learning curve, but investing in ARIF reduces intra-operative morbidity, surgical errors, operative times and costs.

Keywords: upperlimbfractures; arthroscopy; arthroscopically-assisted; fracture fixation

Cite this article: Dei Giudici L, Faini A, Garro L, Tucciarone A, Gigante A. Arthroscopic management of articular and peri-articular fractures of the upper limb. *EFORT Open Rev* 2016;1:325-331. DOI: 10.1302/2058-5241.1.160016.

Introduction

Management of an articular fracture is a matter of concern. Regardless of the classification system used and the surgical indications employed by the specialist, the main goals remain the same, i.e. anatomical reduction, stable fixation, loose body removal and a minimally invasive technique.

Diagnosis and treatment choice are made on the basis of radiographs, after grading according to a classification system. Unfortunately, it is not always possible to correctly assess joint surface continuity based solely on plain radiographs. Nonetheless, complex fracture patterns are often associated with other intra-articular lesions which should be addressed urgently.

When surgery is required, minimally invasive plate osteosynthesis (MIPO) is the most accepted technique, when applicable;¹ other options are the classical open reduction and internal fixation (ORIF), fluoroscopy-assisted procedures, and arthroscopically-assisted reduction and internal fixation (ARIF). Fluoroscopy can facilitate a percutaneous fixation, but it can lead to poor quality images² and is inadequate in the presence of comminution. Incorrect management has very poor outcomes leading to malunion or nonunion, pain, loss of function, decreased range of movement (ROM), and even after an apparently proper reduction and fixation, there can be complications.^{3,4}

Arthroscopic joint surgery has recently undergone an exponential evolution, expanding its applications in traumatology with ARIF techniques. The main advantages are accurate diagnosis of fracture and associated soft-tissue involvement, the potential for particular treatments, anatomical reduction and minimal invasiveness.⁵

The purpose of this paper is to provide a review of the recent literature concerning ARIF for articular and peri-articular fractures in the upper limb, and to propose optimal techniques in the acute setting. To this purpose, the present review was carried out by searching the most recent peer-reviewed literature for the following keywords: 'ARIF', 'arthroscopic assistance', 'arthroscopic reduction' and 'articular fractures'. The most important research databases were analysed, namely PubMed (<http://www.ncbi.nlm.nih.gov/pubmed>), Scopus (<http://www.scopus.com/>), Google Scholar (<http://scholar.google.it/>) and the Cochrane Library (<http://www.thecochranelibrary.com/view/0/index.html>). All papers related to an upper limb articular or a peri-articular fracture treatment, in which arthroscopy was used for assistance during reduction or during any phase of the surgery, were analysed. Selected papers met the following inclusion criteria: treatment of an articular or periarticular fracture; involvement of the shoulder, elbow or wrist joint; use of arthroscopy during reduction or fixation; and use of arthroscopy as an assistance tool (i.e. to verify the anatomical reduction of the articular surface). Animal and cadaveric models describing experimental arthroscopic techniques for the reduction and the fixation of a fracture were excluded. The application of the abovementioned criteria resulted in a total of 45 papers, divided into case reports, case series, technical notes and narrative reviews. Systematic reviews, randomised clinical trials and other level I and II studies were not available.

Shoulder joint

Glenoid fractures

Articular shoulder fractures can be divided into glenoid fractures, following a high-energy direct blow on the joint, and glenoid rim fractures, following traumatic dislocations.⁶

Recent technical and instrumental advances have favoured ARIF and very promising results have been obtained,⁷ but more studies are needed, especially comparing ARIF with mini-open approaches.

For glenoid fractures, cannulated screws implanted percutaneously by a trans-subscapularis approach offer a great advantage when compared to an ORIF,⁸ though, if there is extensive comminution, or if the fracture fragments are too small, it is preferable to perform suture fixation.⁹ It must be kept in mind that when there is bone loss <25%, it is better to choose a suture anchor fixation rather

than screws. Gigante et al¹⁰ reported on a case of a Y-shaped glenoid fracture easily treated with ARIF with percutaneous pin fixation, resulting in a complete recovery at the latest follow-up (see Figs 1 to 3).

As for glenoid rim fractures, incidence can vary between 4% and 70%, and up to 30% of shoulder dislocations can also present with a bony Bankart lesion.¹¹ Arthroscopic assistance for glenoid rim fractures was proposed by Tauber et al,⁸ associated with cannulated screw fixation and recommended for precise anatomical restoration, full ROM recovery and almost zero complications. Marsland and Ahmed,¹² on a cadaveric model, investigated common portals used during ARIF for glenoid rim fractures; Neviaser stated that superior and posterior portals are safe and practical to use, allowing, in combination, a good coverage of every portion of the glenoid rim, while anterior and posterior portals are at risk for neurovascular injuries. An ARIF approach for glenoid rim fractures can allow the simultaneous treatment of greater tuberosity fractures and many other associated intra-articular lesions. Unfortunately, this method is not always technically possible as there could be too little bone stock, too much displacement of the fragments or a fixed retraction. Gupta et al¹¹ proposed a good, straightforward and reproducible technique: they performed a modification of the Sugaya technique and fixed a bony Bankart lesion with a postero-lateral suture positioning the inferior suture anchor through the subscapularis muscle. The 'double-pulley dual-row' technique proposed by Zhang and Chunyan¹³ maximises the contact area, distributing stress forces on a wider surface with better biomechanics and healing. It is indicated for CT-confirmed bony Bankart lesions with a base width less than 5 mm, offering a secure fixation of the bulky fragment. If the fracture site is posterior, there is indication for surgery in the presence of a bone loss >33%.¹²

For posterior fractures, a posterior Bankart repair is not sufficient in some cases and an arthroscopic McLaughlin procedure, or 'reverse remplissage', was proposed recently, consisting of a subscapularis tenodesis with double mattress arthroscopic sutures.¹⁴ It is indicated in wide defects, for patients at risk of recurrent joint dislocation during normal activity, and after the failure of conservative treatment.¹⁴ Other indications suggested for this technique are <20% of humeral head involvement, <8 mm lesion depth and recurrent instability.¹⁴

Distal clavicle fractures

A distal clavicle fracture happens in between 10% and 17% of all clavicle fractures.¹⁵ Neer's type 2 fracture often develops nonunion^{15,16} and even surgical treatment can have a high frequency of complications.

Recent techniques have been proposed in search of an arthroscopic reduction and a minimally invasive fixation,¹⁶⁻¹⁸ with good subjective outcomes, functionality,

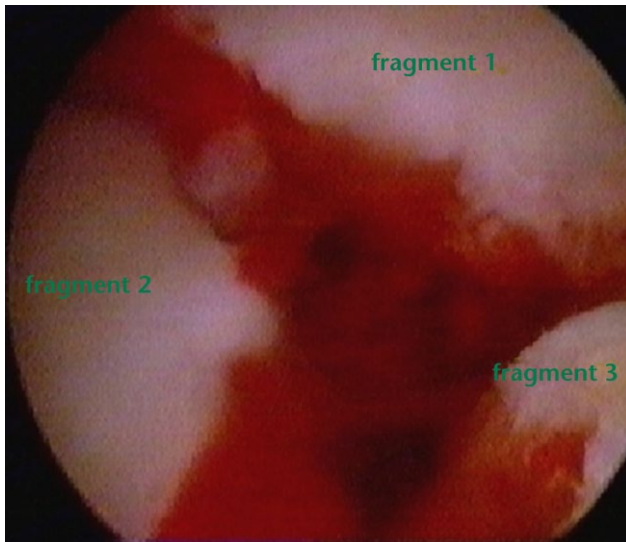


Fig.1 Arthroscopic view of three-fragment glenoid fracture.

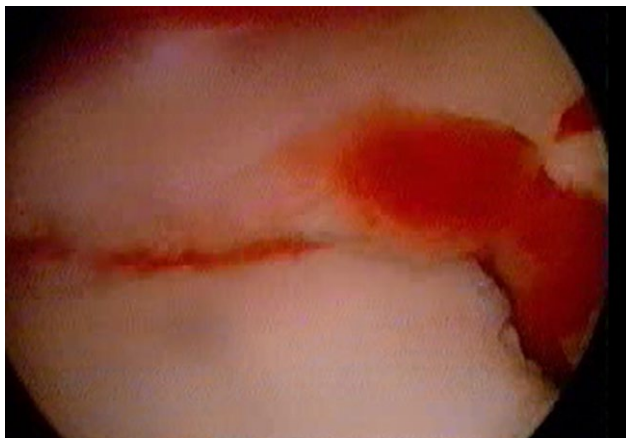

Fig. 2 Arthroscopic view of intra-operative reduction of a three-fragment glenoid fracture.

symmetrical ROM and a potential to return to previous activities after only three months and to full sporting activities at six months. The main explanation is that in those kinds of fractures, the ligaments are intact or partially injured and, to obtain fracture healing, it is only necessary to realign the fractured portions. Takase, Kono and Yamamoto¹⁶ developed ARIF for Neer type 2 fractures using an artificial ligament with EndoButton (Smith & Nephew; Andover, Massachusetts) fixation on the coracoid, and a screw with a washer on the clavicle. With the technique proposed by Motta et al,¹⁷ consisting of fixation with the AC TightRope (Arthrex; Naples, Florida), the biggest concern appeared to be age >60 years, which was also a key negative prognostic factor. It allows an improved view of the coracoid process and of the tunnel to be prepared, a prompt diagnosis of associated lesions in the shoulder joint, a better aesthetic outcome, a closed reduction without the need for a delayed hardware removal, better pain

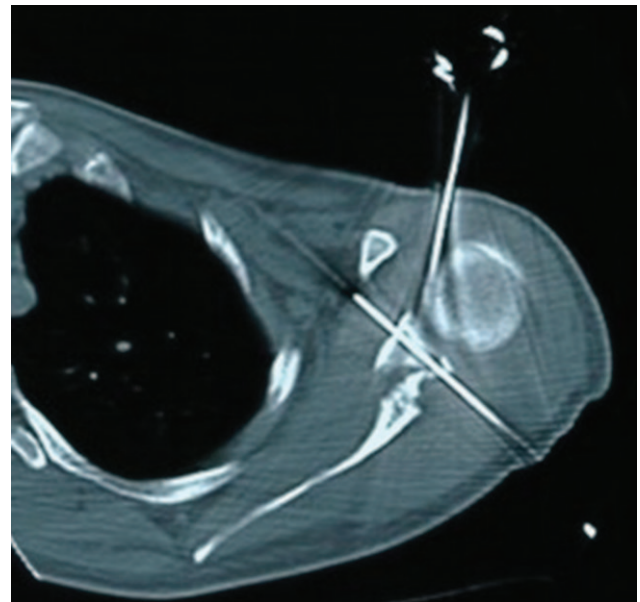


Fig. 3 CT scan of the three-fragment glenoid fracture after reduction with the ARIF approach, showing the fixation with K-wires, and the flush articular surface.

relief and the application of a local regional anaesthetic.¹⁷ If a secondary fracture caused by button erosion is possible, this is avoided by using a tunnel no larger than 4 mm.¹⁸ Checchia et al¹⁷ proposed arthroscopy during cerclage fixation using a double loop suture for distal clavicle fractures with excellent results. Nourissat et al¹⁹ described a similar procedure using a FiberWire (Arthrex; Naples, Florida) suture. Pujol et al²⁰ preferred a double TightRope for ARIF of Latarjet's fractures with good results, comparable with other easier techniques.

Humeral greater tuberosity fractures

Greater tuberosity fractures represent about 20% of proximal humeral fractures.²¹

Cannulated screws, usually used in the management of greater tuberosity fractures, are not indicated in osteoporotic patients and present some serious complications such as increasing comminution or dislocation of small fragments.

ARIF allows for better primary stability, improved healing and anatomical reduction. Park et al²² proposed an interesting 'suture-bridge' technique for occult greater tuberosity fractures in patients with chronic pain, weakness, ROM reduction and following the failure of conservative treatment. Lesser tuberosity fracture as an associated condition was also described in a case report by Pauly et al²³ in which they opted for ARIF with 'suture-anchors' and cannulated screws.

Proximal humeral fractures

Endomedullary nailing is the 'gold standard' in the treatment of Codman fractures with two or three fragments,

although it creates functional damage to the supraspinatus, especially at its insertion point.²⁴

Arthroscopy can be used for unstable proximal humeral fractures with two or three fragments, proximal spiral fractures and epiphyseal fractures with comminution, while it is contraindicated for complex intra-articular fractures, head splits and in young patients.²⁵

ARIF, in this case, involves incision and subsequent repair of the supraspinatus tendon but causes less peri-operative and post-operative morbidity with less soft-tissue trauma, reduced bleeding, a lower rate of infection and humeral head osteonecrosis. It also allows the treatment of associated intra-articular lesions, facilitating a fast recovery.²⁵

Elbow joint

Radial head fractures

ORIF is the 'gold standard' for Mason-Hotchkiss type II fractures of the radial head. New indications for ARIF have been recently proposed for radial head fractures and capitulum humeri fractures.²⁶

In a recent paper, Van Tongel et al²⁷ proposed elbow arthroscopy in the treatment of radial head fracture types II, III and IV, in children with radial neck fractures, for coronoid fractures, for lateral condyle fractures and for capitulum fractures.

ARIF with screws was described recently for Mason-Hotchkiss type II fractures²⁸ with good results: ROM, stability and strength were restored in all patients with no complications and only three cases of very mild osteoarthritis. Other advantages when compared with ORIF are the diagnosis of associated pathologies and, in selected cases, the possibility of treating the fracture using only anatomical reduction with probes or palpators. Michels, Pouliart and Handelberg²⁸ adopted ARIF with screws for radial head fractures, advocating great advantages such as the stab-like incisions, with no development of complications and excellent outcomes at five-and-a-half years of follow-up.

Delayed excision of the radial head is actually indicated for highly comminuted fractures²⁹ in low demand patients with recurrent pain having a significant reduction of ROM. Menth-Chiari, Ruch and Poehling³⁰ and McLaughlin³¹ proposed their arthroscopic excision techniques with good results on a very selected cohort. Surgical time was increased but authors concluded that arthroscopy allows an important reduction in the soft-tissue damage, translating into a better recovery, most of all in terms of higher ROM, when compared with open results.

Coronoid fractures

Adams, Merten and Steinmann³² arthroscopically reduced selected coronoid fractures and then synthesised them with a cannulated screw. Surgery is usually indicated if

there is a displacement >50%, as in a type III fracture according to Regan-Morrey's classification, and if the joint is unstable;³² however, a very careful examination must be performed, as it was demonstrated that type I and type II fractures always have some sort of ligament injury.³³ Anatomical reduction of a coronoid fracture is essential to restore stability, even in complex fracture patterns.

In those conditions ORIF presents several negative aspects, such as the opening and detachment of the joint capsule, difficulties in reduction and therefore the potential to disrupt vascularisation of fragments and an insufficient restoration of the anatomy, resulting in instability. A case series was presented by Hausman et al³³ proposing ARIF as an alternative approach. Advantages were the minimal dissection with little soft-tissue disruption and almost perfect anatomical reconstruction, decreasing the risk of heterotopic ossification and arthrofibrosis. A good outcome with stability restoration resulted in all cases and there was also the potential to treat very small fragments with debridement and capsular repair. Indications for ARIF as treatment for coronoid fractures was for types I, II and III. ARIF with screws is usually indicated for an isolated coronoid fracture, while debridement is the usual chosen option for very small fragments.³² It is the authors' opinion that more precautions should be observed in treating special patients such as children and adolescents.

Humeral condyle fractures

ARIF was proposed for capitulum humeri fractures and for condylar fractures in the paediatric population. Usually, a closed reduction with pin fixation is proposed for lateral condyle fractures of the humerus as ORIF carries a high risk of complications.³⁴ Perez Carro, Golano and Vega³⁴ performed ARIF with Kirschner (K-) wires in a fracture of the lateral humeral condyle in an 11-year-old patient, achieving full and symmetrical ROM, complete pain relief and no complications.

One of the biggest advantages offered by ARIF in these conditions is the potential for diagnosing associated lesions, as for the other anatomical locations; however, great care should be used in treating this particular population.

Wrist joint

Distal radial fractures

ARIF for distal radial fractures appears complicated, but recent papers in its favour have been published,^{35,36} even for open fractures.

Varitidimis et al³⁶ compared the outcome of ARIF *versus* fluoroscopy, obtaining better results for the ARIF group in terms of functionality and subjective scores.

Fluoroscopy can produce low-quality images and is not
Downloaded from <http://www.bjopen.com/> at 09/02/2024 02:48:29AM
 via Open Access. This article is distributed under the terms of the Creative Commons Attribution-NonCommercial 4.0 License (<http://www.creativecommons.org/licenses/by-nc/4.0/>) which permits non-commercial use, reproduction and distribution of the work without further permission provided the original work is attributed. <http://www.creativecommons.org/licenses/by-nc/4.0/>

practical in the presence of severe comminution. On the other hand, arthroscopy allows for the removal of any small fragments or loose bodies not visible with fluoroscopy. Moreover, Abe, Yoshida and Tominaga³⁵ found fluoroscopy much less useful during reduction when compared with arthroscopy, reporting a dissociation of about 35% between the two systems.

ARIF facilitates joint debridement, gap correction and blood clot evacuation,³⁷ and allows treatment of associated lesions; ligamentous injuries were found in 68% to 98% of cases, cartilage injuries in 32% and the mean associated lesion incidence was stated to be around 21%.³⁸

Del Pinal et al³⁷ applied the ‘dry technique’³⁹ for complex distal radial fractures with associated comminution, after a mini-open approach for reduction of diaphyseal-metaphyseal fracture and reduction with plate and screws. In order to create a solid supporting structure stabilising the biggest fragments, the construct can be moved ‘en bloc’ as required and fixed to the diaphysis after correct length, alignment and rotation are obtained. The next step is the arthroscopic reduction of the articular surface using probes and ligamentotaxis and synthesis with definitive hardware. The technique mentioned above³⁹ offers new advantages, such as the abolition of compartmental syndrome risk, larger portals that will not compromise visualisation and the potential for immediate surgery without any delay. The results achieved were good, with mobilisation starting after only 48 h, a ROM recovery in the range of 77% to 90%, strength recovery of 95%, return to previous levels of activity in all patients, and only a gap equal to or less than 1 mm.³⁷ A similar technique is called ‘PART’.³⁵ It involves a first step of reduction by direct manipulation, followed by plate preset, the vertical suspension of the wrist to allow a three-portal arthroscopy for anatomical reduction of unreduced fragments, and the treatment of associated cartilage and soft-tissue injuries with the final securing

of the locking plate. This last technique demonstrated that ARIF could be used in any case, resolving traction problems when a volar plate is needed. Similar results appear impossible to obtain with fluoroscopy assistance only.

ARIF appears to be superior to ORIF, and is indicated in young adults, middle-aged and active patients, even more if there are clinical suspicions of soft-tissue injuries;⁴⁰ it is contraindicated for compartment syndrome, exposed fractures and unreducible dislocation.⁴¹ The correct timing to perform ARIF is 48 h after the trauma, but before seven days.⁴²

A schematic summary is provided in Tables 1-3.

Limits and disadvantages

Although promising, ARIF approaches present several limitations. First of all, fracture care by arthroscopy demands a high degree of technical skill and has a prolonged and steep learning curve; it is currently reserved to a limited number of expert arthroscopists, and requires additional

Table 1. Schematic summary of ARIF applications for the superior shoulder, describing the joint, site of fracture, type of fracture, management of the fracture and the hardware used in literature

Joint	Site	Type	ARIF	Hardware
Shoulder	Glenoid surface	Displaced Bony Bankart	Fixation Double pulley	Cannulated screws ⁸ Pins/K-Wires ¹⁰ Suture ^{9,10,13} Cannulated screws ⁸ Suture ¹⁴
			Reverse remplissage	Screws ¹⁸ EndoButton+screw ¹⁶ TightRope ^{17,20} Suture ¹⁹
	Glenoid rim	Posterior Bony Bankart	Fixation	
	Distal clavicle	Neer 2		

ARIF, arthroscopic-assisted reduction and internal-fixation; K-wire, Kirschner wire

Table 2. Schematic summary of ARIF applications for the inferior shoulder

Joint	Site	Type	ARIF	Hardware
Shoulder	Humeral GT	Displaced	Single/dual-row Suture bridge Fixation	Suture ²² Suture ²² Cannulated screws ²²
			Fixation	Suture+cannulated screws ²³ Cannulated screws ²⁵ Cannulated screws ²⁵
	Humeral GT+LT	Displaced	Fixation	Cannulated screws ²⁵ Cannulated screws ²⁵
			Proximal humeral	Codman 2-3 frags Spiroid
		Epiphyseal comminuted	Fixation	Cannulated screws ²⁵

ARIF, arthroscopic-assisted reduction and internal-fixation; GT, great humeral tuberosity; LT, lesser humeral tuberosity; Frags, fragments.

Table 3. Schematic summary of ARIF applications for the elbow and wrist

	Radial head	Mason-Hotchkiss 2-3-4	Reduction	No hardware ²⁸
Elbow		Mason-Hotchkiss 2-3-4	Fixation	Cannulated screws ²⁸ No hardware ^{30,31} Cannulated screws ²⁷
		Radial neck	Excision Fixation	Screws ^{32,33} No hardware ³² Pin ³⁴ K-Wire ³⁴
	Coronoid	Regan-Morrey 1-2-3	Fixation Debridement	Plate+cannulated screws ^{35,37} K-Wires ⁴⁰ Cannulated screws ⁴⁰
Wrist/hand	Humeral condyles	Lateral	Fixation	
	Distal radius	Articular+metaphyseal	ORIF+ARIF	
		Articular	Fixation	

ARIF, arthroscopic-assisted reduction internal fixation; ORIF, open reduction internal fixation; K-wire, Kirschner wire

learning processes based on cadaveric labs and simulators, for example.⁴³ Moreover, alternatives for fixation are limited, as a result of the small fragments and the narrow window in which to place the implants.

Conclusions

The ARIF approach has demonstrated several improvements in comparison with classical ORIF approaches. Definitive advantages of ARIF approaches are the direct visualisation of the joint surface and the potential for proper anatomical reduction of the fracture with less morbidity,^{44,45} safer access to difficult joint areas, a stab-like incision instead of a large arthrotomy,⁴⁴ and a proper diagnosis of every associated lesion and its required treatment which can be simultaneous in many cases. There has also been a demonstrable improvement in the objective and subjective outcomes. However, ORIF is supported by stronger evidence, randomised clinical trials and decades of excellent outcomes, making it, still, the ‘gold standard’ when approaching an articular or peri-articular fracture. More studies are needed, with larger populations and mid- and long-term follow-up, in order to properly confirm the superiority of one technique over another and to establish a possible new trend in joint fracture treatment.

AUTHOR INFORMATION

¹Clinical Orthopaedics, Department of Clinical and Molecular Science DISCLIMO, School of Medicine, Università Politecnica delle Marche, Ancona, Italy

²II Orthopaedic Division, Istituto Chirurgico Ortopedico Traumatologico, ICOT, Latina, Italy

Correspondence should be sent to: L. Dei Giudici, Clinical Orthopaedics, Department of Clinical and Molecular Science, School of Medicine, Università Politecnica delle Marche, Via Tronto, 10/A, 60126, Ancona, Italy.
Email: lucadeigiudici@gmail.com

FUNDING

No benefits in any form have been received or will be received from a commercial party related directly or indirectly to the subject of this article.

LICENCE

© 2016 The author(s)

This article is distributed under the terms of the Creative Commons Attribution-NonCommercial 4.0 License (<http://www.creativecommons.org/licenses/by-nc/4.0/>) which permits non-commercial use, reproduction and distribution of the work without further permission provided the original work is attributed.

REFERENCES

1. **Teeny SM, Wiss DA.** Open reduction and internal fixation of tibial plafond fractures. Variables contributing to poor results and complications. *Clin Orthop Relat Res* 1993;292:108–17.

2. **Walsh EF, Akelman E, Fleming BC, DaSilva MF.** Thumb carpometacarpal arthroscopy: a topographic, anatomic study of the thenar portal. *J Hand Surg* 2005;30A:373–9.

3. **Hildebrand KA, Ross DC, Patterson SD, et al.** Dorsal perilunate dislocations and fracture–dislocations: Questionnaire, clinical, and radiographic evaluation. *J Hand Surg Am* 2000;25:1069–79.

4. **Budoff JE.** Treatment of acute lunate and perilunate dislocations. *J Hand Surg Am* 2008;33:1424–1432.

5. **Venkatesh R.** Principles of surgical management of musculoskeletal conditions. *Best Pract Res Clin Rheumatol* 2008;22:483–98.

6. **Bushnell B, Creighton RED, Herring M.** Bony instability of the shoulder. *Arthroscopy* 2008;24:1061–73.

7. **Porcellini G, Paladini P, Campi F, Paganelli M.** Long-term outcome of acute versus chronic bony Bankart lesions managed arthroscopically. *Am J Sports Med* 2007;35:2067–72.

8. **Tauber M, Moursy M, Eppel M, Koller H, Resch H.** Arthroscopic screw fixation of large anterior glenoid fractures. *Knee Surg Sports Traumatol Arthrosc* 2008;16:326–32.

9. **Schandelmaier P, Blauth M, Schneider C, Krettek C.** Fractures of the glenoid treated by operation. A 5- to 23-year follow-up of 22 cases. *J Bone Joint Surg [Br]* 2002;84-B:173–7.

10. **Gigante A, Marinelli M, Verdenelli A, Lupetti E, Greco F.** Arthroscopy-assisted reduction and percutaneous fixation of a multiple glenoid fracture. *Knee Surg Sport Traumatol Arthrosc* 2003;11:112–15.

11. **Gupta AK, McCormick FM, Abrams GD, et al.** Arthroscopic bony Bankart fixation using a modified Sugaya Technique. *Arthroscopy Tech* 2013;2:e251–5.

12. **Marsland D, Ahmed HA.** Arthroscopically assisted fixation of glenoid fractures: a cadaver study to show potential application of percutaneous screw insertion and anatomic risks. *J Shoulder Elbow Surg* 2011;20:481–90.

13. **Zhang J, Chunyan J.** A new “double-pulley” dual-row technique for arthroscopic fixation of bony Bankart lesion. *Knee Surg Sports Traumatol Arthrosc* 2011;19:1558–62.

14. **Martetschläger F, Padalecki JR, Millet PJ.** Modified arthroscopic McLaughlin procedure for treatment of posterior instability of the shoulder with an associated reverse Hill-Sachs lesion. *Knee Surg Sports Traumatol Arthrosc* 2013;21:1642–6.

15. **Postacchini F, Gumina S, De Santis P, Albo F.** Epidemiology of clavicle fractures. *J Shoulder Elbow Surg* 2002;11:452–6.

16. **Takase L, Kono R, Yamamoto L.** Arthroscopic stabilization for Neer type 2 fracture of the distal clavicle fracture. *Arch Orthop Trauma Surg* 2012;132:399–403.

17. **Motta P, Bruno L, Maderni A, Tosco P, Mariotti U.** Acute lateral dislocated clavicular fractures: arthroscopic stabilization with TightRope. *J Shoulder Elbow Surg* 2014;23:e47–e52.

18. **Checchia SL, Doneux PS, Miyazaki AN, Fregonese M, Silva LA.** Treatment of distal clavicle fractures using an arthroscopic technique. *J Shoulder Elbow Surg* 2008;17:395–8.

19. **Nourissat G, Kakuda C, Dumontier C, Sautet A, Doursounian L.** Arthroscopic stabilization of Neer type 2 fracture of the distal part of the clavicle. *Arthroscopy* 2007;23:674.e1–e4.

20. **Pujol N, Desmoineaux P, Boisrenoult P, Beaufile P.** Arthroscopic treatment of comminuted distal clavicle fractures (Latarjet Fractures) using 2 double-button devices. *Arthroscopy Tech* 2013;2:e61–3.

21. **Gruson KI, Ruchelsman DE, Tejwani NC.** Isolated tuberosity fractures of the proximal humerus: current concepts. *Injury* 2008;39:284–98.

22. **Park SE, Ji JH, Shafi M, et al.** Arthroscopic management of occult greater tuberosity fracture of the shoulder. *Eur J Orthop Surg Traumatol* 2014;24:475-82.
23. **Pauly S, Herrman S, Perka C, Greiner S.** Arthroscopic refixation of a combined fracture of the greater and lesser tuberosity of the proximal humerus. *Knee Surg Sports Traumatol Arthrosc* 2013;21:1171-5.
24. **Kim KC, Rhee KJ, Shin HD, Kim YM.** Arthroscopic fixation for displaced greater tuberosity fracture using the suture-bridge technique. *Arthroscopy* 2008;24:120.e1-3.
25. **Lill H, Katthagen C, Hertel A, Gille J, Voigt C.** All-arthroscopic intramedullary nailing of 2- and 3-part proximal humeral fractures: a new arthroscopic technique and preliminary results. *Arch Orthop Trauma Surg* 2012;132:641-7.
26. **Hsu JW, Gould JL, Fonseca-Sabune H, Hausman MH.** The emerging role of elbow arthroscopy in chronic use injuries and fracture care. *Hand Clin* 2009;25:305-21.
27. **Van Tongel A, Macdonald P, Van Riet R, Dubberley J.** Elbow arthroscopy in acute injuries. *Knee Surg Sports Traumatol Arthrosc* 2012;20:2542-8.
28. **Michels F, Pouliart N, Handelberg F.** Arthroscopic management of Mason type 2 radial head fractures. *Knee Surg Sports Traumatol Arthrosc* 2007;15:1244-50.
29. **Louriat P, Moreau PE, Dallaudiere B, et al.** Outcome of arthroscopic treatment for displaced lateral clavicle fractures using a double button device. *Knee Surg Sports Traumatol Arthrosc* 2015;23:1429-33.
30. **Menth-Chiari WA, Ruch DS, Poehling GG.** Arthroscopic excision of the radial head: clinical outcome in 12 patients with post-traumatic arthritis after fracture of the radial head or rheumatoid arthritis. *Arthroscopy* 2001;17:918-23.
31. **McLaughlin RE 2nd, Savoie FH 3rd, Field LD, Ramsey JR.** Arthroscopic treatment of the arthritic elbow due to primary radiocapitellar arthritis. *Arthroscopy* 2006;22:63-9.
32. **Adams JE, Merten SM, Steinmann SP.** Arthroscopic-assisted treatment of coronoid fractures. *Arthroscopy* 2007;23:1060-5.
33. **Hausmann MR, Raymond AK, Qureshi S, Goldstein R, Parsons BO.** Arthroscopically assisted coronoid fracture fixation. *Clin Orthop Relat Res* 2008;466:3147-52.
34. **Perez Carro L, Golano P, Vega J.** Arthroscopic-assisted reduction and percutaneous external fixation of lateral condyle fractures of the humerus. *Arthroscopy* 2007;23:1131.e1-4.
35. **Abe Y, Yoshida K, Tominaga Y.** Less invasive surgery with wrist arthroscopy for distal radius fracture. *J Orthop Sci* 2013;18:398-404.
36. **Varitimidis SE, Basdekis GK, Dailiana ZH, et al.** Treatment of intra-articular fractures of the distal radius: fluoroscopic or arthroscopic reduction? *J Bone Joint Surg [Br]* 2008;90-B:778-85.
37. **Del Pinal F, Klausmeyer M, Morelada E, de Piero G, Ruas JS.** Arthroscopic reduction of comminuted intra-articular distal radius fractures with diaphyseal-metaphyseal comminution. *J Hand Surg Am* 2014;39:835-43.
38. **Forward DP, Lindau TR, Melsom DS.** Intercarpal ligament injuries associated with fractures of the distal part of the radius. *J Bone Joint Surg [Am]* 2007;89-A:2334-40.
39. **Del Piñal F, García-Bernal FJ, Pisani D, et al.** Dry arthroscopy of the wrist: surgical technique. *J Hand Surg [Am]* 2007;32:119-23.
40. **Dantuliri PK, Gillon T.** Current treatment of distal radius fractures: arthroscopic assisted fracture reduction of distal radius fractures. *Oper Tech Orthop* 2009;19:88-95.
41. **Lutsky K, Boyer MI, Steffen JA, Goldfarb CA.** Arthroscopic assessment of intraarticular fractures after open reduction and internal fixation from a volar approach. *J Hand Surg Am* 2008;33:476-84.
42. **Abboudi J, Culp RW.** Treating fractures of the distal radius with arthroscopic assistance. *Orthop Clin North Am* 2001;32:307-15.
43. **Howells NR, Gill HS, Carr AJ, Price AJ, Rees JL.** Transferring simulated arthroscopic skills to the operating theatre: a randomised blinded study. *J Bone Joint Surg [Br]* 2008;90-B:494-9.
44. **Gill TJ, Moezzi DM, Oates KM, Sterett WI.** Arthroscopic reduction and internal fixation of tibial plateau fractures in skiing. *Clin Orthop* 2001;383:243-9.
45. **Atesok K, Doral MN, Whipple T, et al.** Arthroscopy-assisted fracture fixation. *Knee Surg Sports Traumatol Arthrosc* 2011;19:320-9.