



Thoracolumbar fractures without neurological impairment: a review of diagnosis and treatment

G. Vilà-Canet¹
 A. García de Frutos¹
 A. Covaro¹
 M.T. Ubierna¹
 E. Caceres^{1,2}

- An appropriate protocol and unified management of thoracolumbar fractures without neurological impairment has not been well defined.
- This review attempts to elucidate some controversies regarding diagnostic tools, the ability to define the most appropriate treatment of classification systems and the evidence for conservative and surgical methods based on the recent literature.

Keywords: burst fracture; neurologically intact injuries; classification; conservative treatment; surgical treatment

Cite this article: Vilà-Canet G, García de Frutos A, Covaro A, Ubierna MT, Caceres E. Thoracolumbar fractures without neurological impairment: a review of diagnosis and treatment. *EFORT Open Rev* 2016;1:332-338. DOI: 10.1302/2058-5241.1.000029

Introduction

The incidence of thoracolumbar spinal injuries in the United States has been increasing in recent years, especially as a result of motor vehicle crashes.¹ The same trend has been observed with increasing incidence between 2001 and 2007 in China. Motor vehicle accidents are the leading cause of spinal trauma followed by falls from a height. In a large Chinese series by Liu et al² which included 82 720 patients with spinal trauma, it has been demonstrated that the lumbar spine is the area most frequently involved (56%), followed by thoracic spine (23.7%), cervical spine (17.7%) and sacrococcygeal spine (2.3%).

In 2010, a Swedish group published an epidemiological study of thoracolumbar fractures between 1997 and

2001 which were registered in Sweden. They described an incidence of 13 per 100 000 inhabitants in patients younger than 60 years, mainly as a result of traffic accidents and falls from a height.³ Due to improved traffic safety standards and health care resources, mortality from this type of injury has decreased, but not the number of injured patients needing treatment.⁴ We therefore think it is necessary to work out the ideal management of thoracolumbar fractures, focussing on patients without neurological impairment.

Diagnostic imaging

Several imaging tests are available to diagnose spinal fracture in injured patients.

Plain radiographs and CT scans are usually enough to evaluate stable lesions such as compression fractures or mild burst fractures. There is no doubt that CT scanning gives us very useful information about bony elements, and is usually performed routinely in patients with multiple injuries.⁵ Non-reconstructed, computerised tomographic scans of the abdomen and pelvis have shown good reliability in detecting thoracolumbar spinal injuries, only requiring reconstruction in cases where some abnormality is found and further information is needed.⁶ However, significant soft-tissue disruptions can be missed when CT scanning or plain radiographs are used alone, and we can therefore miss important information which affects treatment decisions.

Today, there is controversy regarding when to perform an MRI scan and the value of the findings at the moment of therapeutic decision. In 2013 Winkelhofer et al⁷ analysed how the use of MRI could change the classification degree of a fracture when compared to a CT scan study alone. They found the AO classification changed in 31% of patients when MRI was added, the thoracolumbar injury classification and severity score (TLICS) changed in 33% of cases and the indication for surgery increased in 24% when both CT scan and MRI were performed, when compared with CT scan use alone. Their conclusion was that MRI considerably improved the detection of fractures and soft-tissue injuries in comparison with CT alone. Similar results were published by Pizones et al⁸

MRI modified the initial diagnosis in 40% of the patients, and therapeutic management in 16% of cases. The authors concluded that MRI was important both for the classification of thoracolumbar fractures and the decision on the most appropriate treatment. On the other hand, another study compared the intra-operative findings with MRI results, concluding that sometimes the MRI can lead to over-diagnosis and over-treatment of stable lesions as MRI has nearly 100% sensitivity but low specificity.⁹ In line with these results, the van Middendorp group¹⁰ tried to judge the role of posterior ligamentous complex injuries in the management of spinal fractures. They concluded that MRI leads to an over-estimation of the number of posterior ligamentous complex injuries, and that there is a lack of clinical evidence of prognostic value for these types of injuries.

Some authors attempted to find the relationship between posterior ligamentous complex (PLC) injury and radiograph parameters, with contradictory results. Hiyama et al¹¹ found an association between a local kyphosis of greater than 20° and an increased supraspinous distance with a PLC injury, but not so with vertebral body translation, loss of vertebral body height or canal compromise.

These results contrast with the ones published some years before by Radcliff et al,¹² who concluded that neither loss of vertebral body height nor local kyphosis were predictive of PLC rupture.

In some cases, there is a high suspicion of PLC injury, but the MRI is not available or is contraindicated. In those cases, an ultrasound can be used as described in a 2013 meta-analysis by Gabriel et al,¹³ finding high levels of accuracy using ultrasound for diagnosing PLC injuries in patients with flexion distraction, compression or burst fractures.

Further studies are needed to decide the value of some pathological findings, especially with reference to PLC injuries detected by MRI.

Classification

Many classification systems have been proposed to assist spinal surgeons in the treatment and decision-making for thoracic and lumbar spine injuries. There has been a lack of consensus concerning the optimal classification system. It is well-known that a good classification system - apart from being reliable and easy to reproduce - should assist in assessing instability and address treatment recommendations as well as future clinical consequences. The most commonly-used classification systems have been the Denis¹⁴ and AO-Magerl.¹⁵

The Denis classification introduced the concept of the three columns of the spine. Spinal injuries were classified in four different categories: compression fractures, burst fractures, 'seat-belt' type injuries and fracture-dislocations.

In the AO-Magerl classification, categories were established according to the injury mechanism. The three main categories include:

- Type A: Vertebral body compression injuries. No disruption of the posterior elements.
- Type B: Injuries with transverse disruption and elongation of the posterior and/or anterior elements in distraction.
- Type C: Injuries secondary to rotation or translation.

Once one of these three patterns has been chosen, the fracture is reclassified with an increasing injury severity of between 1 and 3 in sub-groups of more than 50 sub-types. In 2005, Wood et al¹⁶ evaluated both the Denis and AO systems and found that they both had only moderate reliability and repeatability.

In 1994 - the same year as the development of the AO-Magerl classification - the 'load-sharing classification' was also described by McCormack, Karaikovic and Gaines.¹⁷ The load-sharing classification grades the extent of vertebral body comminution (sagittal plane), the degree of fracture displacement (axial plane) and the amount of correction of kyphotic deformity. It can help to predict when an anterior reconstruction with a strut graft will be required. Fractures with mild comminution, scoring six or fewer points can be successfully repaired from the posterior approach while severely comminuted fractures scoring seven or more must be repaired by an anterior approach with vertebrectomy and strut grafting. This classification has been validated both clinically and biomechanically.¹⁸⁻²¹

Some authors suggest using both the AO-Magerl and load-sharing classifications in combination for a more accurate selection of treatment, surgical approach and length of instrumentation.²²

In 2005, in order to overcome the limitations of the previous classification systems and with an attempt to develop a grading system with prognostic significance, Vaccaro et al²³ published a new TLICS system based on three domains: injury morphology, integrity of the PLC and neurological status (Table 1). With a score of 3 or less, non-operative management is recommended. Five or more points indicate the need for surgical treatment. A score of 4 does not indicate an ideal treatment and the decision is left to the treating physician.

This classification has been validated and has shown good intra- and inter-observer²⁴⁻²⁶ reliability, and its usage has spread worldwide. However some criticisms of the TLICS classification have also been published. Mattei et al²⁷ highlighted the limitations of the TLICS classification, particularly for comminuted burst fractures with no neurological impairment. This type of fracture can have a TLICS score of 2 points, indicating non-operative treatment.

Table 1. Thoracolumbar injury classification and severity (TLICS) scale

Morphology of injury	Compression	1
	Burst	2
	Translation	3
	Distraction	4
PLC integrity	Intact	0
	Suspected	2
	Injured	3
Neurological status	Intact	0
	Nerve injury	2
	Complete cord lesion	2
	Incomplete cord lesion	3
	Cauda equina	3

PLC, posterior ligamentous complex

They described one case of progressive kyphotic deformity produced following conservative treatment of a comminuted burst fracture. In the authors' opinion there is a sub-group of fractures which require special consideration — that TLICS disregards — to avoid greater problems in the future. This opinion stands in line with a recent article published by Dodwad et al²⁸ where use of the TLICS system is recommended in conjunction with clinical judgement. Joaquim et al²⁹ also highlighted inconsistencies in the treatment recommendations of thoracolumbar burst fractures when TLICS is used.

To address these limitations, Vaccaro et al together with AOSpine recently published a new classification, the AOSpine thoracolumbar spine injury classification system,³⁰ a combination of AO/Magerl system and TLICS system. This new classification consists of a morphological classification of the fracture, a grading system for neurological status and a description of relevant patient-specific modifiers. A surgical algorithm for the treatment of thoracolumbar trauma has also been proposed by the same group.^{31,32}

Recent studies are proving the reliability of this new classification,^{33,34} and further work should evaluate whether this classification improves the making of clinical decisions.

Conservative treatment: indications and options

Conservative treatment is proposed in stable injuries, including simple compression or stable burst fractures with no significant posterior osteoligamentous disruption or neurological complications;³⁵ this means a TLICS classification of 3 points or less.

Controversy exists regarding the most appropriate conservative option. There are a wide variety of immobilisation devices and protocols. Some authors recommend a spinal orthosis with early ambulation for 6-12 weeks³⁶ while others suggest bed rest initially, reduction of the fracture with axial traction and a hyperextension body cast.²¹ No individual method or protocol has shown superiority over another.³⁷

In recent years, the basis for the treatment of stable fractures has evolved. Recent articles have shown a lack of benefit to brace usage in patients with stable thoracolumbar fractures when compared with no bracing at all.³⁸

A 2014 systematic review³⁹ which included two randomised controlled trials compared the results of thoracolumbar burst fractures without neurological impairment. The fractures were treated conservatively, with those randomly assigned to wearing (or not wearing) an orthosis. No benefit was found in relation to orthosis wear. Subsequent studies also support these results.⁴⁰

Regardless of the conservative option chosen, close outpatient supervision is essential and in cases of increasing kyphosis (more than 10° compared to the discharge radiograph) on control radiographs or increasing pain, surgical treatment should be considered.⁴¹

Surgical treatment: indication and options

Surgical treatment is proposed when patients have unstable burst fractures (PLC complex injury), burst fractures with neurological deficit or distraction/rotational injuries with or without neurological injury. Surgery is frequently indicated with a TLICS classification of 5 points or above.⁴²

As a general rule, patients with PLC injuries (unstable burst fractures, flexion/distraction injuries and fracture-dislocations) require posterior instrumentation and fusion.⁴² An anterior approach can also be considered if we use the McCormack classification system¹⁷ and a result of seven or more points is obtained.

Kanna, Shetty and Rajasekaran⁴³ recently published a series of cases contradicting the need for anterior support in fractures with a high McCormack classification. They achieved good results at two years' follow-up, performing only posterior fixation including instrumentation of the fractured vertebra when fractures with severe anterior comminution were treated.

A systematic review of operative management of thoracolumbar burst fractures⁴⁴ including 23 initial level studies, analysed the results on performing either short or long segment pedicle screw fixation, posterior, anterior or combined approaches and percutaneous techniques. They concluded that there is good evidence to support posterior non-fusion and percutaneous techniques, regardless of short or long pedicle instrumentation. Furthermore, posterior approaches are associated with lower rates of complication than anterior or combined approaches.

Flexion-distraction injuries are usually treated with long segment pedicle instrumentation using a posterior approach, with similar good results when open surgery is compared to a minimally-invasive approach.^{45,46}

Fracture-dislocation injuries are often the result of very high-energy trauma and are the fracture type most often associated with neurological damage. Both bony columns

and ligamentous structures are torn. Realignment and fixation are best accomplished through posterior positioning, reduction, multi-level instrumentation and fusion.³⁵ Some cases need a second-stage anterior approach.

Hao et al⁴⁷ recently published an RCT comparing two methods to treat fracture-dislocation injuries: combined postero-anterior fusion *versus* transforaminal interbody fusion. They found similar good results using both techniques, but they recommend the transforaminal approach in order to avoid the complications related to a combined anterior approach.

Should I operate or not - what is the evidence?

Despite the recommendations based on classifications, one of the most controversial aspects is still to decide if it is better to operate or not on these types of fractures.

In 2012, Gnanenthiran, Adie and Harris⁴⁸ published a meta-analysis comparing non-operative *versus* operative treatment for thoracolumbar burst fractures without neurological injury, including four prospective controlled clinical trials, in order to establish the best evidence. They concluded that there was insufficient evidence to prove that operative management is superior to non-operative treatment. Surgery can improve the degree of kyphosis, but this fact does not seem to be related to better clinical results.

In 2013 a Cochrane review on the same topic was also published.⁴⁹ The authors could analyse only two trials that met their inclusion criteria and compared both techniques. Contradictory results were found between the trials, so the authors concluded that there was not enough evidence to support conservative or surgical treatment in neurologically-intact burst fractures.

Recently, Wood et al⁵⁰ published a long-term follow-up study comparing outcomes after surgical, or non-operative, treatment for stable burst fractures. They concluded that a long-term follow-up (16 to 20 years) of those patients with a stable burst fracture who were treated non-operatively reported less pain and better function when compared with those who were treated surgically.

So, despite the fact that controversy still exists, at the present time surgery has not been proven to be better than conservative measures when a long-term follow-up was performed.

Case 1 (see supplementary material) features an example of a level I burst fracture treated conservatively, and Case 2 (see supplementary material) displays the surgical management of a level I burst fracture. Both patients were neurologically intact.

Thoracolumbar fractures in polytrauma

There is controversy regarding the appropriate timing of surgical stabilisation of thoracolumbar spine injuries in severely injured patients. A 2011 systematic review showed that polytrauma patients, especially the most injured ones, may benefit from early surgical stabilisation of spinal injuries (with or without cord damage) in order to decrease hospital and intensive care unit length of stay, days of mechanical ventilation and pulmonary complications.⁵¹

In 2013, another systematic review reported that neurologically-intact patients with thoracolumbar fractures may benefit from immediate early surgery for the same reasons discussed above.⁵²

In 2014, Bliemel et al published the results of the German Trauma Society registry including 8994 patients with spinal fractures.⁵³ They also supported stabilisation at an early stage (< 72h) to decrease complications and hospital length of stay. They recommend making an effort to stabilise patients with unstable spinal fractures as soon as possible.

Percutaneous techniques can reduce peri-operative morbidity such as blood loss and infection rates; such techniques can also reduce operative duration and hospital stay; therefore these techniques can be an option for such polytrauma patients.⁵⁴⁻⁵⁶

Take home messages

- The performance of an MRI is not mandatory in all fractures.
- In stable fractures treated conservatively, the use of orthoses has not shown a benefit greater than the use of no immobilisation at all.
- There is a lack of evidence to support a greater beneficial outcomes from these surgical options when compared with conservative measures.
- If surgery is chosen, posterior approaches are related with fewer complications than anterior or combined approaches, and percutaneous techniques have shown good results, especially in polytrauma patients.

Conclusions

Burst fractures without neurological impairment are common. A classification system does not exist which takes into account all of the variables that may influence the results post-treatment.

Controversy still exists regarding the most suitable treatment for thoracolumbar fractures without neurological impairment. Surgery has not been proven as superior to conservative measures but, in operated cases, posterior approaches and percutaneous techniques are a good option in order to decrease complications.

Case 1

A 49-year-old patient had suffered a paragliding accident. He complained of low back pain and was neurologically intact. Figures 1–4 show the fracture images. According to the TLICS classification, a punctuation of 2 was obtained for each fracture, so they were considered non-surgical lesions. According to the load sharing

classification, a punctuation of 7 was obtained for the level III fracture (suggesting an anterior approach reconstruction) and a punctuation of 6 was obtained for the level V fracture.

We decided to perform a double approach in two stages, in order to give some anterior support in the level III fracture, and an L1-S1 posterolateral arthrodesis. See Figures 5 and 6 for the post-operative radiograph.

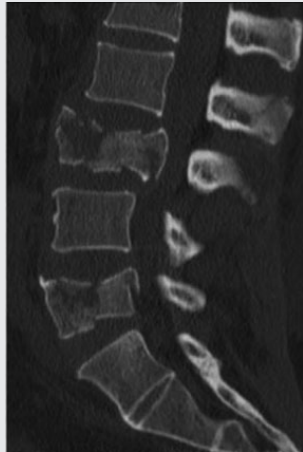


Fig.1 Computerised tomography (CT) sagittal view: level III and level V burst fractures.

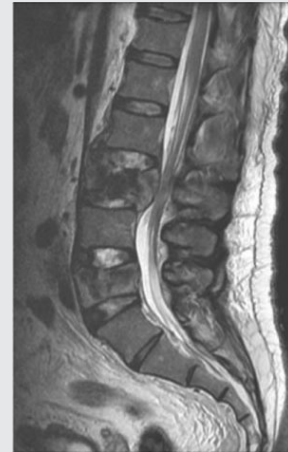

Fig 4 MRI scan sagittal view with intact posterior ligamentous complex.

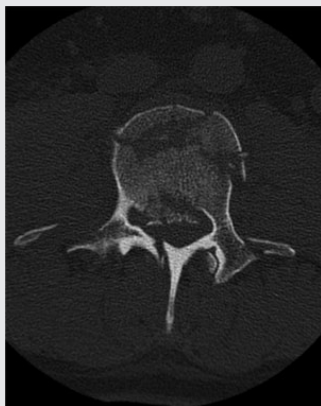

Fig. 2 Level III axial view.

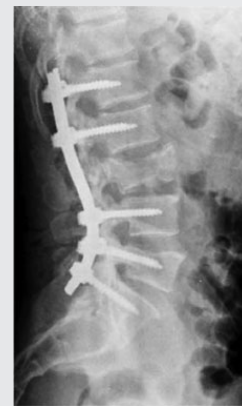

Fig. 5 Standing post-operative radiograph following posterior approach.

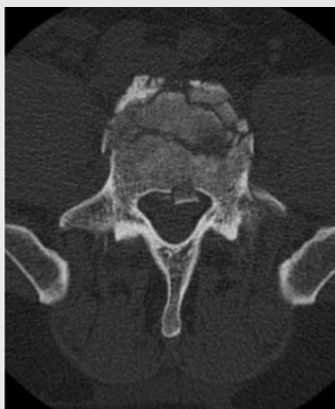


Fig. 3 Level V axial view.

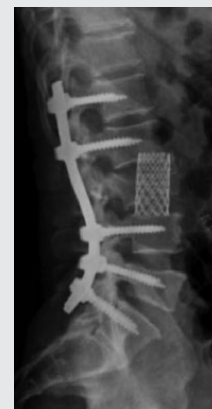

Fig. 6 Standing post-operative radiograph following posterior-anterior approach.

SUPPLEMENTARY MATERIAL

Supplementary material can be found online which demonstrates the evolution of two case examples of burst fractures in neurologically intact patients, one of whom was treated surgically while the other was treated conservatively. See <http://www.eortopenreviews.org/content/1/9>

AUTHOR INFORMATION

¹ICATME, Institut Universitari Quirón-Dexeus, Barcelona, Spain

²Universitat Autònoma de Barcelona, Spain

Correspondence should be sent to: E. Caceres, ICATME, Hospital Universitari Quirón-Dexeus, C/Sabino Arana 5-19, 08028, Barcelona, Spain.

Email: cacerespalou@gmail.com

CONFLICT OF INTEREST

Ana Garcia de Frutos declares separate financial relationships with Stryker, DePuy Synths and Biomet. These relationships have no connection to this paper.

FUNDING

No benefits in any form have been received or will be received from a commercial party related directly or indirectly to the subject of this article.

LICENCE

© 2016 The author(s)

This article is distributed under the terms of the Creative Commons Attribution-NonCommercial 4.0 International (CC BY-NC 4.0) licence (<https://creativecommons.org/licenses/by-nc/4.0/>) which permits non-commercial use, reproduction and distribution of the work without further permission provided the original work is attributed.

REFERENCES

- Doud AN, Weaver AA, Talton JW, et al.** Has the incidence of thoracolumbar spine injuries increased in the United States from 1998 to 2011? *Clin Orthop Relat Res* 2015;473:297-304.
- Liu P, Yao Y, Liu MY, et al.** Spinal trauma in mainland China from 2001 to 2007: an epidemiological study based on a nationwide database. *Spine (Phila Pa 1976)* 2012;37:1310-1315.
- Jansson KA, Blomqvist P, Svedmark P, et al.** Thoracolumbar vertebral fractures in Sweden: an analysis of 13,496 patients admitted to hospital. *Eur J Epidemiol* 2010;25:431-437.
- Oliver M, Inaba K, Tang A, et al.** The changing epidemiology of spinal trauma: a 13-year review from a level I trauma centre. *Injury* 2012;43:1296-1300.
- Looby S, Flanders A.** Spine trauma. *Radiol Clin North [Am]* 2011;49:129-163.
- Smith MW, Reed JD, Facco R, et al.** The reliability of nonreconstructed computerized tomographic scans of the abdomen and pelvis in detecting thoracolumbar spine injuries in blunt trauma patients with altered mental status. *J Bone Joint Surg [Am]* 2009;91-A:2342-2349.
- Winkhofer S, Thekkumthala-Sommer M, Schmidt D, et al.** Magnetic resonance imaging frequently changes classification of acute traumatic thoracolumbar spine injuries. *Skeletal Radiol* 2013;42:779-786.
- Pizones J, Izquierdo E, Alvarez P, et al.** Impact of magnetic resonance imaging on decision making for thoracolumbar traumatic fracture diagnosis and treatment. *Eur Spine J* 2011;20:390-396.
- Rihn JA, Yang N, Fisher C, et al.** Using magnetic resonance imaging to accurately assess injury to the posterior ligamentous complex of the spine: a prospective comparison of the surgeon and radiologist. *J Neurosurg Spine* 2010;12:391-396.
- van Middendorp JJ, Patel AA, Schuetz M, Joaquim AF.** The precision, accuracy and validity of detecting posterior ligamentous complex injuries of the thoracic and lumbar spine: a critical appraisal of the literature. *Eur Spine J* 2013;22:461-474.
- Hiyama A, Watanabe M, Katoh H, et al.** Relationships between posterior ligamentous complex injury and radiographic parameters in patients with thoracolumbar burst fractures. *Injury* 2015;46:392-398.
- Raddcliff K, Su BW, Kepler CK, et al.** Correlation of posterior ligamentous complex injury and neurological injury to loss of vertebral body height, kyphosis, and canal compromise. *Spine (Phila Pa 1976)* 2012;37:1142-1150.
- Gabriel AC, Angel JP, Juan JG, et al.** Diagnostic accuracy of ultrasound for detecting posterior ligamentous complex injuries of the thoracic and lumbar spine: a systematic review and meta-analysis. *J Craniovertebr Junction Spine* 2013;4:25-31.
- Denis F.** The three column spine and its significance in the classification of acute thoracolumbar spinal injuries. *Spine (Phila Pa 1976)* 1983;8:817-831.
- Magerl F, Aebi M, Gertzbein SD, Harms J, Nazarian S.** A comprehensive classification of thoracic and lumbar injuries. *Eur Spine J* 1994;3:184-201.
- Wood KB, Khanna G, Vaccaro AR, et al.** Assessment of two thoracolumbar fracture classification systems as used by multiple surgeons. *J Bone Joint Surg [Am]* 2005;87-A:1423-1429.
- McCormack T, Karakovic E, Gaines RW.** The load sharing classification of spine fractures. *Spine (Phila Pa 1976)* 1994;19:1741-1744.
- Wang XY, Dai LY, Xu HZ, Chi YL.** The load-sharing classification of thoracolumbar fractures: an in vitro biomechanical validation. *Spine (Phila Pa 1976)* 2007;32:1214-1219.
- Parker JW, Lane JR, Karakovic EE, Gaines RW.** Successful short-segment instrumentation and fusion for thoracolumbar spine fractures: a consecutive 41/2-year series. *Spine (Phila Pa 1976)* 2000;25:1157-1170.
- Dai LY, Jin WJ.** Interobserver and intraobserver reliability in the load sharing classification of the assessment of thoracolumbar burst fractures. *Spine (Phila Pa 1976)* 2005;30:354-358.
- Dai LY, Jiang LS, Jiang SD.** Conservative treatment of thoracolumbar burst fractures: a long-term follow-up results with special reference to the load sharing classification. *Spine (Phila Pa 1976)* 2008;33:2536-2544.
- Katonis P, Pasku D, Alpantaki K, et al.** Combination of the AO-Magerl and load-sharing classifications for the management of thoracolumbar burst fractures. *Orthopedics* 2010 (Epub ahead of print) PMID:20349867.
- Vaccaro AR, Lehman RA Jr, Hurlbert RJ, et al.** A new classification of thoracolumbar injuries: the importance of injury morphology, the integrity of the posterior ligamentous complex, and neurologic status. *Spine (Phila Pa 1976)* 2005;30:2325-2333.
- Koh YD, Kim DJ, Koh YW.** Reliability and validity of thoracolumbar injury classification and severity score (TLICS). *Asian Spine J* 2010;4:109-117.
- Lewkonja P, Paolucci EO, Thomas K.** Reliability of the thoracolumbar injury classification and severity score and comparison with the Denis classification for injury to the thoracic and lumbar spine. *Spine (Phila Pa 1976)* 2012;37:2161-2167.
- Whang PG, Vaccaro AR, Poelstra KA, et al.** The influence of fracture mechanism and morphology on the reliability and validity of two novel thoracolumbar injury classification systems. *Spine (Phila Pa 1976)* 2007;32:791-795.
- Mattei TA, Hanovnikian JH, Dinh D.** Progressive kyphotic deformity in comminuted burst fractures treated non-operatively: the Achilles tendon of the Thoracolumbar Injury Classification and Severity Score (TLICS). *Eur Spine J* 2014;23:2255-2262.

- 28. Dodwad SN, Dodwad SJ, Wisneski R, Khan SN.** Retrospective analysis of thoracolumbar junction injuries using the thoracolumbar injury severity and classification score, American Spinal Injury Association class, injury severity score, age, sex, and length of hospitalization. *J Spinal Disord Tech* 2015;28:E410-E416.
- 29. Joaquim AF, Daubs MD, Lawrence BD, et al.** Retrospective evaluation of the validity of the thoracolumbar injury classification system in 458 consecutively treated patients. *Spine J* 2013;13:1760-1765.
- 30. Vaccaro AR, Oner C, Kepler CK, et al; AOSpine Spinal Cord Injury & Trauma Knowledge Forum.** AOSpine thoracolumbar spine injury classification system: fracture description, neurological status, and key modifiers. *Spine (Phila Pa 1976)* 2013;38:2028-2037.
- 31. Vaccaro AR, Schroeder GD, Kepler CK, et al.** The surgical algorithm for the AOSpine thoracolumbar spine injury classification system. *Eur Spine J* 2016;25:1087-1094.
- 32. Schroeder GD, Vaccaro AR, Kepler CK, et al.** Establishing the injury severity of thoracolumbar trauma: confirmation of the hierarchical structure of the AOSpine Thoracolumbar Spine Injury Classification System. *Spine (Phila Pa 1976)* 2015;40:E498-E503.
- 33. Kepler CK, Vaccaro AR, Koerner JD, et al.** Reliability analysis of the AOSpine thoracolumbar spine injury classification system by a worldwide group of naïve spinal surgeons. *Eur Spine J* 2016;25:1082-1086.
- 34. Urrutia J, Zamora T, Yurac R, et al.** An independent interobserver reliability and intraobserver reproducibility evaluation of the new AOSpine thoracolumbar spine injury classification system. *Spine (Phila Pa 1976)* 2015;40:E54-E58.
- 35. Wood KB, Li W, Lebl DR, Ploumis A.** Management of thoracolumbar spine fractures. *Spine J* 2014;14:145-164.
- 36. Cantor JB, Lebowitz NH, Garvey T, Eismont FJ.** Nonoperative management of stable thoracolumbar burst fractures with early ambulation and bracing. *Spine (Phila Pa 1976)* 1993;18:971-976.
- 37. Stadhouders A, Buskens E, Vergroesen DA, et al.** Nonoperative treatment of thoracic and lumbar spine fractures: a prospective randomized study of different treatment options. *J Orthop Trauma* 2009;23:588-594.
- 38. Giele BM, Wiertsema SH, Beelen A, et al.** No evidence for the effectiveness of bracing in patients with thoracolumbar fractures. *Acta Orthop* 2009;80:226-232.
- 39. Alcalá-Cerra G, Paternina-Caicedo AJ, Díaz-Becerra C, Moscote-Salazar LR, Fernandes-Joaquim A.** Orthosis for thoracolumbar burst fractures without neurologic deficit: A systematic review of prospective randomized controlled trials. *J Craniovertebr Junction Spine* 2014;5:25-32.
- 40. Shamji MF, Roffey DM, Young DK, Reindl R, Wai EK.** A pilot evaluation of the role of bracing in stable thoracolumbar burst fractures without neurological deficit. *J Spinal Disord Tech* 2014;27:370-375.
- 41. Mehta JS, Reed MR, McVie JL, Sanderson PL.** Weight-bearing radiographs in thoracolumbar fractures: do they influence management? *Spine (Phila Pa 1976)* 2004;29:564-567.
- 42. Joaquim AF, Patel AA.** Thoracolumbar spine trauma: evaluation and surgical decision-making. *J Craniovertebr Junction Spine* 2013;4:3-9.
- 43. Kanna RM, Shetty AP, Rajasekaran S.** Posterior fixation including the fractured vertebra for severe unstable thoracolumbar fractures. *Spine J* 2015;15:256-264.
- 44. Scheer JK, Bakhsheshian J, Fakurnejad S, et al.** Evidence-based medicine of traumatic thoracolumbar burst fractures: a systematic review of operative management across 20 years. *Global Spine J* 2015;5:73-82.
- 45. Lopez AJ, Scheer JK, Smith ZA, Dahdaleh NS.** Management of llexion distraction injuries to the thoracolumbar spine. *J Clin Neurosci* 2015;22:1853-1856.
- 46. Grossbach AJ, Dahdaleh NS, Abel TJ, et al.** Flexion-distraction injuries of the thoracolumbar spine: open fusion versus percutaneous pedicle screw fixation. *Neurosurg Focus* 2013;35:E2.
- 47. Hao D, Wang W, Duan K, et al.** Two-year follow-up evaluation of surgical treatment for thoracolumbar fracture-dislocation. *Spine (Phila Pa 1976)* 2014;39:E1284-E1290.
- 48. Gnanenthiran SR, Adie S, Harris IA.** Nonoperative versus operative treatment for thoracolumbar burst fractures without neurological deficit. *Clin Orthop Relat Res* 2012;470:567-577.
- 49. Abudou M, Chen X, Kong X, Wu T.** Surgical versus non-surgical treatment of thoracolumbar burst fractures without neurological deficit. *Cochrane Database Syst Rev* 2013;6:CD005079
- 50. Wood KB, Buttermann GR, Phukan R, et al.** Operative compared with nonoperative treatment of a thoracolumbar burst fracture without neurological deficit: a prospective randomized study with follow-up at sixteen to twenty-two years. *J Bone Joint Surg [Am]* 2015;97-A:3-9.
- 51. Carreon LY, Dimar JR.** Early versus late stabilization of spine injuries: a systematic review. *Spine (Phila Pa 1976)* 2011;36:E727-E733.
- 52. Xing D, Chen Y, Ma JX, et al.** A methodological systematic review of early versus late stabilization of thoracolumbar spine fractures. *Eur Spine J* 2013;22:2157-2166.
- 53. Bliemel C, Lefering R, Buecking B, et al.** Early or delayed stabilization in severely injured patients with spinal fractures? Current surgical objectivity according to the Trauma Registry of DGU: treatment of spine injuries in polytrauma patients. *J Trauma Acute Care Surg* 2014;76:366-373.
- 54. Giorgi H, Blondel B, Adetchessi T, et al.** Early percutaneous fixation of spinal thoracolumbar fractures in polytrauma patients. *Orthop Traumatol Surg Res* 2014;100:449-454.
- 55. Phan K, Rao PJ, Mobbs RJ.** Percutaneous versus open pedicle screw fixation for treatment of thoracolumbar fractures: systematic review and meta-analysis of comparative studies. *Clin Neurol Neurosurg* 2015;135:85-92.
- 56. Court C, Vincent C.** Percutaneous fixation of thoracolumbar fractures: current concepts. *Orthop Traumatol Surg Res* 2012;98:900-909.