



## Radial nerve palsy

Marko Bumbasirevic<sup>1,2</sup>

Tomislav Palibrk<sup>1</sup>

Aleksandar Lesic<sup>1,2</sup>

Henry DE Atkinson<sup>3</sup>

- As a result of its proximity to the humeral shaft, as well as its long and tortuous course, the radial nerve is the most frequently injured major nerve in the upper limb, with its close proximity to the bone making it vulnerable when fractures occur.
- Injury is most frequently sustained during humeral fracture and gunshot injuries, but iatrogenic injuries are not unusual following surgical treatment of various other pathologies.
- Treatment is usually non-operative, but surgery is sometimes necessary, using a variety of often imaginative procedures. Because radial nerve injuries are the least debilitating of the upper limb nerve injuries, results are usually satisfactory.
- Conservative treatment certainly has a role, and one of the most important aspects of this treatment is to maintain a full passive range of motion in all the affected joints.
- Surgical treatment is indicated in cases when nerve transection is obvious, as in open injuries or when there is no clinical improvement after a period of conservative treatment. Different techniques are used including direct suture or nerve grafting, vascularised nerve grafts, direct nerve transfer, tendon transfer, functional muscle transfer or the promising, newer treatment of biological therapy.

Cite this article: Bumbasirevic M, Palibrk T, Lesic A, Atkinson HDE. Radial nerve palsy. *EFORT Open Rev* 2016;1:286-294. DOI: 10.1302/2058-5241.1.000028.

**Keywords:** radial nerve injury; radial nerve palsy; posterior interosseous nerve injury; nerve reconstruction; tendon transfer

### Introduction

Injuries to the radial nerve can occur at any point along its anatomical route, and the aetiology is quite varied. As a result of its proximity to the humeral shaft, as well as its long and tortuous course, the radial nerve is the most

frequently injured major nerve in the upper limb. Its close bony proximity makes it vulnerable to fractures of the humeral shaft and around the elbow. Injuries can be divided into high, complete radial nerve injuries and low, posterior interosseous radial nerve injury (PIN injury). Most injuries occur distal to the triceps muscle innervation. Radial nerve injuries are usually diagnosed through physical examination, though electrodiagnostic and radiological studies can help to identify the exact injury location and the degree of damage.

Treatment is often expectant (non-operative), though surgery is also sometimes necessary by a variety of often imaginative procedures. Because radial nerve injuries are the least debilitating of the upper limb nerve injuries, results are usually satisfactory.<sup>1,2</sup>

Nerve injuries can take the form of a neuropraxia, which presents as minor contusions or compression of the peripheral nerve with a temporary interruption in the transmission of electrical impulses. Axonotmesis is a more severe form of nerve injury with damage to the axons themselves and accompanying distal Wallerian degeneration, but maintaining preservation of Schwann cells and an intact endoneurial nerve structure. The most severe form of damage is a neurotmesis, where there is a complete anatomical disruption to nerve continuity. Here there is no possibility of spontaneous nerve recovery, and surgery is always necessary.<sup>3</sup> Nerve recovery is dependent on a variety of factors, the most predictive being age, sex, time of repair, the materials used for repair, the size of the defect and duration of follow-up.<sup>4</sup>

### Anatomy

The radial nerve is the largest nerve in the upper limb. It is a branch of the brachial plexus arising from the posterior cord with fibres originating from the C5, C6, C7, C8 and T1 roots. The radial nerve runs across the latissimus dorsi muscle, deep to the axillary artery. It passes through the triangular interval at the inferior border of the teres major muscle. It then winds around the proximal part of the humerus on its medial side and enters and innervates the triceps muscle between the lateral and medial heads. At that level the nerve diverts into two sensory branches – the posterior cutaneous nerve of the arm and the inferior lateral cutaneous nerve of the arm. It then lies on the spiral groove of the humeral shaft and pierces the lateral

intermuscular septum, entering the anterior compartment between brachialis and brachioradialis, about 12 cm proximal to the lateral epicondyle. It is often a site of neuropraxia after humeral shaft fracture with entrapment between the fracture fragments. Distally it passes anteriorly to the lateral humeral condyle. At the level of the elbow, the radial nerve gives branches to the brachioradialis, extensor carpi radialis longus and anconeus. The extensor carpi radialis brevis can receive innervation from the radial nerve proper or from the posterior interosseous nerve, depending on anatomical variation.<sup>5</sup>

Proximal to the level of the elbow, the nerve divides into superficial and deep branches. The superficial branch is purely sensory. It runs under the brachioradialis muscle at the radial side of the forearm. In the middle third of the forearm the nerve is close and lateral to the radial artery, while more distally it veers away from it. At the level of the distal forearm it emerges under the brachioradialis tendon at around 9 cm proximal to the radial styloid and travels superficially under the skin. At the level of the radial styloid it divides into two or three sensory branches innervating the skin of the proximal two thirds of the lateral three and a half fingers, as well as the dorsum of the hand.<sup>6,7</sup>

The posterior interosseous nerve is the deep branch of the radial nerve. It runs between the two heads of the supinator muscle, innervates it and then enters the forearm and supplies the majority of the forearm and hand extensors. The most proximal part of the supinator muscle forms the arcade of Frohse, a fibrous arc, which is a common site for nerve compression. At the distal end of the supinator muscle the posterior interosseous nerve divides into two branches: the medial (recurrent) branch innervating the extensor carpi ulnaris, the extensor digitorum communis and the extensor digiti quinti; and the lateral (descending) branch innervating the extensor indicis proprius, the extensor pollicis longus, the abductor pollicis longus and the extensor pollicis brevis.<sup>8,9</sup>

## Aetiology

The radial nerve is most frequently injured in association with humeral fractures. Typically these injuries occur at the junction of the middle and distal thirds (Holstein-Lewis fracture). These are usually spiral fractures where the distal fragment displaces proximally and radially. This is the point at which the nerve enters the anterior compartment piercing the intermuscular septum, and where it is least mobile. The nerve can be injured by the fracture itself, during manipulation of the fragments during reduction/surgery or through entrapment by healing callus formation.<sup>10</sup> Fractures of the radial head and neck, and radius/ulna fractures can damage the posterior interosseous nerve.<sup>11,12</sup>

### *Gunshot injuries*

Gunshot injuries of either low or high velocity can cause significant damage to the radial nerve. This type of injury is not uncommon and the outcomes depend largely on whether the nerve is directly transected or is damaged by the shock-wave or blast effect of the projectile.<sup>13,14</sup>

### *Injuries with sharp objects*

Knives and glass, for example, can directly transect the nerve and lead to disability.<sup>15</sup> However, the superficial branches of the radial nerve are the most vulnerable to this type of injury, and often there is no significant permanent damage.

### *Iatrogenic injury*

Peripheral nerve injuries are an unintentional but common complication of upper limb surgery. Any part of the radial nerve and its branches can be affected. The nerve is particularly vulnerable at the mid-shaft of the humerus where it is in direct contact with the periosteum and at the point where it pierces the intermuscular septum. The symptoms only become apparent after the surgery, usually manifesting as sensory loss, wrist drop or a deficit in finger extension in metacarpophalangeal (MCP) joints. The nerve can be damaged by surgical blades, Kirschner wires (K-wires), during limb traction or fracture manipulation, by fixation devices such as plates, screws and intramedullary nails for example, and from poor positioning on the operating table.<sup>16-20</sup>

### *Thermal and crush injuries*

These injuries can present as unusual intraoperative cases of vascular changes from blood pressure cuffs leading to radial nerve palsy.<sup>22</sup> Recent studies performed on cadavers have shown that distal locking screws can damage the radial nerve when introduced from a lateral to medial direction.<sup>23,24</sup>

The posterior interosseous nerve is frequently injured during elbow surgery such as elbow arthroplasty, radial head fracture repair and synovectomy. It also lies near the anterolateral portal, and can be damaged during elbow arthroscopy – a rare complication, but one that arthroscopists should be aware of nonetheless.<sup>25</sup>

The superficial radial nerve is not uncommonly injured after K-wire fixation of the distal radius: up to 20% in some wrist fracture series.<sup>26,27</sup> Superficial branches of the radial nerve can also be injured during shoulder arthroscopy.<sup>28</sup>

### *Intramuscular injections*

These injections can cause direct nerve damage from the needle or injected agent. These injuries mostly occur in the region proximal to the spiral groove of the humerus and can even include the triceps muscle.<sup>29,30</sup> Symptoms are usually immediately apparent following the injection.

### Compression neuropathies

Compression neuropathies are characterised by the location at which the nerve is placed under pressure. One of the well-known entities is ‘Saturday night palsy’, when compression of the radial nerve at the spiral groove of the humerus after prolonged pressure occurs. Compression also can be caused by the fibrous arch of the lateral head of the triceps muscle, within the fibrous arcade of Frohse, at the origin of the extensor carpi radialis brevis, with radial head pathologies such as tumours, by a recurrent radial artery, and by pathological processes along the sensory branch (Wartenberg syndrome). Rare causes of radial nerve affection can be tumours, neuritis, repetitive over-use, systemic and neurological diseases.<sup>31-35</sup>

### Diagnosis

The clinical examination is the fundamental diagnostic tool. All the muscles innervated by the radial nerve can be tested for strength and function, including the triceps, forearm supinator, and wrist and finger extensors. For the upper lesions of radial nerve, loss of elbow extension should be evaluated with gravity eliminated. The examiner should be aware that with digital flexion, some extension of the wrist is possible with tight passive extensors. Digital extension is an area where most errors in diagnosis can occur. Extension of interphalangeal (IP) joints is accomplished by the interossei and lumbrical muscles innervated by the ulnar nerve. With radial nerve injury, only extension in the MCP joints is affected. One can also test the sensation on the dorsum of the hand and lateral three and a half fingers as well as the arm and forearm.

Electromyography and nerve conduction electrodiagnostic studies are helpful when trying to locate anatomically a nerve lesion. One can differentiate between cervical radiculopathies, brachial plexopathies and peripheral nerve lesions. One can also monitor nerve recovery during the period of rehabilitation, especially from four months, when regeneration can be detected.<sup>36</sup>

Even though a nerve injury may be evident following clinical and electrodiagnostic testing, it is frequently unclear whether the nerve has suffered a neuropraxia, axonotmesis or neurotmesis in the early post-operative period. Prompt confirmation of this type of injury is essential,<sup>37-39</sup> as early surgical treatment and repair of an injured nerve can be crucial when neurotmesis is present.

Electroconduction studies should be performed only after Wallerian degeneration has set in, at around four months after nerve injury. One should be aware that with electrodiagnostic testing it is impossible to make a definite prognosis concerning nerve recovery. Conduction studies can predict that the nerve is going to recover only one month before first clinical signs of recovery appear. The

brachioradialis is the first muscle to show the signs of recovery, followed by ECRL and ECRB.

### Diagnostic tools

**Ultrasonography** can precisely visualise the anatomical integrity of the nerve, differentiating between a rupture of the nerve and neuroma formation. It can demonstrate the exact location of the nerve injury and follow the nerve along its anatomical path. It is non-invasive, affordable and has specific advantages over MRI and other diagnostic procedures.<sup>37,40,41</sup>

**Plain radiography** can detect fractures, dislocations, excessive callus formation and tumours as causes of compression.

**MRI** is useful in detecting the location of an injury, co-existing pathologies and neurological diseases when a nerve lesion is suspected.<sup>42,43</sup>

### Treatment

Treatment of radial nerve palsy can be either non-operative or operative.

#### Non-operative treatment

Non-surgical treatment certainly has a role. Many conditions that include radial nerve impairment are transient and can be treated non-operatively. Compression neuropathies can initially be treated with rest, activity modification, non-steroidal anti-inflammatory drugs (NSAIDs), vitamin therapy and a period of immobilisation in a functional splint. Corticosteroid injections with or without local anaesthetic can be administered with caution. One of the most important aspects of this treatment is to maintain a full passive range of motion in all the affected joints through exercise programmes and the use of dynamic splints. The key function attributable to the radial innervated muscle is wrist extension. Power grip is critically dependent on fixation of the wrist in extension.<sup>44</sup>

#### Surgical treatment

Surgical treatment is indicated in cases when nerve transection is obvious, as in open injuries or when there is no clinical improvement after a period of conservative treatment. The nerve can be repaired by direct suturing or nerve grafting. Other reconstructive procedures such as tendon transfers may also become necessary to overcome any permanent nerve dysfunction. Nerve transfers and functional free muscle transfers are currently gaining in popularity.

Surgical reconstruction of the injured nerve is always the best solution following trauma and obvious nerve transection (Figs 1-5).

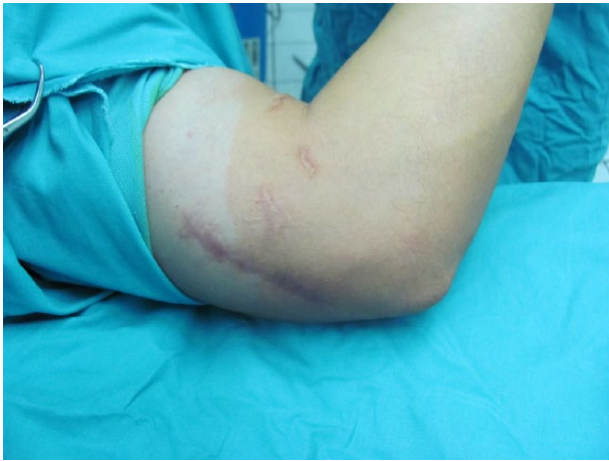


Fig. 1 Pre-operative finding of an old radial nerve injury.

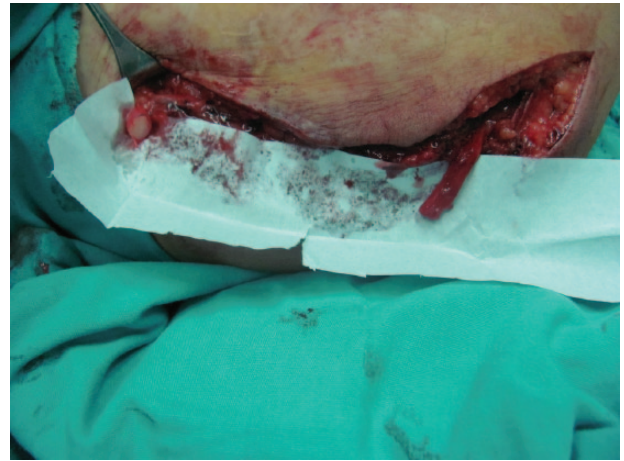

Fig. 3 An 8 cm gap between two ends prepared for reconstruction.

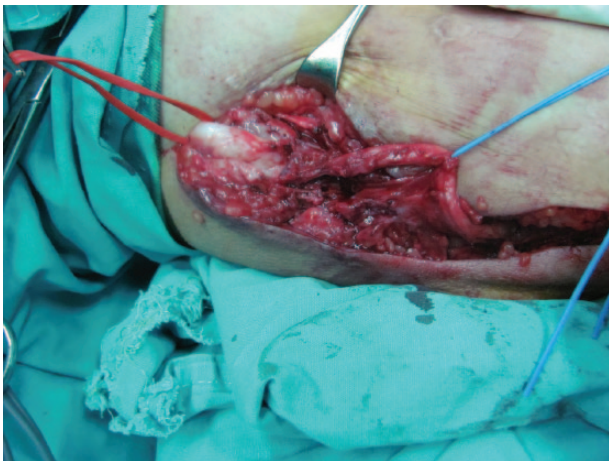


Fig. 2 Intraoperative finding of injured radial nerve.

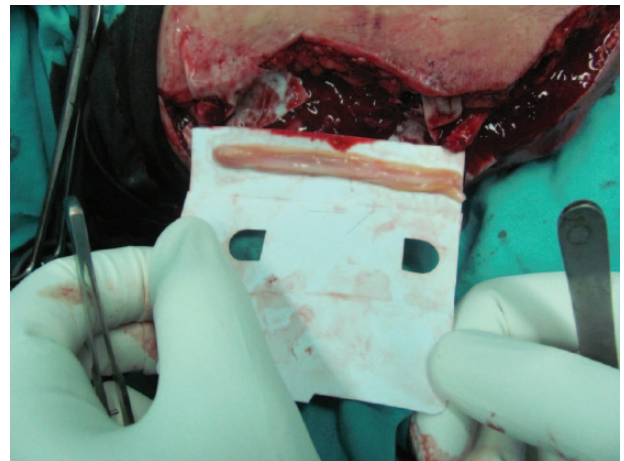


Fig. 4 Four cables of sural nerve glued with fibrin glue.

The functional results after microsurgical reconstruction are mostly satisfactory with low levels of disability. When there is nerve discontinuity, an end-to-end repair is the method of choice. In situations where reconstruction of the peripheral nerve injury is difficult due to segmental defects or 'gaps' in the nerve, nerve grafting can be helpful. Autogenous nerve grafts are most commonly used. The sural nerve and cutaneous nerve branches of the forearm are usually of good quality, have low donor site morbidity, and can be used for transfers. This usually follows an 'in group' fascicular grafting technique.<sup>45,46</sup> Recovery of radial nerve motor function may be expected if the repair is carried out within 15 months of the injury.<sup>47,48</sup>

Vascularised nerve grafts have better outcomes when compared with nerve grafts without a vascular pedicle, the main benefits being the avoidance of an initial ischaemic period and the ability to transfer larger blocks of nerve tissue.<sup>49,50</sup>

Radial nerve palsy related to humeral shaft fracture occurs in between 2% and 17% of cases. These are usually

closed fractures, and non-operative treatment results in a full recovery within three to 68 months in up to 95% of patients. When these are high-energy open fractures with soft-tissue damage, then early fixation and nerve exploration is recommended.<sup>51-55</sup> Direct nerve transfer also has a role and is one of the primary techniques used in the repair of brachial plexus injuries. This procedure involves the coaptation of the proximal end of a nerve, which is different to the distal denervated recipient nerve. We 'sacrifice' the function of a lesser-valued donor muscle in order to restore the function of the recipient nerve and muscle. There are various reported surgical techniques. Radial nerve function can be restored through the direct nerve transfer of the motor branches of the median nerve in the proximal forearm to the extensor carpi radialis brevis and the posterior interosseous branches of the radial nerve. The branch to the pronator teres muscle can be transferred to the extensor carpi radialis longus branch. The branch to the flexor carpi radialis is used to revive the posterior interosseous nerve. The flexor digitorum superficialis tendon can also

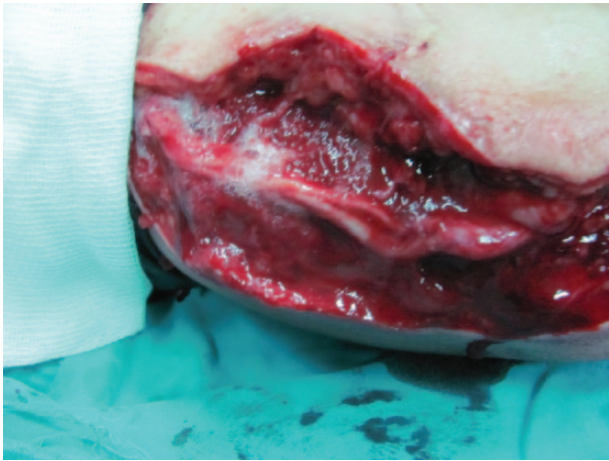


Fig. 5 Complete radial nerve grafting with fibrin glue.

be transferred to the extensor carpi radialis brevis tendon to recreate wrist extension. The success of these procedures is gauged by testing the degree of resultant wrist and finger extension.<sup>56-59</sup>

Tendon transfer is essential in irreparable or long-standing radial nerve palsies in order to restore hand function. Tendon transfer is still the most commonly used technique for motor reconstruction in chronic cases. A waiting period of one year is usually sufficient to see any evidence of nerve regeneration. Following a radial nerve injury, the extrinsic extensor function of the hand and wrist is lost. This results in an inability to extend the fingers and wrist and affects grip strength and finger flexion, and has a large influence on thumb usage. Tendon transfer surgery must restore finger, thumb and wrist function without inflicting other motor deficits on the hand.<sup>60-62</sup>

Knowledge of tendon and nerve anatomy and an understanding of the concept of muscle balance and kinetics are important. Timing of tendon transfers is still controversial. The most accepted approach is to perform tendon transfers after sufficient time has elapsed, to determine that further nerve recovery will not appear, either through surgery or physical therapy. However, some new research suggests that immediate tendon transfer should be performed in cases where there is a gap of more than 4 cm between the nerve ends, when the nerve is in a deep wound, surrounded by excessive scar tissue and when there is significant associated tissue loss.<sup>63</sup>

There are some principles for tendon transfer procedures including good skin coverage, mobile and stable joints, and stable skeletal alignment that must be respected in order to obtain a good functional results. The motor unit must have the right strength (grade 4+ or more on the MRC scale) and amplitude. Used tendons must have the straightest trajectory, avoiding sharp angles and crossing only one joint.

Before embarking on tendon transfer surgery it is important that the joints have achieved good passive mobility in order to achieve optimal function post-tendon transposition. The donor muscles are tested for strength before surgery, and must come from a region unaffected by the pathology.

With over 50 described techniques, the surgeon must choose the most suitable for the individual patient. Most often we use the pronator teres to extensor carpi radialis brevis transfer to restore wrist extension, the flexor carpi radialis for finger extension (Brand technique) and the palmaris longus to extensor pollicis longus (EPL) transfer for thumb extension. The flexor carpi radialis tendon can also be used to restore thumb abduction and extension, where it is transferred to the tendons of the first extensor compartment.

The flexor digitorum superficialis muscles (Boyes technique) are also a useful donor as they provide better sliding function; however, the technique is more demanding and the synergy in strength between metacarpo-phalangeal joint extension and finger flexion can be problematic. We typically use the fourth finger flexor digitorum superficialis to generate extension of the thumb and index finger. This type of transfer allows for simultaneous extension and does not affect the final result.

Flexor carpi ulnaris (FCU) is also an alternative for recreating finger extension; however, it is now seldom used, because wrist stability can be threatened through FCU tendon harvesting. Thumb abduction can also be restored through EPL re-routing, or by tenodesing abductor pollicis longus to brachioradialis.<sup>63-66</sup>

The Merle d'Aubigné procedure is a combined transfer of pronator teres to extensor carpi radialis longus and brevis, the flexor carpi ulnaris to extensor pollicis longus, and the extensor digiti communis and palmaris longus to abductor pollicis longus and extensor pollicis brevis.<sup>67</sup> In some cases with 'high' radial nerve palsy, and when pronator teres, palmaris longus and flexor digitorum superficialis are not available, a technique called the 'double wrist flexor' transfer can be used. Here the flexor carpi ulnaris and flexor carpi radialis are both used to regain extensor function. In these cases wrist flexion is reduced; however, the overall results are good.<sup>68</sup> Post-operatively, a long-arm cast is applied for a period of six weeks. This is followed by physical therapy and muscle-tendon re-education.

#### Functional muscle transfer

In cases of radial nerve palsy when there is no possibility of radial nerve reconstruction or tendon or nerve transfers with a free functional muscle transfer, the loss of elbow or wrist end finger extension can be re-gained.<sup>69</sup> Functional muscle transfer is a sophisticated surgical procedure which requires microsurgical skills. It can be a valuable

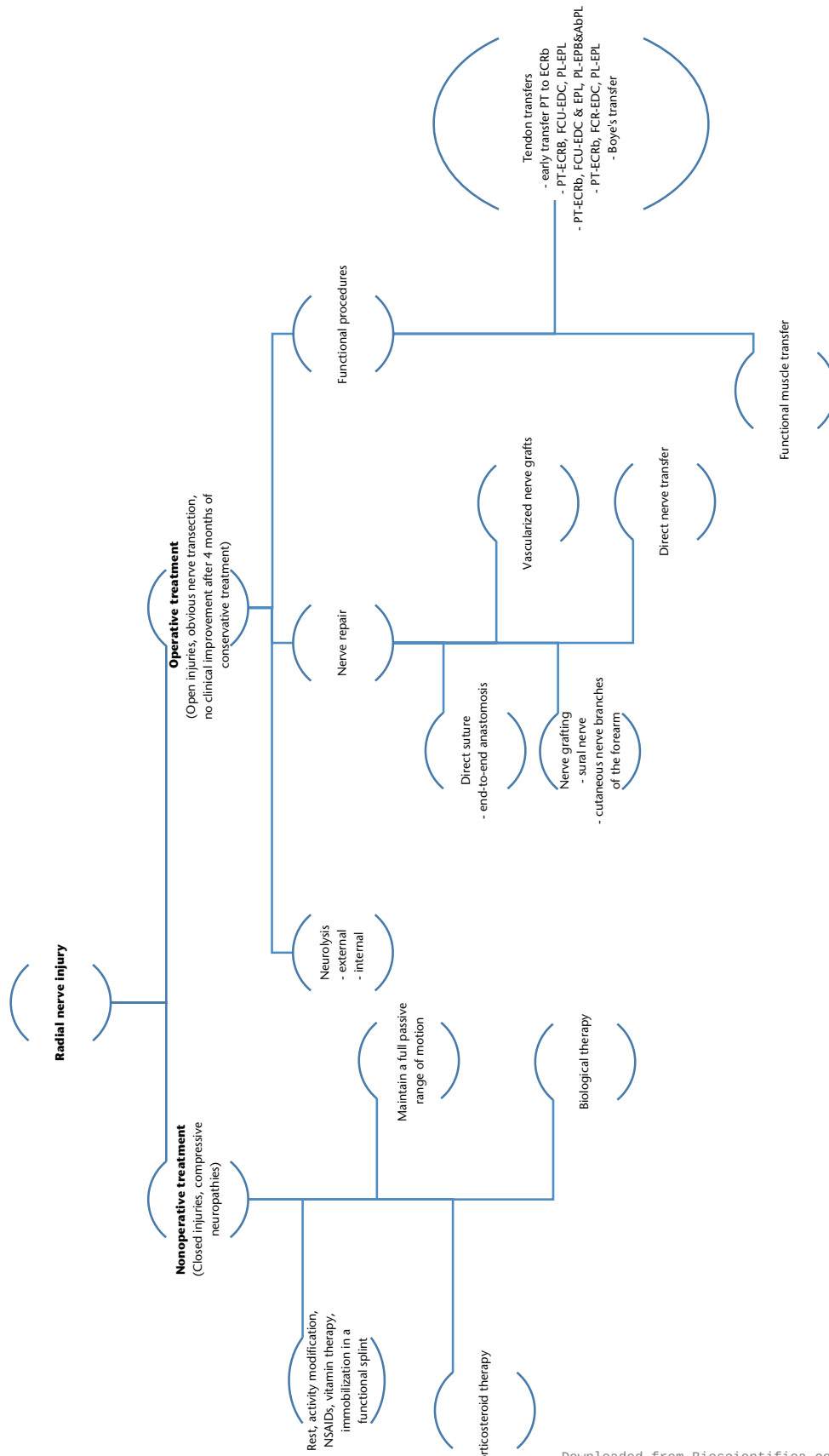


Fig. 6 Radial nerve injury flowchart.

solution in cases when there are no other possibilities, or where the previously described methods of treatment have been unsuccessful. The well-functioning muscle is transferred to the non-functional recipient site and, after reconstruction of the nutrient blood vessels and motor nerve branch, the transplanted muscle can become a well-functioning motor unit. Frequently the gracilis muscle is used as donor, but latissimus dorsi, tensor fasciae lata, rectus femoris, medial gastrocnemius and others can also be used.

Today the spotlight is on biological therapies and nerve regeneration. Research is being conducted with pluripotent stem cells and nerve conduits. Some research has suggested that the use of mesenchymal stem cells can lead to a functional recovery and nerve regeneration when combined with biological scaffolds, with promising developments using human amniotic membranes loaded with human umbilical cord mesenchymal stem cells in radial nerve repair. Tests on the regenerated nerves in primates have yielded good results, and this bodes well because of their similarity to humans.<sup>70-72</sup>

## Conclusion

Radial nerve palsy can result from a variety of aetiologies, and the treatment algorithm is dictated not only by the cause of neuropathy, but also the expected recovery of the nerve. Treatment ranges from non-operative, expectant management to surgical intervention. The breadth of surgical intervention ranges from direct nerve repair to tendon transfer, with a wide variety of options supported in the literature. New frontiers in nerve regeneration with stem cells have yielded preliminarily promising results, and future developments in this field are anticipated.

### AUTHOR INFORMATION

<sup>1</sup>Orthopaedic and Traumatology University Clinic, Clinical Center of Serbia, Serbia

<sup>2</sup>School of Medicine, University of Belgrade, Serbia

<sup>3</sup>Department of Trauma and Orthopaedics, University College, London Medical School, North Middlesex University Hospital, UK

Correspondence should be sent to: Marko Bumbasirevic, Stojana Novakovica 25, 11000 Belgrade, Serbia.

Email: marko.bumbasirevic@gmail.com

### CONFLICT OF INTEREST

None declared.

### FUNDING

No benefits in any form have been received or will be received from a commercial party related directly or indirectly to the subject of this article.

### LICENCE

© 2016 The author(s)

This article is distributed under the terms of the Creative Commons Attribution-NonCommercial 4.0 License (<http://www.creativecommons.org/licenses/by-nc/4.0/>) which permits non-commercial use, reproduction and distribution of the work without further permission provided the original work is attributed.

### REFERENCES

1. Jobe MT, Martiney SF. Peripheral nerve injuries. In: *Campbell's operative orthopaedics*. Twelfth ed. Philadelphia: Elsevier Mosby, 2013:3063-3123.
2. Li Y, Ning G, Wu Q, et al. Review of literature of radial nerve injuries associated with humeral fractures—an integrated management strategy. *PLoS One* 2013;8:e78576.
3. Seddon H. Three types of nerve injury. *Brain* 1943;66:237-288.
4. He B, Zhu Z, Zhu Q, et al. Factors predicting sensory and motor recovery after the repair of upper limb peripheral nerve injuries. *Neural Regen Res* 2014;9:661-672.
5. Abrams RA, Ziets RJ, Lieber RL, Botte MJ. Anatomy of the radial nerve motor branches in the forearm. *J Hand Surg Am* 1997;22:232-237.
6. Robson AJ, See MS, Ellis H. Applied anatomy of the superficial branch of the radial nerve. *Clin Anat* 2008;21:38-45.
7. Ikiz ZA, Uçerler H. Anatomic characteristics and clinical importance of the superficial branch of the radial nerve. *Surg Radiol Anat* 2004;26:453-458.
8. Prasartritha T, Liupolvanish P, Rojanakit A. A study of the posterior interosseous nerve (PIN) and the radial tunnel in 30 Thai cadavers. *J Hand Surg Am* 1993;18:107-112.
9. Sunderamoorthy D, Chaudhury M. An uncommon peripheral nerve injury after penetrating injury of the forearm: the importance of clinical examination. *Emerg Med J* 2003;20:565-566.
10. Holstein A, Lewis GM. Fractures of the humerus with radial-nerve paralysis. *J Bone Joint Surg [Am]* 1963;45-A:1382-1388.
11. Li H, Cai QX, Shen PQ, et al. Posterior interosseous nerve entrapment after Monteggia fracture-dislocation in children. *Chin J Traumatol* 2013;16:131-135.
12. Serrano KD, Rebella GS, Sansone JM, Kim MK. A rare case of posterior interosseous nerve palsy associated with radial head fracture. *J Emerg Med* 2012;43:e115-e117.
13. Guo Y, Chiou-Tan FY. Radial nerve injuries from gunshot wounds and other trauma: comparison of electrodiagnostic findings. *Am J Phys Med Rehabil* 2002;31:207-211.
14. Mirić D, Senohradski K, Starčević B, Djordjević Z. [External fixation war injuries of the proximal humerus]. *Srp Arh Celok Lek* 2004;132:92-95. (In Serbian)
15. Provencher MT, Allen LR, Gladden MJ, Shin AY. The underestimation of a glass injury to the hand. *Am J Orthop (Belle Mead NJ)* 2006;35:91-94.
16. Hassan DM, Johnston GH. Safety of the limited open technique of bone-transfixing threaded-pin placement for external fixation of distal radial fractures: a cadaver study. *Can J Surg* 1999;42:363-365.
17. Steinberg BD, Plancher KD, Idler RS. Percutaneous Kirschner wire fixation through the snuff box: an anatomic study. *J Hand Surg Am* 1995;20:57-62.
18. Carlan D, Pratt J, Patterson JM, et al. The radial nerve in the brachium: an anatomic study in human cadavers. *J Hand Surg Am* 2007;32:1177-1182.
19. Zhang J, Moore AE, Stringer MD. Iatrogenic upper limb nerve injuries: a systematic review. *ANZ J Surg* 2011;81:227-236.

20. **Lim R, Tay SC, Yam A.** Radial nerve injury during double plating of a displaced intercondylar fracture. *J Hand Surg Am* 2012;37:669-672.
21. **Singh VA, Michael RE, Dinh DB, Bloom S, Cooper M.** Posterior interosseous nerve syndrome from thermal injury. *Case Rep Surg* 2014;2014:891393.
22. **Lin CC, Jawan B, de Villa MV, Chen FC, Liu PP.** Blood pressure cuff compression injury of the radial nerve. *J Clin Anesth* 2001;13:306-308.
23. **Noger M, Berli MC, Fasel JH, Hoffmeyer PJ.** The risk of injury to neurovascular structures from distal locking screws of the unreamed humeral nail (UHN): a cadaveric study. *Injury* 2007;38:954-957.
24. **Blyth MJ, Macleod CM, Asante DK, Kinninmonth AW.** Iatrogenic nerve injury with the Russell-Taylor humeral nail. *Injury* 2003;34:227-228.
25. **Gupta A, Sunil Tm.** Complete division of the posterior interosseous nerve after elbow arthroscopy: a case report. *J Shoulder Elbow Surg* 2004;13:566-567.
26. **Singh S, Trikha P, Twyman R.** Superficial radial nerve damage due to Kirschner wiring of the radius. *Injury* 2005;36:330-332.
27. **Ali AM, El-Alfy B, Attia H.** Is there a safe zone to avoid superficial radial nerve injury with Kirschner wire fixation in the treatment of distal radius? A cadaveric study. *J Clin Orthop Trauma* 2014;5:240-244.
28. **Singh VK, Singh PK, Azam A.** Intraoperative positioning related injury of superficial radial nerve after shoulder arthroscopy - a rare iatrogenic injury: a case report. *Cases J* 2008;1:47.
29. **Pandian JD, Bose S, Daniel V, Singh Y, Abraham AP.** Nerve injuries following intramuscular injections: a clinical and neurophysiological study from Northwest India. *J Peripher Nerv Syst* 2006;11:165-171.
30. **Preston DC, Shapiro BE.** Radial neuropathy. In: Preston DC, Shapiro BE. *Electromyography and Neuromuscular Disorders. Clinical Electrophysiologic Correlations*. Third ed. Boston: Butterworth-Heinemann; 1998:291-306.
31. **Kornberg AJ, Pestronk A.** Chronic motor neuropathies: diagnosis, therapy, and pathogenesis. *Ann Neurol* 1995;37:S43-S50.
32. **McCarty EC, Tsairis P, Warren RF.** Brachial neuritis. *Clin Orthop Relat Res* 1999;368:37-43.
33. **White SH, Goodfellow JW, Mowat A.** Posterior interosseous nerve palsy in rheumatoid arthritis. *J Bone Joint Surg [Br]* 1988;70-B:468-471.
34. **Martínez-Villén G, Badiola J, Alvarez-Alegret R, Mayayo E.** Nerve compression syndromes of the hand and forearm associated with tumours of non-neural origin and tumour-like lesions. *J Plast Reconstr Aesthet Surg* 2014;67:828-836.
35. **Lotem M, Fried A, Solzi P, Natanson T.** [Saturday night palsy]. *Harefuah* 1972;83:328. (In Hebrew)
36. **Bevelaqua AC, Hayter CL, Feinberg JH, Rodeo SA.** Posterior interosseous neuropathy: electrodiagnostic evaluation. *HSS J* 2012;8:184-189.
37. **Karabay N, Toros T, Ademoğlu Y, Ada S.** Ultrasonographic evaluation of the iatrogenic peripheral nerve injuries in upper extremity. *Eur J Radiol* 2010;73:234-240.
38. **Winfree CJ.** Iatrogenic peripheral nerve injuries. *Curr Surg* 2005;62:283-288.
39. **Allan CH.** Functional results of primary nerve repair. *Hand Clin* 2000;16:67-72.
40. **Peer S, Bodner G, Meirer R, Willeit J, Piza-Katzer H.** Examination of postoperative peripheral nerve lesions with high-resolution sonography. *AJR Am J Roentgenol* 2001;177:415-419.
41. **Lee FC, Singh H, Nazarian LN, Ratliff JK.** High-resolution ultrasonography in the diagnosis and intraoperative management of peripheral nerve lesions. *J Neurosurg* 2011;114:206-211.
42. **Basta I, Nikolić A, Apostolski S, et al.** Diagnostic value of combined magnetic resonance imaging examination of brachial plexus and electrophysiological studies in multifocal motor neuropathy. *Vojnosanit Pregl* 2014;71:723-729.
43. **Furuta T, Okamoto Y, Tohno E, et al.** Magnetic resonance microscopy imaging of posterior interosseous nerve palsy. *Jpn J Radiol* 2009;27:41-44.
44. **Hammert WC.** Radial nerve palsy. *Orthopaedic Knowledge Online Journal*. [http://orthopaortal.aaos.org/oko/article.aspx?article=OKO\\_HANo26](http://orthopaortal.aaos.org/oko/article.aspx?article=OKO_HANo26). (date last accessed 6 July 2016).
45. **Poppler LH, Davidge K, Lu JC, et al.** Alternatives to sural nerve grafts in the upper extremity. *Hand (N Y)* 2015;10:68-75.
46. **Bertelli JA, Ghizoni MF.** Results of nerve grafting in radial nerve injuries occurring proximal to the humerus, including those within the posterior cord. *J Neurosurg* 2016;124:179-185.
47. **Kim DH, Kam AC, Chandika P, Tiel RL, Kline DG.** Surgical management and outcome in patients with radial nerve lesions. *J Neurosurg* 2001;95:573-583.
48. **Li J, Hu H, Wang H, Cheng X.** [The effective analysis of microsurgical repair of radial nerve deep branch injury]. *Zhongguo Xiu Fu Chong Jian Wai Ke Za Zhi* 2012;26:1344-1347. (In Chinese)
49. **Payne SH Jr.** Nerve repair and grafting in the upper extremity. *J South Orthop Assoc* 2001;10:173-189.
50. **Hattori Y, Doi K, Ikeda K, Pagsaligan JM.** Vascularized ulnar nerve graft for reconstruction of a large defect of the median or radial nerves after severe trauma of the upper extremity. *J Hand Surg Am* 2005;30:986-989.
51. **Bumbasirević M, Lesić A, Bumbasirević V, et al.** The management of humeral shaft fractures with associated radial nerve palsy: a review of 117 cases. *Arch Orthop Trauma Surg* 2010;130:519-522.
52. **DeFranco MJ, Lawton JN.** Radial nerve injuries associated with humeral fractures. *J Hand Surg Am* 2006;31:655-663.
53. **Ring D, Chin K, Jupiter JB.** Radial nerve palsy associated with high-energy humeral shaft fractures. *J Hand Surg Am* 2004;29:144-147.
54. **Kim DH, Kam AC, Chandika P, Tiel RL, Kline DG.** Surgical management and outcome in patients with radial nerve lesions. *J Neurosurg* 2001;95:573-583.
55. **Shao YC, Harwood P, Grotz MR, Limb D, Giannoudis PV.** Radial nerve palsy associated with fractures of the shaft of the humerus: a systematic review. *J Bone Joint Surg [Br]* 2005;87-B:1647-1652.
56. **Mackinnon SE, Roque B, Tung TH.** Median to radial nerve transfer for treatment of radial nerve palsy. Case report. *J Neurosurg* 2007;107:666-671.
57. **García-López A, Navarro R, Martínez F, Rojas A.** Nerve transfers from branches to the flexor carpi radialis and pronator teres to reconstruct the radial nerve. *J Hand Surg Am* 2014;39:50-56.
58. **Davidge KM, Yee A, Kahn LC, Mackinnon SE.** Median to radial nerve transfers for restoration of wrist, finger, and thumb extension. *J Hand Surg Am* 2013;38:1812-1827.
59. **Midha R.** Nerve transfers for severe brachial plexus injuries: a review. *Neurosurg Focus* 2004;16:E5.



- 60. Smith RJ.** Tendon transfers to restore wrist and digit extensions. In: *Tendon transfers of the hand and forearm*. Boston: Little, Brown; 1987:35-56.
- 61. Kozin SH.** Tendon transfers for radial and median nerve palsies. *J Hand Ther* 2005;18:208-215.
- 62. Sammer DM, Chung KC.** Tendon transfers: part I. Principles of transfer and transfers for radial nerve palsy. *Plast Reconstr Surg* 2009;123:169e-177e.
- 63. Yavari M, Abdolrazaghi HA, Riahi A.** A comparative study on tendon transfer surgery in patients with radial nerve palsy. *World J Plast Surg* 2014;3:47-51.
- 64. Chuinard RG, Boyes JH, Stark HH, Ashworth CR.** Tendon transfers for radial nerve palsy: use of superficialis tendons for digital extension. *J Hand Surg Am* 1978;3:560-570.
- 65. Al-Qattan MM.** Tendon transfer for radial nerve palsy: a single tendon to restore finger extension as well as thumb extension/radial abduction. *J Hand Surg Eur Vol* 2012;37:855-862.
- 66. Riordan DC.** Tendon transfers in hand surgery. *J Hand Surg Am* 1983;8:748-753.
- 67. Tanis PJ, Poelhekke LM, Schreuders TA, Hovius SE.** [Tendon transfers to restore hand function following peripheral nerve injury in the arm]. *Ned Tijdschr Geneeskd* 2000;144:825-830. (In Dutch)
- 68. Al-Qattan M.** The "double wrist flexor" tendon transfer for radial nerve palsy. *Ann Plast Surg* 2013;71:34-36.
- 69. Stevanovic M, Sharpe F.** Functional free muscle transfer for upper extremity reconstruction. *Plast Reconstr Surg* 2014;134:257e-274e.
- 70. Li Z, Qin H, Feng Z, et al.** Human umbilical cord mesenchymal stem cell-loaded amniotic membrane for the repair of radial nerve injury. *Neural Regen Res* 2013;8:3441-3448.
- 71. Wang D, Huang X, Fu G, et al.** A simple model of radial nerve injury in the rhesus monkey to evaluate peripheral nerve repair. *Neural Regen Res* 2014;9:1041-1046.
- 72. Casañas J, de la Torre J, Soler F, et al.** Peripheral nerve regeneration after experimental section in ovine radial and tibial nerves using synthetic nerve grafts, including expanded bone marrow mesenchymal cells: morphological and neurophysiological results. *Injury* 2014;45:S2-S6.