



Surgical treatment of medial knee ligament injuries: current indications and techniques

N. Reha Tandogan
Asim Kayaalp

- The medial collateral ligament (MCL) and the posterior oblique ligament (POL) are the main static valgus restraints of the knee.
- Most isolated medial injuries can be treated with bracing and early knee motion.
- Combined MCL and ACL (anterior cruciate ligament) injuries can be managed with bracing of the knee followed by a delayed reconstruction of the ACL.
- Residual medial laxity may be addressed at the time of ACL surgery.
- Bony avulsions, incarceration of the distal MCL under the meniscus or over the pes anserinus tendons, open injuries, MCL tears combined with PCL or bi-cruciate injuries should be treated surgically.
- Chronic symptomatic medial instability can be managed with the recently described reconstruction techniques using free tendon grafts located at anatomical insertion sites.

Keywords: knee ligaments; medial collateral ligament; ligament reconstruction

Cite this article: Tandogan NR, Kayaalp A. Surgical treatment of medial knee ligament injuries: Current indications and techniques. *EFORT Open Rev* 2016;2:27-33. DOI: 10.1302/2058-5241.1.000007.

Injuries to the medial side of the knee have traditionally been treated conservatively with bracing and early motion, achieving satisfactory results in most patients.¹ Recent research on the anatomy and biomechanics of the medial side of the knee, coupled with the more anatomical techniques of reconstruction, have led to an increased interest in the surgical treatment of these injuries. This article will discuss the current treatment options in isolated and combined medial side injuries, with a special focus on the indications and techniques of surgery.

Anatomy and biomechanics

Following the description of the three layer concept of Warren and Marshall,² many authors, most notably Müller³

and Hughston,⁴ have contributed to our understanding of the anatomy and kinematics of the medial structures.

The three main static stabilizers on the medial side of the knee are the superficial and the deep medial collateral ligament and the posterior oblique ligament.²⁻⁵ The superficial medial collateral ligament (sMCL) originates slightly proximal and posterior to the medial epicondyle of the femur and courses distally to attach in 2 tibial sites. The proximal tibial attachment is 1 cm below the joint line and is mainly to the soft tissues, while the distal insertion is 5–7 cm below the joint line and attaches directly to bone on the tibia.^{5,6} The sMCL is the main valgus stabilizer of the knee in all flexion angles.⁷

The deep medial collateral ligament (dMCL) originates 1 cm distally from the insertion of the sMCL on the medial epicondyle and courses deep to the sMCL. It has strong attachments to the medial meniscus and attaches a few millimetres distal to the joint line on the tibia. It functions as a secondary valgus stabilizer and has a minor role in the prevention of anterior tibial translation.

The posterior oblique ligament (POL) is the thickening of the posteromedial capsule that originates distal and anterior to the gastrocnemius tubercle, then broadens and assumes a fan shape as it courses distally. The central part of the POL blends with and is slightly anterior to the attachment of the semimembranosus tendon. The POL acts as a stabilizer of valgus, internal and external rotation of the knee.⁸ Its role in valgus stability is more prominent in extension. The POL also acts as a secondary posterior stabilizer; this becomes more important in the absence of the PCL.⁸

Injury mechanisms

Medial side injuries of the knee most commonly occur during sports. Most of the injuries are isolated MCL tears, but injuries to the cruciates and POL may occur with increasing severity of the trauma. A recent study has found an incidence rate of 7.3 per 1000 person-years in an athletic population.⁹ Contact sports such as soccer, American football and skiing carry a high risk of medial side injuries. Grade III MCL injuries are associated with a cruciate ligament injury in 80% of cases; the ACL is involved in the majority of cases.¹⁰ High energy trauma such as motor vehicle and industrial accidents are usually associated with multi-ligament injuries and should be treated as knee dislocations.

Healing of medial injuries

The rich vasculature, the absence of contact with the synovial fluid, the concave geometry of the medial tibial plateau and the natural varus alignment of the knee contribute to the high spontaneous healing capacity of medial injuries. The healing of MCL has been studied extensively in animal models. Rabbit studies have confirmed the negative effects of immobilization, with early motion resulting in a mechanically superior healing response.¹¹ Smoking has been shown to impair healing.¹² The findings derived from these animal experiments have formed the basis of conservative treatment in humans; namely early range of motion in a protective brace and controlled weight-bearing.

Clinical findings

Patients present with pain and swelling on the medial side of the knee after a trauma involving a valgus strain. Physical examination reveals pain on palpation and valgus stress along the course of the ligament. Pain around the medial epicondyle may persist for several weeks and prevent full extension of the knee.

A positive valgus stress test at 30 degrees of knee flexion is the hallmark of a sMCL rupture. The test produces both pain and abnormal medial opening and should always be compared to the uninvolved knee. A medial opening of 3–5 mm indicates sMCL injury. This increases to 5–7 mm with the involvement of POL, and valgus stress test becomes positive in full extension. An opening of the medial side greater than 10 mm indicates an ACL injury, while an opening greater than 20 mm suggests a bicruciate injury. A more objective way of quantifying the valgus stress test is to use stress radiographs. Stress radiographs are difficult to perform in acute injuries due to pain and guarding by the patient; however, they can be very useful once the pain subsides. Laprade has shown that isolated sectioning of the sMCL produces a 3.2 mm abnormal medial opening compared to the uninjured knee. This opening increases to 9.8 mm with complete sectioning of the medial structures including the sMCL, dMCL and POL.¹³

The injury has been classified into 3 grades depending on the severity of the injury:¹⁴

- Grade I injury: The medial structures have microscopic injury with strain of the fibres and foci of haemorrhage. The patient exhibits mild pain and tenderness but no clinical instability.
- Grade II injury: The medial structures are partially torn with some fibres still intact. The pain is more pronounced and there is valgus instability with a firm end-point.
- Grade III injury: The medial structures are completely torn. Pain and functional loss is evident. There is a significant valgus instability without a firm end-point at

20 degrees of flexion. A rotatory instability may be present. This increased external rotation can be assessed with a positive dial test. This abnormal external rotation should be differentiated from the dial test observed in postero-lateral knee injuries using the varus stress test.

Imaging

All patients should undergo standard radiographs. Bony avulsions of the medial structures are rare and are usually from the femoral insertion. Stress radiographs compared to the uninvolved knee may be helpful in defining the severity of the injury in chronic cases as noted in the previous section (Fig. 1). These can be performed manually or using a mechanical stressing instrument such as the Telos device. Linear ossification along the MCL may be seen in chronic cases (Fig. 2).

Magnetic resonance imaging (MRI) is a valuable adjunct to clinical examination in the diagnosis of acute MCL injuries. The location and severity of injury, accompanying lesions of the cruciates, menisci and cartilage can clearly be seen in MRIs (Fig. 3). Traumatic bone bruises in the lateral compartment should alert the surgeon to the presence of severe medial injury. Miller et al have reported the prevalence of bone bruises in the lateral femoral condyle or lateral tibial plateau to be 45% in acute isolated MCL injuries.¹⁵

Conservative treatment

Almost all isolated Grade I and II MCL injuries can be treated conservatively. Following a short period of rest, bandage and cold therapy, early knee motion in a varus-valgus constrained brace with partial weight-bearing is the treatment of choice. Immobilization in a cast should be avoided owing to its negative effects on ligament healing and residual stiffness. No limits should be set in flexion-extension during bracing and early restitution of full knee extension should be the goal, especially in cases with injuries near the femoral insertion. Gradual return to sports after active quadriceps and hamstring rehabilitation and sports-specific training is possible. Lundberg and Messner reported excellent results in 38 Grade I or II MCL injuries followed prospectively for ten years. The median Lysholm score was 100 at 4 years and 95 at ten years.¹⁶ Return to sports is correlated with the severity of injury, and has been reported to be 11 days for Grade I and 20 days for Grade II injuries in one series.¹⁷ Although animal studies suggest that platelet-rich plasma (PRP) injections promote the early stages of ligament healing and the structural properties of the repair tissue in the rabbit model,¹⁸ only a single case report has been published with favourable outcome and early return to sport for MCL injuries.¹⁹

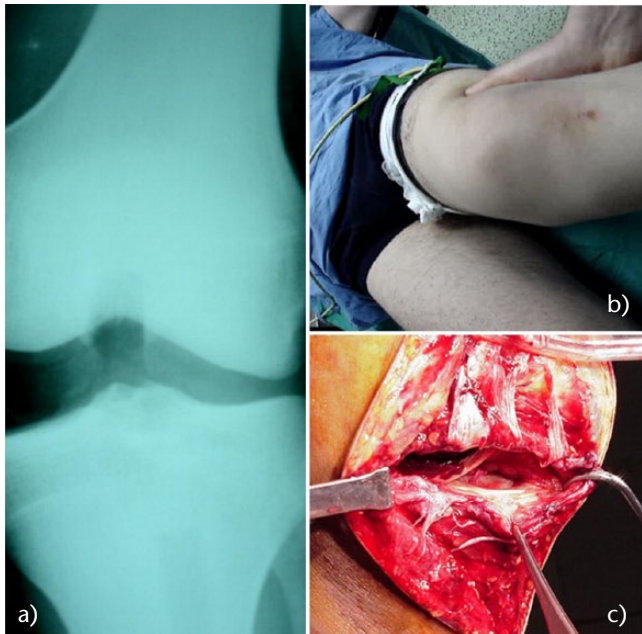


Fig. 1 A patient with antero-medial rotatory instability. a) Valgus stress radiographs; b) Manual valgus stress testing; c) Severe damage to the medial structures seen during surgery.

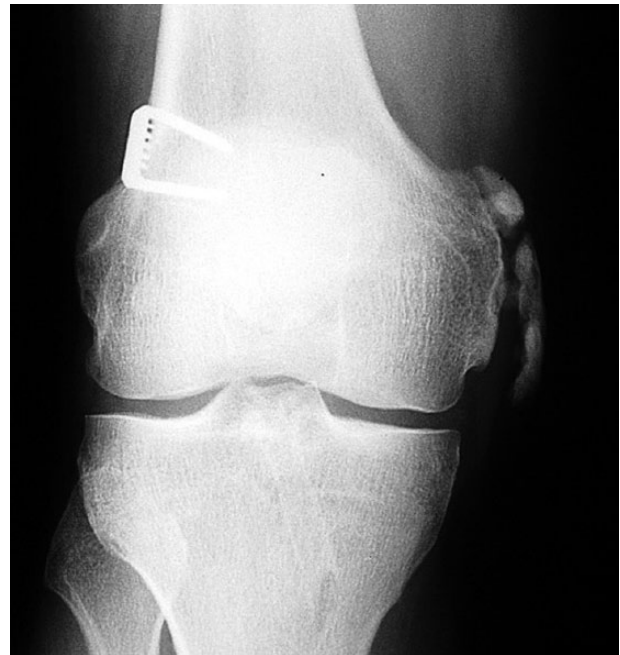

Fig. 2 The Pellegrini-Stieda lesion. Ossification along the course of MCL.

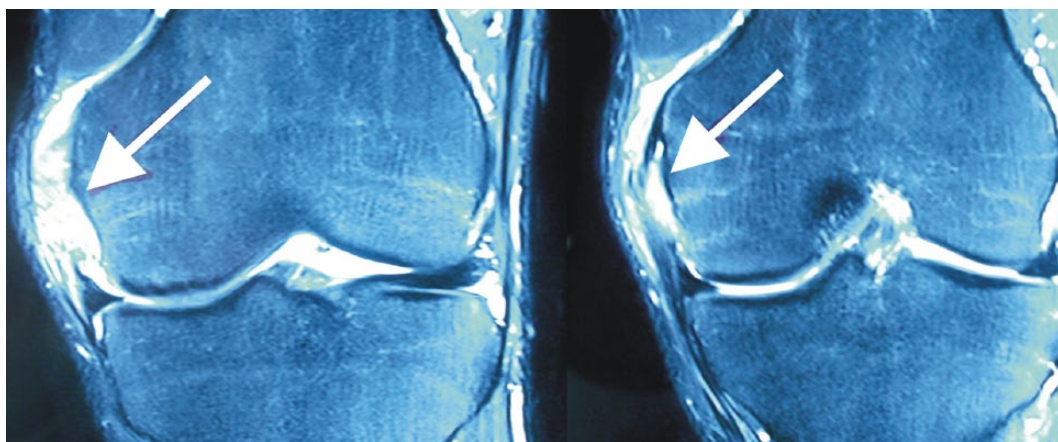


Fig. 3 Complete sMCL injury in T2 fat suppressed MRI. Peri-ligamentous oedema and complete mid-substance injury is observed.

Isolated Grade III medial knee injuries are rare; these cases should also undergo a trial of conservative treatment similar to Grade II injuries. Indelicato has reported that return to sports was possible at 9.2 weeks after early functional rehabilitation in Grade III injuries.²⁰ Patients with symptomatic residual instability after conservative treatment should be treated surgically.

Combined anterior cruciate ligament and medial collateral ligament injuries

Grade III MCL injuries are usually associated with an anterior cruciate ligament (ACL) injury. The optimal treatment for these combined injuries is controversial. Surgical repair

of both ligaments, popular in the 1980s, has led to unacceptably high rates of stiffness with similar stability compared to conservative treatment and has fallen out of favour. Current treatment of combined ACL and MCL injuries involves bracing up to 6 weeks to allow for healing of the medial injury, followed by reconstruction of the ACL when full knee motion has recovered. If medial laxity persists after conservative treatment, the medial structures can be reconstructed at the time of ACL surgery. Failure to recognize and treat the medial side results in abnormal strains on the ACL graft and is a significant reason for failure.²¹

In a systematic review of combined ACL and MCL injuries, Grant et al have reported that the best results were achieved in patients with delayed ACL reconstruction,

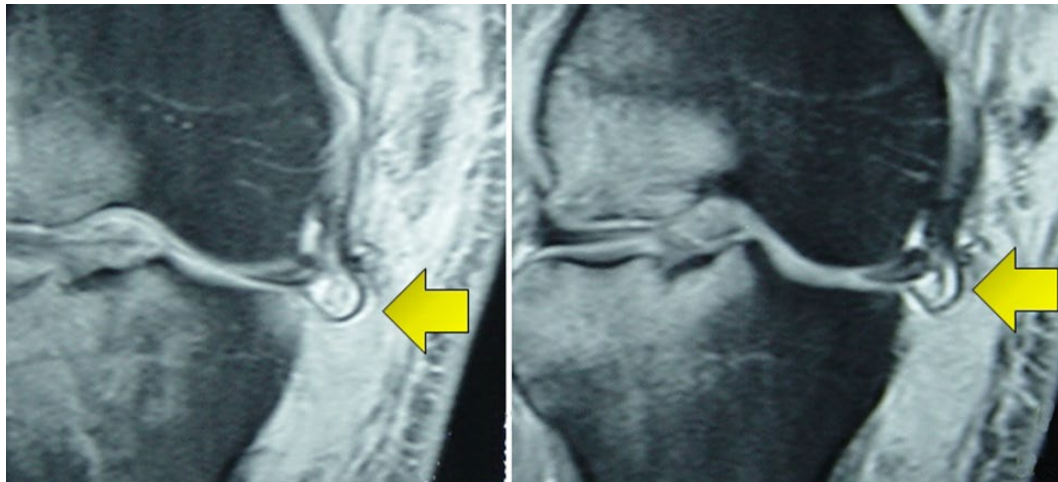


Fig. 4 Coronal MR images of interposition of the distal MCL under the medial meniscus after being torn from the tibial attachment. Widespread bone bruising in the lateral compartment indicates the severity of valgus injury.

allowing the MCL to heal and recovery of knee range of motion.²²

An alternative approach to combined injuries is isolated reconstruction of the ACL in the acute setting, followed by a brace treatment for MCL. The proponents of this treatment believe that ACL reconstruction provides a favourable environment for MCL healing and does not lead to loss of motion. Halinen et al have reported on 47 combined injuries in which isolated ACL reconstruction was compared with combined repair of the ACL and MCL. Similar stability was found in both groups and the authors concluded that isolated ACL reconstruction was sufficient to restore knee stability if performed in the acute setting.²³ Hara et al performed isolated ACL reconstruction in patients with associated Grade II medial injuries. They reported that their results were comparable to isolated ACL injuries and the residual medial laxity was not an issue.²⁴ The disadvantage of early isolated ACL reconstruction in combined injuries is that the patient might need a second surgical intervention if the medial side fails to heal adequately.

Indications for acute medial surgery

Although the majority of the MCL injuries will heal with conservative treatment, several indications exist for acute medial surgery. These are:

1. *Bony avulsion of MCL from the medial epicondyle.* Since the ligament is structurally intact in most of these cases, internal fixation of the fragment results in excellent stability. Screw fixation is the treatment of choice. “Peel-off” injuries of the POL can be addressed with suture-anchor fixation.²⁵ Large implants should be avoided and the fixation should be stable enough to allow early range of motion exercises.
2. *Interposition of the distal part of the MCL under the medial meniscus.* Surgical repair of the MCL and

menisco-tibial ligaments is mandatory in these cases to preserve meniscal function (Fig. 4).

3. *Combined posterior cruciate ligament (PCL) and MCL injury.* Unlike combined ACL and MCL injuries, acute postero-medial injuries require surgical repair. The recommended treatment is PCL reconstruction with a tendon graft and primary repair or reconstruction of the medial structures. The MCL, POL and semimembranosus corner should be explored in the first 3 weeks after injury and repaired if the tissues are of adequate quality. The POL plays an important role in the posterior stability of the knee and should be meticulously repaired to avoid excessive strain on the PCL graft.²⁶ Primary reconstruction with a tendon graft should be performed for the medial structures if the injury is too severe to preclude a solid primary repair. Stannard has reported a failure rate of 20% for primary repair compared to 4% for primary reconstruction.²⁷
4. *MCL injury associated with a bi-cruciate injury.* This injury should be considered a knee dislocation and patients should undergo reconstruction of the ACL and PCL, with primary repair/reconstruction of the medial side in the first 3–4 weeks following injury (see Video i).^{28,29} Some authors advocate a staged approach to prevent stiffness in these complex injuries.²⁷ The PCL reconstruction and repair/reconstruction of the medial side is performed first, followed by ACL reconstruction 6 weeks later. Reconstruction of all injured ligaments should have been performed before the patient starts weight-bearing.
5. *Open medial injuries.* These are usually a result of high-energy trauma and associated with multi-ligament injuries and fractures. A few simple sutures during primary wound closure will increase knee stability until definitive surgery.

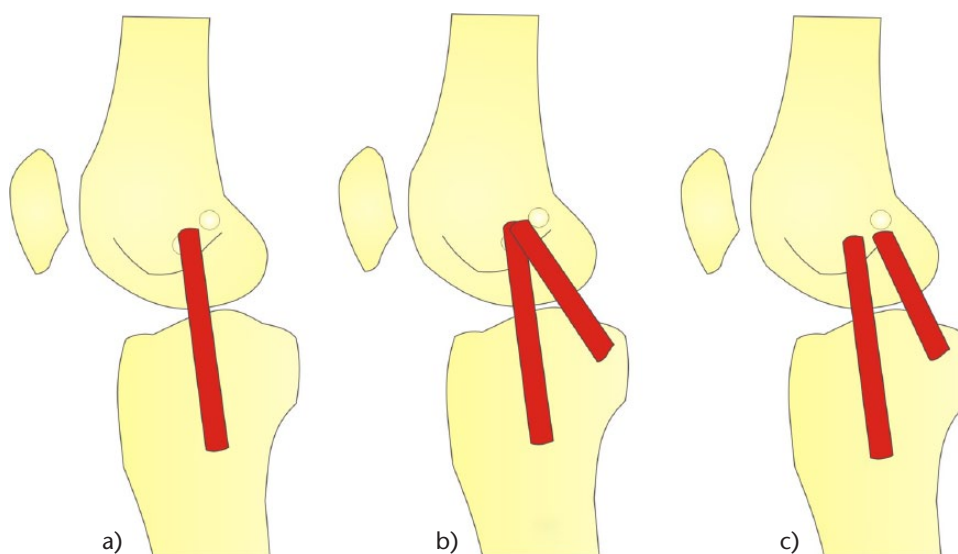


Fig. 5 Current medial reconstruction techniques. a) Isolated sMCL reconstruction; b) Reconstruction of the sMCL and POL using a single femoral tunnel; c) Anatomical reconstruction of the sMCL and POL using 4 separate tunnels in the femur and tibia.

6. *Relative indications.* Complete tibial side MCL injuries in athletes have a worse prognosis for healing and are considered to require surgery by some authors.³⁰ Similarly, surgical treatment of the medial side may be considered for combined ACL and MCL injuries in valgus knees.

Reconstruction of medial injuries

Reconstruction of medial knee injuries is indicated for chronic symptomatic medial instability after conservative treatment, or in cases where tissue quality precludes primary repair in acute cases. Historical techniques include a distally-pediced semimembranosus graft,³⁰ distally-based semitendinosus graft,³¹ pes anserinus transfer,³² proximal advancement or recession of the MCL on the medial epicondyle,³³ and advancement of the tibial insertion of sMCL.³⁴ These have been followed by single or double bundle reconstructions³⁵ using autografts (mostly hamstrings) or allografts.^{35,36}

In a cadaveric study, Wijdicks et al have shown that anatomical augmented repairs and anatomical reconstructions were able to improve knee stability and provide less than 2 mm of medial joint gapping at 0° and 20° of flexion.³⁷ Three treatment options are currently employed for the reconstruction of medial structures; all of them use free tendon grafts fixed at anatomical insertion sites under appropriate tension (Fig. 5).

1. Isolated sMCL reconstructions

These techniques are indicated in patients with medial laxity in flexion. A doubled free hamstring tendon graft is usually preferred. The tendon graft should be placed between the supero-posterior part of the medial epicondyle on the femur and the tibial insertion of sMCL 5–7 cm distal to the

joint line. Leaving the semitendinosus distal insertion intact is not recommended as the anterior insertion of the hamstrings is non-anatomical and does not restore adequate medial stability. Femoral fixation is usually performed in a blind tunnel with an interference screw, while tibial fixation can be achieved with a staple or a button implant on the lateral cortex (Fig. 6).

Large screw/washer combinations should be avoided in the femoral fixation. The distal fixation on the tibia is important as shorter grafts do not provide adequate rotational stability.³⁸ Yoshiya et al have reported on the 2-year follow-up of 24 patients using semitendinosus and gracilis tendons and have found normal or nearly normal IKDC scores in all patients.³⁰ The contralateral patellar tendon was used for ACL reconstruction in this series. Using a similar technique, Kim et al have found less than 2 mm medial laxity in 22 of 24 patients followed for 52 months, with a mean Lysholm score of 91.³⁹

2. Reconstruction of the sMCL and POL using a single femoral tunnel

These techniques are employed in patients with medial laxity in both full extension and 20 degrees flexion. A two-tailed graft is placed in a tunnel on the medial epicondyle. One limb of the graft is fixed distally on the sMCL on the tibia (Fig. 7a) while the other limb is fixed just anterior to the semimembranosus insertion on the tibia to reproduce the POL (Fig 7b). The sMCL graft is fixed in 20 degrees flexion, while the POL graft is tensioned in full extension (Fig. 7).

Lind et al have reported on the 2-year follow-up of 50 patients using this technique. They found that medial laxity was less than 5 mm in 98% of the patients, and 74% had IKDC A or B scores.⁴⁰

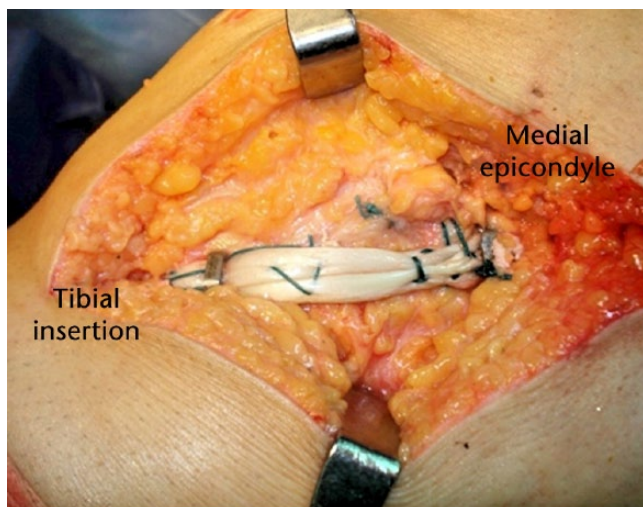
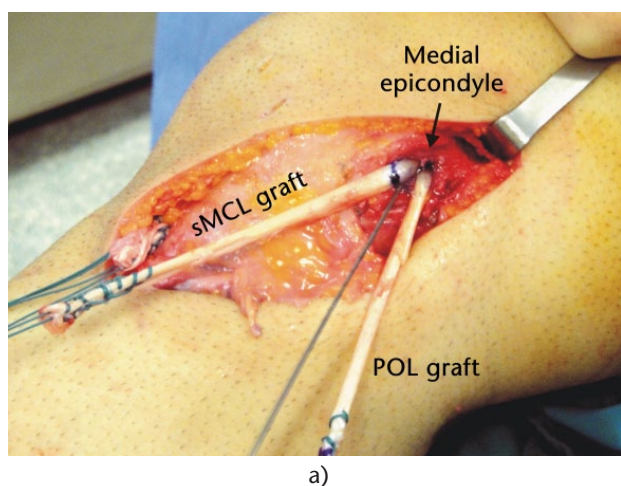
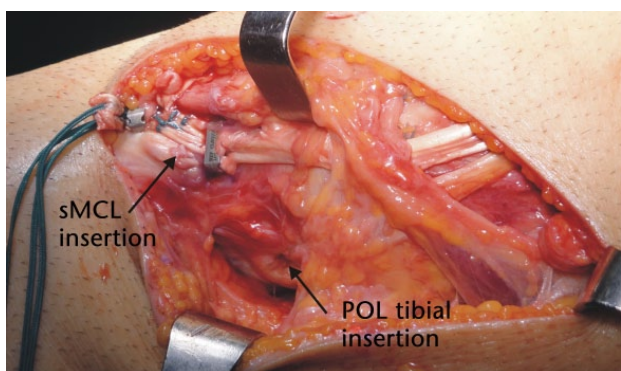


Fig. 6 Two-bundle hamstring tendon graft reconstruction of the sMCL.



a)



b)

Fig. 7 Reconstruction of the sMCL and POL using a single femoral insertion and two-limbed graft.

3. Anatomical reconstruction of the sMCL & POL

This technique has been described by LaPrade et al after extensive anatomical and biomechanical studies. The authors reconstruct the proximal and distal divisions of the

superficial medial collateral and the posterior oblique ligament using two separate grafts placed in 4 anatomical tunnels.⁴¹ The sMCL graft is placed between the supero-posterior part of the medial epicondyle and 6 cm distal to the joint line on the tibia. The POL graft femoral attachment is 7.7 mm distal and 2.9 mm anterior to the gastrocnemius tubercle, and the tibial insertion is slightly anterior to the direct arm attachment of the semimembranosus tendon on the tibia. The POL graft is fixed in full extension while the sMCL is tensioned and fixed in 20 degrees of flexion. The authors have reported excellent results with reduction of valgus laxity from 6.2 mm to 1.3 mm in 28 patients.

Conclusions

Isolated medial side injuries of the knee are common and are treated with bracing and early motion with excellent functional results. The surgeon should be aware that several indications exist for acute repair and not all medial side injuries are amenable to conservative treatment. Chronic symptomatic medial instability should be reconstructed with anatomical techniques.

Supplementary material

A video demonstrating surgical repair of acute bicruciate and MCL injury is available alongside this article: <http://www.efortopenreviews.org/content/1/2/27>

AUTHOR INFORMATION

Çankaya Orthopedics, Ankara, Turkey.

Correspondence should be sent to Reha Tandogan, Çankaya Orthopedics, Ankara, Turkey.
Email: rtandogan@ortoklinik.com

CONFLICT OF INTEREST

None declared.

FUNDING

No benefits in any form have been received or will be received from a commercial party related directly or indirectly to the subject of this article.

LICENCE

© 2016 The author(s)

This article is distributed under the terms of the Creative Commons Attribution-NonCommercial 4.0 License (<http://www.creativecommons.org/licenses/by-nc/4.0/>) which permits non-commercial use, reproduction and distribution of the work without further permission provided the original work is attributed.

REFERENCES

1. **Wijdicks CA, Griffith CJ, Johansen S, Engebretsen L, LaPrade RF.** Injuries to the medial collateral ligament and associated medial structures of the knee. *J Bone Joint Surg [Am]* 2010;92:1266–1280.
2. **Warren LF, Marshall JL.** The supporting structures and layers on the medial side of the knee: an anatomical analysis. *J Bone Joint Surg [Am]* 1979;61:56–62.
3. **Müller W.** *The knee. Form, function, and ligament reconstruction.* Berlin, Heidelberg New York: Springer-Verlag, 1983.

Downloaded from <http://www.efortopenreviews.org/content/1/2/27> on 09/14/2016 at 26:46AM via Open Access. This article is distributed under the terms of the Creative Commons Attribution-NonCommercial 4.0 License (<http://www.creativecommons.org/licenses/by-nc/4.0/>) which permits non-commercial use, reproduction and distribution of the work without further permission provided the original work is attributed. <https://creativecommons.org/licenses/by-nc/4.0/>

4. **Hughston JC, Eilers AF.** The role of the posterior oblique ligament in repairs of acute medial (collateral) ligament tears of the knee. *J Bone Joint Surg [Am]* 1973;55:923–940.
5. **LaPrade RF, Engebretsen AH, Ly TV, Johansen S, Wentorf FA, Engebretsen L.** The anatomy of the medial part of the knee. *J Bone Joint Surg [Am]* 2007;89:2000–2010.
6. **Robinson JR, Bull AM, Thomas RR, Amis AA.** The role of the medial collateral ligament and posteromedial capsule in controlling knee laxity. *Am J Sports Med* 2006;34:1815–1823.
7. **Griffith CJ, LaPrade RF, Johansen S, Armitage B, Wijdicks C, Engebretsen L.** Medial knee injury: part 1, static function of the individual components of the main medial knee structures. *Am J Sports Med* 2009;37:1762–1770.
8. **Petersen W, Loerch S, Schanz S, Raschke M, Zantop T.** The role of the posterior oblique ligament in controlling posterior tibial translation in the posterior cruciate ligament-deficient knee. *Am J Sports Med* 2008;36:495–501.
9. **Roach CJ, Haley CA, Cameron KL, Pallis M, Svoboda SJ, Owens BD.** The epidemiology of medial collateral ligament sprains in young athletes. *Am J Sports Med* 2014;42:1103–1109.
10. **Miyasaka KC, Daniel DM, Stone ML, et al.** The incidence of knee ligament injuries in the general population. *Am J Knee Surg* 1991;4:3–8.
11. **Thornton GM, Johnson JC, Maser RV, Marchuk LL, Shrive NG, Frank CB.** Strength of medial structures of the knee joint are decreased by isolated injury to the medial collateral ligament and subsequent joint immobilization. *J Orthop Res* 2005;23:1191–1198.
12. **Wright R, Mackey RB, Silva M, Steger-May K.** Smoking and mouse MCL healing. *J Knee Surg* 2010;23:193–199.
13. **LaPrade RF, Bernhardson AS, Griffith CJ, Macalena JA, Wijdicks CA.** Correlation of valgus stress radiographs with medial knee ligament injuries: an in vitro biomechanical study. *Am J Sports Med* 2010;38:330–338.
14. **American Medical Association Committee on the Medical Aspects of Sports.** Standard nomenclature of athletic injuries. Chicago: American Medical Association, 1966: 99–100.
15. **Miller MD, Osborne JR, Gordon WT, Hinkin DT, Brinker MR.** The natural history of bone bruises. A prospective study of magnetic resonance imaging-detected trabecular microfractures in patients with isolated medial collateral ligament injuries. *Am J Sports Med* 1998;26:15–19.
16. **Lundberg M, Messner K.** Long-term prognosis of isolated partial medial collateral ligament ruptures. A ten-year clinical and radiographic evaluation of a prospectively observed group of patients. *Am J Sports Med* 1996;24:160–163.
17. **Derscheid GL, Garrick JG.** Medial collateral ligament injuries in football. Nonoperative management of grade I and grade II sprains. *Am J Sports Med* 1981;9:365–368.
18. **Yoshioka T, Kanamori A, Washio T, et al.** The effects of plasma rich in growth factors (PRGF-Endoret) on healing of medial collateral ligament of the knee. *Knee Surg Sports Traumatol Arthrosc* 2013;21:1763–1769.
19. **Eirale C, Mauri E, Hamilton B.** Use of platelet rich plasma in an isolated complete medial collateral ligament lesion in a professional football (soccer) player: a case report. *Asian J Sports Med* 2013;4:158–162.
20. **Indelicato PA, Hermansdorfer J, Huegel M.** Nonoperative management of complete tears of the medial collateral ligament of the knee in intercollegiate football players. *Clin Orthop Relat Res* 1990;256:174–177.
21. **Battaglia MJ 2nd, Lenhoff MW, Ehteshami JR, et al.** Medial collateral ligament injuries and subsequent load on the anterior cruciate ligament: a biomechanical evaluation in a cadaveric model. *Am J Sports Med* 2009;37:305–311.
22. **Grant JA, Tannenbaum E, Miller BS, Bedi A.** Treatment of combined complete tears of the anterior cruciate and medial collateral ligaments. *Arthroscopy* 2012;28:110–122.
23. **Halinen J, Lindahl J, Hirvensalo E, Santavirta S.** Operative and nonoperative treatments of medial collateral ligament rupture with early anterior cruciate ligament reconstruction: a prospective randomized study. *Am J Sports Med* 2006;34:1134–1140.
24. **Hara K, Niga S, Ikeda H, Cho S, Muneta T.** Isolated anterior cruciate ligament reconstruction in patients with chronic anterior cruciate ligament insufficiency combined with grade II valgus laxity. *Am J Sports Med* 2008;36:333–339.
25. **Kuroda R, Muratsu H, Harada T, et al.** Avulsion fracture of the posterior oblique ligament associated with acute tear of the medial collateral ligament. *Arthroscopy* 2003;19:E18.
26. **Weimann A, Schatka I, Herbolt M, et al.** Reconstruction of the posterior oblique ligament and the posterior cruciate ligament in knees with posteromedial instability. *Arthroscopy* 2012;28:1283–1289.
27. **Stannard JP, Black BS, Azbell C, Volgas DA.** Posteromedial corner injury in knee dislocations. *J Knee Surg* 2012;25:429–434.
28. **Kovachevich R, Shah JP, Arens AM, Stuart MJ, Dahm DL, Levy BA.** Operative management of the medial collateral ligament in the multi-ligament injured knee: an evidence-based systematic review. *Knee Surg Sports Traumatol Arthrosc* 2009;17:823–829.
29. **Phisitkul P, James SL, Wolf BR, Amendola A.** MCL injuries of the knee: current concepts review. *Iowa Orthop J* 2006;26:77–90.
30. **Yoshiya S, Kuroda R, Mizuno K, Yamamoto T, Kurosaka M.** Medial collateral ligament reconstruction using autogenous hamstring tendons: technique and results in initial cases. *Am J Sports Med* 2005;33:1380–1385.
31. **Bosworth DM.** Transplantation of the semitendinosus for repair of laceration of medial collateral ligament of the knee. *J Bone Joint Surg [Am]* 1952;34-A:196–202.
32. **Slocum DB, Larson RL.** Rotatory instability of the knee. Its pathogenesis and a clinical test to demonstrate its presence. *J Bone Joint Surg [Am]* 1968;50:211–225.
33. **Shahane SA, Bickerstaff DR.** Proximal advancement of the medial collateral ligament for chronic medial instability of the knee joint. *Knee* 1998;5:191–197.
34. **O'Donoghue DH.** Reconstruction for medial instability of the knee. *J Bone Joint Surg [Am]* 1973;55:941–954.
35. **Borden PS, Kantaras AT, Caborn DN.** Medial collateral ligament reconstruction with allograft using a double-bundle technique. *Arthroscopy* 2002;18:E19.
36. **Marx RG, Hetsroni I.** Surgical technique: medial collateral ligament reconstruction using Achilles allograft for combined knee ligament injury. *Clin Orthop Relat Res* 2012;470:798–805.
37. **Wijdicks CA, Michalski MP, Rasmussen MT, et al.** Superficial medial collateral ligament anatomic augmented repair versus anatomic reconstruction: an in vitro biomechanical analysis. *Am J Sports Med* 2013;41:2858–2866.
38. **Van den Bogaerde JM, Shin E, Neu CP, Marder RA.** The superficial medial collateral ligament reconstruction of the knee: effect of altering graft length on knee kinematics and stability. *Knee Surg Sports Traumatol Arthrosc* 2011;19:560–568.
39. **Kim SJ, Lee DH, Kim TE, Choi NH.** Concomitant reconstruction of the medial collateral and posterior oblique ligaments for medial instability of the knee. *J Bone Joint Surg [Br]* 2008;90:1323–1327.
40. **Lind M, Jakobsen BW, Lund B, Hansen MS, Abdallah O, Christiansen SE.** Anatomical reconstruction of the medial collateral ligament and posteromedial corner of the knee in patients with chronic medial collateral ligament instability. *Am J Sports Med* 2009;37:1116–1122.
41. **LaPrade RF, Wijdicks CA.** Surgical technique: development of an anatomic medial knee reconstruction. *Clin Orthop Relat Res* 2012;470:806–814.