



Arthroscopic repair of the meniscus: surgical management and clinical outcomes

Alfonso Vaquero-Picado¹

E. Carlos Rodríguez-Merchán¹

- From the biomechanical and biological points of view, an arthroscopic meniscal repair (AMR) should always be considered as an option. However, AMR has a higher reoperation rate compared with arthroscopic partial meniscectomy, so it should be carefully indicated.
- Compared with meniscectomy, AMR outcomes are better and the incidence of osteoarthritis is lower when it is well indicated.
- Factors influencing healing and satisfactory results must be carefully evaluated before indicating an AMR.
- Tears in the peripheral third are more likely to heal than those in the inner thirds.
- Vertical peripheral longitudinal tears are the best scenario in terms of success when facing an AMR.
- 'Inside-out' techniques were considered as the gold standard for large repairs on mid-body and posterior parts of the meniscus. However, recent studies do not demonstrate differences regarding failure rate, functional outcomes and complications, when compared with the 'all-inside' techniques.
- Some biological therapies try to enhance meniscal repair success but their efficacy needs further research. These are: mechanical stimulation, supplemental bone marrow stimulation, platelet rich plasma, stem cell therapy, and scaffolds and membranes.
- Meniscal root tear/avulsion dramatically compromises meniscal stability, accelerating cartilage degeneration. Several options for reattachment have been proposed, but no differences between them have been established. However, repair of these lesions is actually the reference of the treatment.
- Meniscal ramp lesions consist of disruption of the peripheral attachment of the meniscus. In contrast, with meniscal root tears, the treatment of reference has not yet been well established.

Keywords: arthroscopic repair; meniscus; results; surgical techniques

Cite this article: *EFORT Open Rev* 2018;3:584-594.

DOI: 10.1302/2058-5241.3.170059

Introduction

Menisci were considered to be functionless structures for a long time. Although it is well known that meniscal excision can lead to early degenerative arthritis,¹ meniscectomy is still one of the most frequently performed procedures in orthopaedic surgery.^{2,3} The role of the menisci in joint stability,^{4,5} joint kinematics and load transfer⁶ is well documented. Recent advances in meniscal repair techniques and biological augmentation have introduced a new era of meniscal conservative surgery, leading to a more physiological function of the knee after surgery.⁷ In this article, we will describe the current state of understanding on meniscal repair, including indications for the procedure and clinical outcomes.

Anatomy and biomechanics

Several studies in recent decades have highlighted the importance of the meniscus in the global function of the knee, especially in a ligament-deficient joint.^{4,8-10} The micro and macro structures of the meniscus are determined by its functions. Alteration of its morphology could lead to early degenerative osteoarthritis.¹¹

The medial meniscus is C-shaped and slightly smaller than the lateral meniscus.¹² The lateral meniscus is usually longer and wider, with a variable shape, size and mobility, ranging from C-shape to almost discoid shape. They are suited to the lateral and medial compartments of the knee, facilitating the engagement between femoral and tibial surfaces. The medial meniscus covers 50–60% of the medial plateau and the lateral meniscus covers 70–80% of the lateral plateau.¹³ However, shape and total surface can vary between persons, especially in the lateral meniscus.¹²

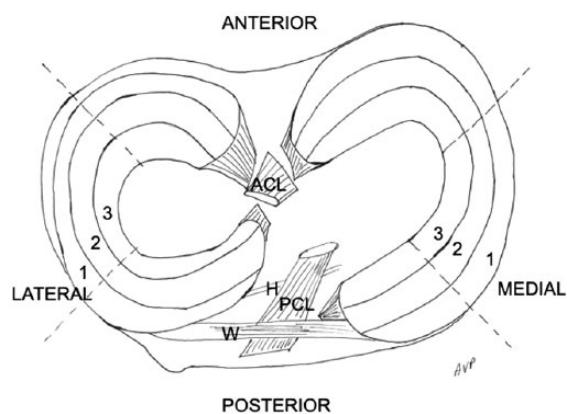


Fig. 1 Anatomy of the meniscal complex and Cooper zones.¹¹⁴

Note. ACL, anterior cruciate ligament; PCL, posterior cruciate ligament; H, Humphrey ligament; W, Wrisberg ligament.

Menisci are stabilized by several ligaments and attachments. Anterior and posterior roots are attached to the tibia. Meniscotibial union is an enthesis, which is much stronger than capsular attachments. Anterior roots are joined by the anterior intermeniscal (transverse) ligament. Attachment to the capsule is provided by the coronary ligament and, in the case of the medial meniscus, by expansions of the medial collateral ligament also. Finally, meniscofemoral ligaments (Humphrey anteriorly and Wrisberg posteriorly) attach the posterior part of the lateral meniscus to the lateral wall of the internal femoral condyle, surrounding the posterior cruciate ligament (PCL) (Fig. 1).¹⁴ These attachments and ligaments are important as they act like a ‘belt’ sustaining and facilitating menisci biomechanics.

The meniscus is composed of water (72%) and extracellular matrix and cells. The rest is dry, composed of collagen fibres (70%), proteoglycans (17%), non-collagenous proteins (8%), deoxyribonucleic acid (DNA) (2%) and adhesion glycoproteins (1%).¹³ Blood supply is provided by the perimeniscal capillary plexus. Although the foetal meniscus is fully vascularized, at 10 years of age, only the external 10–30% has direct blood supply.¹³ The perimeniscal capillary plexus receives blood from the medial, lateral and middle genicular arteries, and irrigates the external surface (25%) of menisci (vascular zone).¹⁵ The rest of the meniscus is almost avascular and aneural. The meniscus is almost acellular as well. Cellular expression changes from fibroblastic in the external third to fibrochondroblastic in the middle third and chondrocytic in the avascular zone.¹⁶ These points are important as ruptures in the vascular zone are suitable to be repaired, while in the avascular zone the healing rate after repair is lower.

Regarding its microscopic structure, collagen distribution is configured in three main layers.¹⁷ The most superficial (in

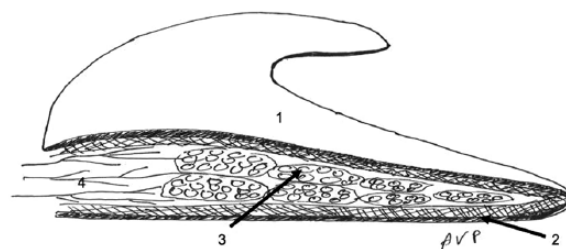


Fig. 2 Microstructure of the meniscus. On a sectioned meniscus, we can differentiate three main layers: (1) the superficial layer is a mesh of collagen fibres, (2) the second layer is composed of collagen fibres in lamellar disposition, (3) collagen fibres are disposed longitudinally in the deep layer, (4) blood supply enters by capsular side within the connective tissue.

contact with the tibia and femur) is considered as the ‘superficial network’, formed by a mesh of thin fibres. Deeply, in the second layer, the disposition of fibres is lamellar. In this layer, fibres are configured in a radial fashion in the anterior and posterior parts of the meniscus, and in a different configuration in the rest of the meniscus. In the central region (third layer), fibres are configured in a circular fashion. This configuration allows compressive loads to be transferred with circumferential dissipation (hoop stress transmission), and explains most of the patterns of meniscal tears (Fig. 2).¹⁷

The medial and lateral menisci have important biomechanical functions. They are not only force transmitters in load bearing and shock absorption, but they are also involved in joint stability, joint lubrication and proprioception. Regarding their main function, they transmit at least 50% of the forces between femur and tibia, and this transmission is greater in extension than in flexion.¹⁸ Their wedge shape facilitates transformation of compressive forces into concentric forces, which are transmitted by circumferential fibres to meniscal attachments in a hoop stress mechanism. When a meniscectomy is performed, cartilage surface contact between femur and tibia increases, and loads are more concentrated. Increased loads and shear forces due to bone-to-bone contact and instability may lead to the arthritic changes seen after meniscectomy.¹⁹

Reasons to repair a meniscal tear

Meniscal rupture triggers the release of a complex chain of degradative enzymes (i.e. interleukin-6, tumour necrosis factor alpha, etc.)²⁰ into the otherwise healthy knee. It has been demonstrated that these deleterious biochemical changes²¹ persist for months, developing a ‘chronic inflammation environment’ which can eventually cause cartilage degeneration.²² In addition, reestablishment of meniscal biomechanical properties can enhance joint

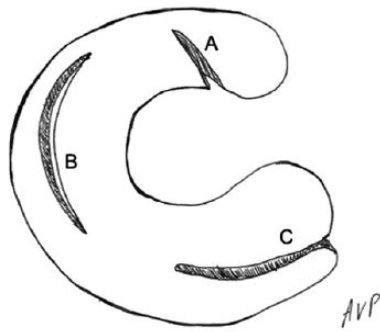


Fig. 3 Types of meniscal tear. A: radial tear. B: longitudinal vertical tear. C: horizontal tear.

stability. In a study conducted by Akpınar et al,²³ anterior cruciate ligament tears associated with medial meniscus tears demonstrated an increased anterior tibial translation at 24-month follow-up, in comparison with those cases with isolated anterior cruciate ligament (ACL) tears. Higher contact pressures between articular surfaces are observed when a meniscectomy is performed in comparison with an intact meniscus.²⁴ Meniscectomy has also been found to be strongly associated with the progression of articular cartilage damage in the ACL-reconstructed knee.²⁵ So, from biomechanical and biological points of view, meniscal repair seems to be a process that should always be performed. This has been endorsed by improved long-term outcomes.²⁶ However, meniscal repair still has a higher rate of reoperation in comparison with meniscectomy, so meniscal repair indication should be carefully evaluated.²⁶

Imaging healing (healing in MRI), clinical healing (absence of symptoms) and arthroscopic healing (healed and stable in a second-look arthroscopy) are not the same and are not always correlated.^{7,27} Some studies have reported that MRI findings after meniscal repair remain controversial, as the same signal can appear in a healed and in a non-healed meniscus.²⁸ Thus clinical symptoms are the guide if a non-healed meniscus is suspected, and arthroscopic second-look still remains the standard method of assessing meniscal healing.^{28,29} So, even if a meniscal repair is an attractive and theoretically well-based procedure, factors influencing healing or satisfactory results must be well evaluated before performing a meniscal repair.

Region: vascular (red zone) vs avascular (white zone)

As we have said before, the peripheral third is vascularized while the inner two thirds are avascular. From a biological point of view, tears in the peripheral third are more likely to heal than those in the central thirds. This hypothesis has been confirmed by several experimental studies.^{15,30} Clinical studies have also confirmed higher

rates of healing in peripheral third tears.^{31,32} In a study conducted by Uzun et al,³³ the rate of repair failure was five times higher in red-white zone tears in comparison with those in the red-red zone, but all the repairs performed in the acute setting did heal. The more peripheral the tear, the greater the rate of healing.⁷ However, extension to the avascular zone is not an absolute contraindication, and rates of healing of up to 87% have been reported,^{34,35} especially in young patients and concomitant anterior cruciate ligament reconstruction.³⁶

Pattern of tear

Vertical longitudinal tears are the best scenario in terms of success when facing a meniscal repair.³⁷ Other patterns include radial, horizontal or oblique extent to the avascular zone.³⁸ Complex tears and a rim > 3 mm are risk factors for increasing failure after repair. Bucket-handle tears have less potential of healing,³⁶ but in fresh tears and those which affect the peripheral third, repair should be attempted in order to avoid a subtotal meniscectomy.³⁹ When performed with concomitant ACL repair, bucket-handle meniscal tears and skeletal immaturity have been identified as statistical significant risk factors for meniscal repair failure.³⁶ In chronic cases, repair of bucket-handle tears is less successful,⁴⁰ but avoids osteoarthritic changes seen after meniscectomy⁴¹ (up to 57% of patients at 22-year follow-up)⁴¹ and should be attempted, especially in young patients (Fig. 3).

Concomitant anterior cruciate ligament (ACL) reconstruction

Many traumatic meniscal tears are associated with an ACL rupture. Increased healing rate has been reported when concomitant meniscal repair and ACL reconstruction are performed^{35,40} in comparison to isolated meniscal repair. In a study conducted by Espejo-Reina et al,⁴⁰ when the healing of a bucket-handle tear was evaluated, all the cases with a concomitant ACL reconstruction healed, while up to 50% of isolated meniscal tears did not. It is thought that release of growth factors and stem cells from bone marrow with ACL repair enhance the biological environment at the repair site,⁷ and several techniques such as venting marrow procedures (i.e. perforations at the intercondylar notch) have been designed to try to replicate this environment.

Degenerative vs traumatic tears

Degenerative tears are due to repeated loads which, in the long term, start to wear the meniscus as a result of years of micro-traumas and ageing of the menisci. After 40 years of age, the cellularity of menisci decreases and present cells suffer a process of senescence.¹³ It is thought that this could lead to higher risk of tears and decreased potential ability to repair.⁴² Indications for meniscal repair

Table 1. Favourable factors for successful meniscal repair

Localization	Red or white-red zone
Pattern	Vertical, bucket handle
ACL	Concomitant reconstruction
Mechanism	Traumatic
Age	Under 40 years

are almost exceptional and should be reserved for very select cases, such as medial root tears in the acute phase, deep radial tears that completely disrupt the hoop stress transmission or some horizontal cleavages in the very young active patient.

Degenerative tear pattern is usually horizontal, radial or complex, while vertical tears are almost non-existent. It is very common to find osteoarthritis affecting the tibiofemoral compartment where the meniscal tear is.⁴³ Almost two thirds of patients with degenerative tears present an asymptomatic tear in the contralateral knee.⁴⁴ Most degenerative cases respond adequately to conservative treatment with physical therapy and painkillers.^{43,45,46}

In contrast, traumatic tears are due to an acute overload, which surpasses the normal resistance of meniscus tissue, leading to a rupture. Vertical longitudinal tears are frequent and associated ligament injuries are not rare.³⁵ Traumatic tears are more frequent in young patients, and may benefit from surgical treatment more frequently (Table 1).^{34,35}

Treatment modalities

Conservative treatment

Conservative treatment consists of physical therapy (i.e. muscle strengthening), weight loss, non-steroidal anti-inflammatory therapy and intra-articular injections.⁴⁷ Most patients with a degenerative tear do well with conservative treatment, and no differences with surgical management have been reported at one-year follow-up in well-designed studies.^{43,45,46,48–50} This is probably due to the fact that degenerative meniscal tears are, in most cases, another expression of a degenerated knee, suffering cartilage damage, synovitis, etc.⁴⁷ Furthermore, arthroscopic partial meniscectomy of degenerative tears is not a cost-effective therapy in comparison with conservative treatment alone.⁵¹

Regarding traumatic tears, we have encountered several factors to evaluate before facing a repair. As a rule, small, peripheral (red-red or red-white zone tears) and stable tears are most likely to be treated conservatively leaving them in situ.⁵² In a study by Duchman et al,⁵² leaving in situ small and peripheral tears when concomitant ACL reconstruction is performed was found to be safe and more than 95% of patients did well without need for a new surgery on the lateral meniscus. However, results for

the medial meniscus were less predictable and repair is recommended in the context of an ACL reconstruction, even if the tear is stable.^{49,52,53}

Surgical treatment

Partial meniscectomy

The great debate when facing a meniscal tear from the point of view of surgical management is whether to repair or to perform a meniscectomy. In a systematic review conducted by Monk et al,⁵⁴ it was noted that, while meniscal repair is a good and widespread technique for the treatment of meniscal injuries, there is a surprising lack of studies comparing meniscal repair with conservative treatment.

Partial meniscectomy has been the gold standard for the surgical treatment of meniscal tears for many years. It is a safe treatment, with a low rate of complications and reoperation.²⁶ However, meniscectomy affects knee biomechanics and, with time, seems to lead to early osteoarthritis.⁵⁵ It has been well documented that the amount of resection is directly related to the degree of radiographic osteoarthritis.^{56,57}

Although current evidence tends to endorse the view that meniscal repair should always be attempted (especially in young patients),³⁵ several controversies exist as to whether performing a partial meniscectomy is better in the context of chronic tears in the avascular zone or in cases of failed repair.

Meniscal repair indications

In chronic tears in the avascular zone, poor biological support can condition the rate of success. Several authors have established six weeks after injury as the limit for performing a successful repair.^{18,58} However, recent studies have demonstrated that chronic tears can be repaired independently of the time passed since trauma.^{59,60} In young patients, cases of bucket-handle tears or large tears affecting the lateral meniscus, repair should always be attempted.^{61,62}

In a study conducted by O'Shea and Shelbourne, in the context of combined ACL and bucket-handle tears, good results were reported when repairing tears in the avascular zone.⁶³ However, tears were repaired in the acute setting and, as we have commented before, concomitant ACL rupture or reconstruction enhance the healing rate after meniscal repair.^{35,40} Otherwise, in a study by Espejo-Reina et al,⁴⁰ in isolated repair of chronic meniscal tears, more than 50% of cases (4 of 7) needed revision and relative risk (RR) for failure in isolated meniscal repairs was 21.3 times higher in comparison with those performed with concomitant ACL reconstruction. Medial meniscal injuries also affect ACL reconstruction stability, increasing anterior tibial translation.²³ For this reason, meniscal repair

should always be contemplated in the context of a concomitant ACL reconstruction, especially if the medial meniscus is affected.

Regarding failed meniscal repair, torn meniscus removal has been preferred traditionally.⁶⁴ However, revision repair after primary repair failure can be an option with high rates of success (up to 79% of cases).⁶⁴ Most cases needing revision for a failed primary repair occur within the first year after repair, in the context of a new trauma in young patients.^{64,65} When revision surgery is not possible following a failed primary repair, the quantity of meniscus to be removed is no higher than the quantity that would have been removed at a primary meniscectomy (so the risk of a well indicated meniscal repair should be taken).⁶⁶

Regarding meniscal repair, many studies have demonstrated its superiority in terms of leading to less osteoarthritis progression, less pain, and better long-term function when compared with partial meniscectomy.^{55,67,68} Even though the rate of failure and reoperation after meniscal repair is higher,²⁶ it is still cost effective in the long term.⁶⁹ As a rule, meniscal repair should always be performed attending to the following issues: anatomic reduction, biological augmentation, and circumferential compression across the tear.⁷ Other aspects such as ligament stability (and reconstruction if necessary) or lower-limb axis should be addressed before attempting a meniscal repair, as in other injuries of the knee.^{14,70}

Repair techniques

Many techniques for meniscal repair have been proposed. All of them can be performed arthroscopically and are classified as ‘outside-in’, ‘inside-out’ and ‘all-inside’ techniques,⁷¹ and all of them should be controlled by the surgeon, to be adapted to all tears. In general, vertical sutures are preferred over horizontal stitches,⁵⁷ although stronger repair techniques have not been correlated with better clinical outcomes.

In general terms, ‘outside-in’ techniques are indicated in anterior horn and mid-body tears, where a perpendicular trajectory related to the tear can be achieved.⁷¹ The suture is introduced from outside the capsule through the joint, engaging the two fragments of the meniscal tear and again through to the outside of the capsule. Knots are tied on the external surface of the capsule. Complication rates of ‘outside-in’ are similar to those for ‘all-inside’ and ‘inside-out’ techniques,⁷² and are usually related to joint stiffness, neurovascular injuries and failure of the meniscus to heal (Fig. 7).⁷³

The ‘inside-out’ techniques have been widely used for large repairs on the mid-body and posterior parts of the meniscus, but no differences have been observed in recent studies regarding failure rate, functional outcomes and complications, when comparing with the ‘all-inside’ techniques.³²

For the inside-out technique, the sutures are inserted from inside the joint, engaging both fragments of the tear and passing through the capsule. The sutures are recovered outside the joint and tied over the capsule. For this, an open approach should be used, increasing surgical time and potential complications (i.e. scarring, stiffness, neurovascular injuries, etc.).¹⁸

Several devices have been described to perform the all-inside repair.¹⁸ Recent devices are based on an anchor or suture fixator which is introduced from inside the joint through the capsular fragment of the tear until it rests over the capsule. The second implant is introduced through the central fragment of the tear and the capsule. It also rests over the external wall of the capsule, but the knot is tied from inside the joint. Its main advantages are that no open approaches are needed and that tears on the posterior horn are easier to repair, because the suture is perpendicular to the tear.⁷

In a systematic review conducted by Grant et al,³¹ there were no differences in rate of failure when comparing inside-out techniques (17%) with all-inside techniques (19%) for repair of isolated meniscal injuries. Nerve injuries were more frequent in inside-out techniques (9% vs. 2%), while implant-related complications (migration, breakage, soft tissue irritation or swelling) were more frequent in all-inside techniques. However, a lack of evidence exists, because most studies comparing inside-out to all-inside techniques are Level 4.³²

Meniscal repair in vertical longitudinal tears

Vertical longitudinal tears disrupt radial fibres while they are in line with circumferential fibres. When it is large enough, the central flap of the tear can move through the centre of the joint, resulting in the so-called bucket-handle tear. This condition can lead to knee locking and its resection to a subtotal meniscectomy, so reduction and repair where indicated should always be performed.

Small peripheral vertical longitudinal tears of the lateral meniscus can be left in situ with a high rate of healing but, when they are more than 10 mm in length or affecting the medial meniscus, they can become unstable and repair is also indicated (Figs. 4 and 5).⁵²

Horizontal cleavage tears

Horizontal cleavage tears do not affect the circumferential fibres of the meniscus, as they are continuous from anterior to posterior horn.⁷ Several studies have demonstrated an increased contact pressure between tibia and femur when the inferior leaf of a horizontal cleavage tear is resected.^{74,75}

Horizontal tears in young patients should be differentiated from degenerative tears. Repair of horizontal cleavage tears in young patients restores the normal biomechanics between tibia and femur, and clinical outcomes seem to be similar to those observed with repair in other tear

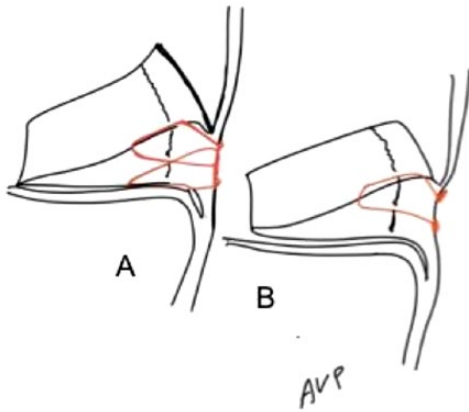


Fig. 4 Vertical longitudinal tear repair. A: inside-out technique, with knots tied over the capsule. B: all-inside technique, with anchors over the capsule.

patterns.^{76–78} In a recent systematic review conducted by Kurzweil et al,⁷⁷ the reoperation rate was 22.2% (77 cases out of 98 repairs), which is comparable to repair in other tear patterns.

Radial tears

Radial tears transect the meniscus from its free border (central) through the capsular border (peripheral). They can be complete or incomplete, and all of them disrupt the circumferential collagen fibres. When the radial tear includes the periphery, the meniscus is divided into two different portions, and the hoop stress transmission is partially disrupted, increasing tibiofemoral contact pressures, but not as much as in the case of meniscectomy.⁷⁹

Although classically radial tears were considered irreparable and better treated with a meniscectomy, in recent years several techniques for repair have been proposed. It has been reported that all-inside vertical repair is superior to an inside-out horizontal technique for radial tear repair,⁸⁰ but there is not enough evidence to support one technique over the other in terms of failure, stiffness or reduction of displacement, so it falls to a surgeon's preference to select the appropriate technique.^{81–84} However, there is evidence to support repair of radial tears over meniscectomy (Fig. 6).⁸²

Meniscal root tears

Interest in meniscal root tears and ramp lesions has increased in recent years. Injuries involving meniscal roots strongly affect joint kinematics and have been described as being similar to a total meniscectomy.²⁴ Root avulsion or deep radial tears near the root facilitate meniscal extrusion and loosening of the hoop stress mechanism, with increasing contact forces between articular surfaces and finally acceleration of articular degeneration.⁸⁵

Meniscal root tears can occur in the acute or chronic setting. Acute tears are usually due to a trauma with the knee hyperflexed or in the context of a multi-ligamentary injury. This is because posterior roots are under greater load, especially at 90° of flexion.⁸⁶ The posterior medial meniscus root is the most frequently injured, since it is the most overloaded root.⁸⁷

Regarding treatment, partial meniscectomy has been classically performed for the treatment of symptomatic root tears. It is still advocated by some authors for the treatment of symptomatic patients with Type 3 or 4 chondral injuries that are refractory to the non-operative treatment.⁸⁸ However, this indication has been revised by recent studies which suggest no benefit of meniscectomy for symptomatic degenerative posterior root tears.⁸⁹ Increasing efforts have been made in recent years for the development of repair techniques. Anchor fixation and transosseous pull out fixation are the most commonly used,^{88,90} and both are useful in restoring meniscus stability and function.⁹¹

Ramp lesions

Meniscal ramp lesions consist of a rupture of the peripheral attachment of the posterior horn of the meniscus (especially detachment of the meniscotibial ligament).⁹² They have been described as present in almost 16% of cases of ACL injury, and more frequently affect the medial meniscus.⁹³

Limited evidence exists regarding the biomechanical consequences of meniscal ramp lesion. In an experimental study conducted by Stephen et al, the authors reported increased lateral rotation and anterior translation in an ACL-deficient knee with concomitant ramp lesion, and they found that only the restoration of both injuries restored the normal knee kinematics.⁵

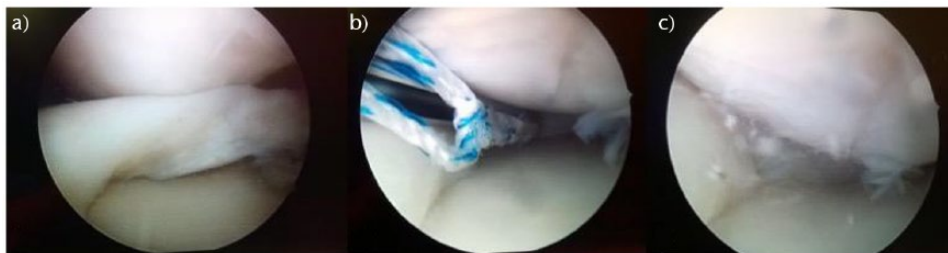

Fig. 5 Bucket-handle tear repair by all-inside technique. A: bucket-handle tear. B: reduction of tear and provisional knot. C: complete reduction and tied knot.

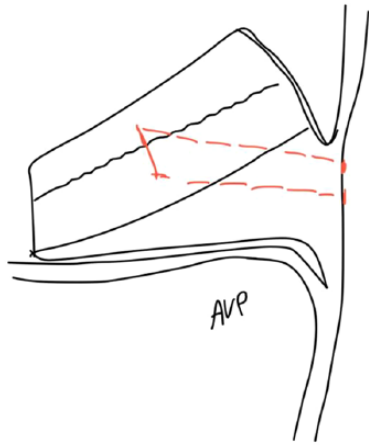


Fig. 6 Radial tear repair with and all-inside technique.

The main problem with ramp lesions is that clinical and radiological diagnosis is difficult. Although several MRI signs have been proposed, all authors conclude that arthroscopic evaluation is still necessary in the diagnosis of a meniscal ramp lesion.^{92–94} To date, no clear consensus exists about whether or not to treat meniscal ramp lesions, with good results found for both options. Well-designed studies are still necessary to assess which ramp lesions will benefit from repair.^{92–94}

How to enhance meniscal healing

Meniscal repair is conditioned by several factors such as almost complete absence of cells, vessels and nerves. Biological therapies try to enhance meniscal repair success by promoting chemotaxis or increasing cellular or matrix production.⁹⁵ Biological augmentation techniques in meniscal surgery appear to have significant potential, but there is a paucity of clinical evidence for most of them.⁹⁶

Mechanical stimulation

Synovial abrasion has been proposed as one method to improve healing response, because many growth factors are released and neovascularization is observed.⁹⁷ Trepagination allows communication between the vascular peripheral third and the avascular zone. Its theoretical advantage is to reconstitute the vascular flow through the white zone. These strategies have demonstrated utility in experimental and clinical studies.^{97–99}

Supplemental bone marrow stimulation

These techniques are designed to recreate the environment of an ACL reconstruction to enhance healing of isolated meniscal tears. While in ACL reconstruction drilling tunnels releases growth factors, blood and platelets from

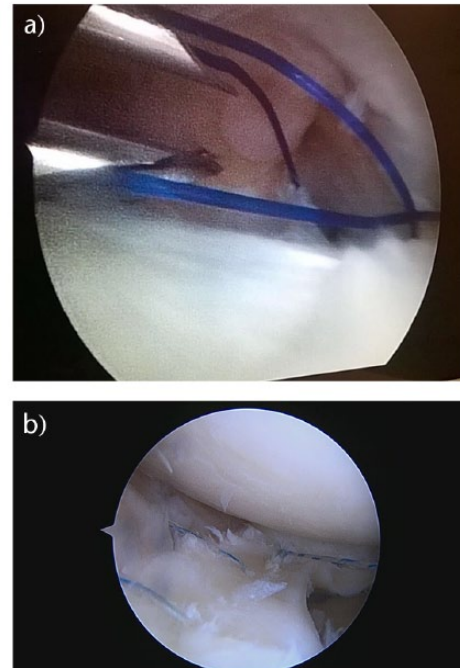


Fig. 7 Outside-in repair. 7A: Two spinal needles are introduced through both fragments with a non-absorbable suture. This suture is recovered through one portal with a suture retriever. Definitive suture is knotted to these sutures and passed through the meniscus fragments. 7B: Definitive sutures (stripped) are tied and knotted over the external wall of the capsule.

the bone, perforations or microfractures at the intercondylar notch are used to try to emulate the same effect. It is well known that concomitant ACL reconstruction enhances the rate of healing of a meniscal repair.^{35,40} Microfractures at the intercondylar notch have also been demonstrated as a reliable technique, comparable to ACL reconstruction in the healing rate of meniscal repair, in experimental and clinical studies.^{100,101}

Fibrin clot

Fibrin clot is composed of fibrin and platelets. Its theoretical utility in a meniscal repair is to serve as a scaffold to stimulate the reparative process.¹⁰² Its use has demonstrated increased healing in peripheral tears both in animal models and human patients.^{97,103,104} However, in central tears its rate of success diminishes, probably influenced by the fact that healing in the inner third is different from the peripheral zone.⁹⁷

Platelet rich plasma

Platelet rich plasma (PRP) is obtained from whole blood by centrifugation. Following this, platelets can be activated by several agents, such as calcium chloride, allowing them to aggregate, forming thrombin and fibrin and causing

the release of several growth factors.^{95,105,106} Few clinical studies have been published regarding the role of PRP in meniscal healing. No differences or a slightly increased healing rate have been observed, but cohorts studied were small.^{107,108}

Stem cell therapy

Stem cell therapy is used to enhance the ability of healing and regeneration of the meniscus. It has been demonstrated to be safe, while increasing healing and meniscal volume shown on an MRI and improving pain when stem cells are administered after meniscectomy.^{109,110} However, more studies are needed to provide enough evidence to support the routine use of stem cells in meniscal pathology.

Scaffolds and membranes

Use of biological membranes to protect and increase healing rates in meniscal repair has become more interesting recently. Partial scaffolds can be an alternative for patients with symptoms without cartilage degeneration after a partial meniscectomy.¹¹¹ Fascia lata and artificial scaffolds have demonstrated increased healing of meniscal repairs.^{112,113} However, larger studies are needed to support the use of membranes.

Complications of meniscal repair

One of the main reasons given by those surgeons who perform meniscectomy is the lower incidence of complications at short-term follow-up.¹¹ However, it has been well defined that meniscectomy increases knee instability and accelerates cartilage degeneration with a relative risk of 14 for radiological changes after meniscectomy in comparison with the general population.¹¹

Although meniscal repair has demonstrated better outcomes at mid to long-term follow-up regarding cartilage status and radiological changes,⁵⁵ it is not a complication-free procedure.

Conclusion

Vertical longitudinal tears are the best scenario in terms of success when facing an arthroscopic meniscal repair. Although 'inside-out' techniques have been widely used for large repairs on the mid-body and posterior parts of the meniscus, no differences have been observed in recent studies regarding failure rate, functional outcomes and complications, when compared with modern 'all-inside' techniques. Meniscal repair has a very high reoperation rate (up to 20.7% in the long term). Tears in the peripheral third are more likely to heal than those in the central thirds.

AUTHOR INFORMATION

¹Department of Orthopaedic Surgery, 'La Paz' University Hospital, Spain.

Correspondence should be sent to: E. C. Rodríguez-Merchán, Department of Orthopaedic Surgery, 'La Paz' University Hospital-IdiPaz, Paseo de la Castellana 261, 28046-Madrid, Spain.

Email: ecrmerchan@hotmail.com

FUNDING STATEMENT

No benefits in any form have been received or will be received from a commercial party related directly or indirectly to the subject of this article.

ICMJE CONFLICT OF INTEREST STATEMENT

None declared.

LICENCE

© 2018 The author(s)

This article is distributed under the terms of the Creative Commons Attribution-Non Commercial 4.0 International (CC BY-NC 4.0) licence (<https://creativecommons.org/licenses/by-nc/4.0/>) which permits non-commercial use, reproduction and distribution of the work without further permission provided the original work is attributed.

REFERENCES

- Dandy DJ, Jackson RW.** The diagnosis of problems after meniscectomy. *J Bone Joint Surg Br* 1975;57:349–352.
- Thorlund JB, Hare KB, Lohmander LS.** Large increase in arthroscopic meniscus surgery in the middle-aged and older population in Denmark from 2000 to 2011. *Acta Orthop* 2014;85:287–292.
- Beaufils P, Becker R, Kopf S, Matthieu O, Pujol N.** The knee meniscus: management of traumatic tears and degenerative lesions. *EFORT Open Rev* 2017;2:195–203.
- Shoemaker SC, Markolf KL.** The role of the meniscus in the anterior-posterior stability of the loaded anterior cruciate-deficient knee: effects of partial versus total excision. *J Bone Joint Surg Am* 1986;68:71–79.
- Stephen JM, Halewood C, Kittl C, Bollen SR, Williams A, Amis AA.** Posteromedial meniscocapsular lesions increase tibiofemoral joint laxity with anterior cruciate ligament deficiency, and their repair reduces laxity. *Am J Sports Med* 2016;44:400–408.
- Zhang AL, Miller SL, Coughlin DG, Lotz JC, Feeley BT.** Tibiofemoral contact pressures in radial tears of the meniscus treated with all-inside repair, inside-out repair and partial meniscectomy. *Knee* 2015;22:400–404.
- Woodmass JM, LaPrade RF, Sgaglione NA, Nakamura N, Krych AJ.** Meniscal repair: reconsidering indications, techniques, and biologic augmentation. *J Bone Joint Surg Am* 2017;99:1222–1231.
- Lorbach O, Kieb M, Herbolt M, Weyers I, Raschke M, Engelhardt M.** The influence of the medial meniscus in different conditions on anterior tibial translation in the anterior cruciate deficient knee. *Int Orthop* 2015;39:681–687.
- Shybut TB, Vega CE, Haddad J, et al.** Effect of lateral meniscal root tear on the stability of the anterior cruciate ligament-deficient knee. *Am J Sports Med* 2015;43:905–911.
- Ahn JH, Bae TS, Kang K-S, Kang SY, Lee SH.** Longitudinal tear of the medial meniscus posterior horn in the anterior cruciate ligament-deficient knee significantly influences anterior stability. *Am J Sports Med* 2011;39:2187–2193.

11. **McDermott ID, Amis AA.** The consequences of meniscectomy. *J Bone Joint Surg Br* 2006;88:1549–1556.
12. **McDermott ID, Sharifi F, Bull AMJ, Gupte CM, Thomas RW, Amis AA.** An anatomical study of meniscal allograft sizing. *Knee Surg Sports Traumatol Arthrosc* 2004;12:130–135.
13. **Tsuji A, Nakamura N, Horibe S.** Age-related changes in the knee meniscus. *Knee* 2017;24:1262–1270.
14. **Vaquero-Picado A, Rodríguez-Merchán EC.** Isolated posterior cruciate ligament tears: an update of management. *EFORT Open Rev* 2017;2:89–96.
15. **Arnoczky SP, Warren RF.** Microvasculature of the human meniscus. *Am J Sports Med* 1982;10:90–95.
16. **Arnoczky SP.** Building a meniscus: biologic considerations. *Clin Orthop Relat Res* 1999;367(suppl):S244–S253.
17. **Petersen W, Tillmann B.** Collagenous fibril texture of the human knee joint menisci. *Anat Embryol (Berl)* 1998;197:317–324.
18. **Laible C, Stein DA, Kiridly DN.** Meniscal repair. *J Am Acad Orthop Surg* 2013;21:204–213.
19. **Lanzer WL, Komenda G.** Changes in articular cartilage after meniscectomy. *Clin Orthop Relat Res* 1990;252:41–48.
20. **Bigoni M, Turati M, Sacerdote P, et al.** Characterization of synovial fluid cytokine profiles in chronic meniscal tear of the knee. *J Orthop Res* 2017;35:340–346.
21. **Brophy RH, Sandell LJ, Rai MF.** Traumatic and degenerative meniscus tears have different gene expression signatures. *Am J Sports Med* 2017;45:114–120.
22. **Brophy RH, Sandell LJ, Cheverud JM, Rai MF.** Gene expression in human meniscal tears has limited association with early degenerative changes in knee articular cartilage. *Connect Tissue Res* 2017;58:295–304.
23. **Akpınar B, Thorhauer E, Irrgang JJ, Tashman S, Fu FH, Anderst WJ.** Alteration of knee kinematics after anatomic anterior cruciate ligament reconstruction is dependent on associated meniscal injury. *Am J Sports Med* 2018;46:1158–1165.
24. **Allaire R, Muriuki M, Gilbertson L, Harner CD.** Biomechanical consequences of a tear of the posterior root of the medial meniscus: similar to total meniscectomy. *J Bone Joint Surg Am* 2008;90:1922–1931.
25. **Nakamae A, Adachi N, Deie M, et al.** Risk factors for progression of articular cartilage damage after anatomical anterior cruciate ligament reconstruction. *Bone Joint J* 2018;100-B:285–293.
26. **Paxton ES, Stock MV, Brophy RH.** Meniscal repair versus partial meniscectomy: a systematic review comparing reoperation rates and clinical outcomes. *Arthroscopy* 2011;27:1275–1288.
27. **Scott GA, Jolly BL, Henning CE.** Combined posterior incision and arthroscopic intra-articular repair of the meniscus: an examination of factors affecting healing. *J Bone Joint Surg Am* 1986;68:847–861.
28. **Hoffelner T, Resch H, Forstner R, Michael M, Minnich B, Tauber M.** Arthroscopic all-inside meniscal repair: does the meniscus heal? A clinical and radiological follow-up examination to verify meniscal healing using a 3-T MRI. *Skeletal Radiol* 2011;40:181–187.
29. **Pujol N, Tardy N, Boisrenoult P, Beaufile P.** Magnetic resonance imaging is not suitable for interpretation of meniscal status ten years after arthroscopic repair. *Int Orthop* 2013;37:2371–2376.
30. **Newman AP, Anderson DR, Daniels AU, Dales MC.** Mechanics of the healed meniscus in a canine model. *Am J Sports Med* 1989;17:164–175.
31. **Grant JA, Wilde J, Miller BS, Bedi A.** Comparison of inside-out and all-inside techniques for the repair of isolated meniscal tears: a systematic review. *Am J Sports Med* 2012;40:459–468.
32. **Fillingham YA, Riboh JC, Erickson BJ, Bach BR, Yanke AB.** Inside-out versus all-inside repair of isolated meniscal tears: an updated systematic review. *Am J Sports Med* 2017;45:234–242.
33. **Uzun E, Misir A, Kizkapan TB, Ozcamdalli M, Akkurt S, Guney A.** Factors affecting the outcomes of arthroscopically repaired traumatic vertical longitudinal medial meniscal tears. *Orthop J Sports Med* 2017;5:232596711712448.
34. **Noyes FR, Barber-Westin SD.** Arthroscopic repair of meniscal tears extending into the avascular zone in patients younger than twenty years of age. *Am J Sports Med* 2002;30:589–600.
35. **Noyes FR, Barber-Westin SD.** Arthroscopic repair of meniscus tears extending into the avascular zone with or without anterior cruciate ligament reconstruction in patients 40 years of age and older. *Arthroscopy* 2000;16:822–829.
36. **Krych AJ, Pitts RT, Dajani KA, Stuart MJ, Levy BA, Dahm DL.** Surgical repair of meniscal tears with concomitant anterior cruciate ligament reconstruction in patients 18 years and younger. *Am J Sports Med* 2010;38:976–982.
37. **Krych AJ, McIntosh AL, Voll AE, Stuart MJ, Dahm DL.** Arthroscopic repair of isolated meniscal tears in patients 18 years and younger. *Am J Sports Med* 2008;36:1283–1289.
38. **Yim J-H, Seon J-K, Song E-K, et al.** A comparative study of meniscectomy and nonoperative treatment for degenerative horizontal tears of the medial meniscus. *Am J Sports Med* 2013;41:1565–1570.
39. **Ahn JH, Kim K-I, Wang JH, Kyung BS, Seo MC, Lee SH.** Arthroscopic repair of bucket-handle tears of the lateral meniscus. *Knee Surg Sports Traumatol Arthrosc* 2015;23:205–210.
40. **Espejo-Reina A, Serrano-Fernández JM, Martín-Castilla B, Estades-Rubio FJ, Briggs KK, Espejo-Baena A.** Outcomes after repair of chronic bucket-handle tears of medial meniscus. *Arthroscopy* 2014;30:492–496.
41. **Vautrin M, Schwartz C.** Future of 34 meniscectomies after bucket-handle meniscus tear: a retrospective study with a follow-up over 22 years. *Eur J Orthop Surg Traumatol* 2016;26:435–440.
42. **Mesiha M, Zurakowski D, Soriano J, Nielson JH, Zarins B, Murray MM.** Pathologic characteristics of the torn human meniscus. *Am J Sports Med* 2007;35:103–112.
43. **Howell R, Kumar NS, Patel N, Tom J.** Degenerative meniscus: pathogenesis, diagnosis, and treatment options. *World J Orthop* 2014;5:597–602.
44. **Zanetti M, Pfirrmann CWA, Schmid MR, Romero J, Seifert B, Hodler J.** Patients with suspected meniscal tears: prevalence of abnormalities seen on MRI of 100 symptomatic and 100 contralateral asymptomatic knees. *AJR Am J Roentgenol* 2003;181:635–641.
45. **Katz JN, Brophy RH, Chaisson CE, et al.** Surgery versus physical therapy for a meniscal tear and osteoarthritis. *N Engl J Med* 2013;368:1675–1684.
46. **Sihvonen R, Paavola M, Malmivaara A, et al.** Arthroscopic partial meniscectomy versus sham surgery for a degenerative meniscal tear. *N Engl J Med* 2013;369:2515–2524.
47. **Ayhan E, Kesmezacar H, Akgun I.** Intraarticular injections (corticosteroid, hyaluronic acid, platelet rich plasma) for the knee osteoarthritis. *World J Orthop* 2014;5:351–361.
48. **Beaufils P, Becker R, Kopf S, Matthieu O, Pujol N.** The knee meniscus: management of traumatic tears and degenerative lesions. *EFORT Open Rev* 2017;2:195–203.

49. **Beaufils P, Becker R, Kopf S, et al.** Surgical management of degenerative meniscus lesions: the 2016 ESSKA meniscus consensus. *Knee Surg Sports Traumatol Arthrosc* 2017;25:335–346.
50. **van de Graaf VA, Wolterbeek N, Mutsaerts ELAR, et al.** Arthroscopic partial meniscectomy or conservative treatment for nonobstructive meniscal tears: a systematic review and meta-analysis of randomized controlled trials. *Arthroscopy* 2016;32:1855–1865.e4.
51. **Marsh JD, Birmingham TB, Giffin JR, et al.** Cost-effectiveness analysis of arthroscopic surgery compared with non-operative management for osteoarthritis of the knee. *BMJ Open* 2016;6:e009949.
52. **Duchman KR, Westermann RW, Spindler KP, et al.** The fate of meniscus tears left in situ at the time of anterior cruciate ligament reconstruction: a 6-year follow-up study from the MOON cohort. *Am J Sports Med* 2015;43:2688–2695.
53. **Pujol N, Beaufils P.** Healing results of meniscal tears left in situ during anterior cruciate ligament reconstruction: a review of clinical studies. *Knee Surg Sports Traumatol Arthrosc* 2009;17:396–401.
54. **Monk P, Garfjeld Roberts P, Palmer AJR, et al.** The urgent need for evidence in arthroscopic meniscal surgery. *Am J Sports Med* 2017;45:965–973.
55. **Lutz C, Dalmay F, Ehkirch FP, et al.** Meniscectomy versus meniscal repair: 10 years radiological and clinical results in vertical lesions in stable knee. *Orthop Traumatol Surg Res* 2015;101(suppl):S327–S331.
56. **Englund M, Lohmander LS.** Risk factors for symptomatic knee osteoarthritis fifteen to twenty-two years after meniscectomy. *Arthritis Rheum* 2004;50:2811–2819.
57. **Stärke C, Kopf S, Petersen W, Becker R.** Meniscal repair. *Arthroscopy* 2009;25:1033–1044.
58. **Tengrootenhuysen M, Meermans G, Pittoors K, van Riet R, Victor J.** Long-term outcome after meniscal repair. *Knee Surg Sports Traumatol Arthrosc* 2011;19:236–241.
59. **van der Wal RJP, Thomassen BJW, Swen J-WA, van Arkel ERA.** Time interval between trauma and arthroscopic meniscal repair has no influence on clinical survival. *J Knee Surg* 2016;29:436–442.
60. **Barber-Westin SD, Noyes FR.** Clinical healing rates of meniscus repairs of tears in the central-third (red-white) zone. *Arthroscopy* 2014;30:134–146.
61. **Karupiah SV, Majeed H, Sigamoney K, Geutjens G.** Failure of meniscal repair association with late anterior cruciate ligament reconstruction. *J Orthop* 2016;13:106–109.
62. **Shelbourne KD, Dersam MD.** Comparison of partial meniscectomy versus meniscus repair for bucket-handle lateral meniscus tears in anterior cruciate ligament reconstructed knees. *Arthroscopy* 2004;20:581–585.
63. **O'Shea JJ, Shelbourne KD.** Repair of locked bucket-handle meniscal tears in knees with chronic anterior cruciate ligament deficiency. *Am J Sports Med* 2003;31:216–220.
64. **Krych AJ, Reardon P, Sousa P, Levy BA, Dahm DL, Stuart MJ.** Clinical outcomes after revision meniscus repair. *Arthroscopy* 2016;32:1831–1837.
65. **Shieh AK, Edmonds EW, Pennock AT.** Revision meniscal surgery in children and adolescents: risk factors and mechanisms for failure and subsequent management. *Am J Sports Med* 2016;44:838–843.
66. **Pujol N, Barbier O, Boisrenoult P, Beaufils P.** Amount of meniscal resection after failed meniscal repair. *Am J Sports Med* 2011;39:1648–1652.
67. **Stein T, Mehling AP, Welsch F, von Eisenhart-Rothe R, Jäger A.** Long-term outcome after arthroscopic meniscal repair versus arthroscopic partial meniscectomy for traumatic meniscal tears. *Am J Sports Med* 2010;38:1542–1548.
68. **Xu C, Zhao J.** A meta-analysis comparing meniscal repair with meniscectomy in the treatment of meniscal tears: the more meniscus, the better outcome? *Knee Surg Sports Traumatol Arthrosc* 2015;23:164–170.
69. **Feeley BT, Liu S, Garner AM, Zhang AL, Pietzsch JB.** The cost-effectiveness of meniscal repair versus partial meniscectomy: a model-based projection for the United States. *Knee* 2016;23:674–680.
70. **Vaquero-Picado A, Rodríguez-Merchán EC.** Cartilage injuries of the knee. In: Rodríguez-Merchán EC, Liddle AD, eds. *Joint preservation in the adult knee*. Basel: Springer International Publishing, 2017:127–141.
71. **Lembach M, Johnson DL.** Meniscal repair techniques required for the surgeon performing anterior cruciate ligament reconstruction. *Orthopedics* 2014;37:617–621.
72. **Hantes ME, Zachos VC, Varitimidis SE, Dailiana ZH, Karachalios T, Malizos KN.** Arthroscopic meniscal repair: a comparative study between three different surgical techniques. *Knee Surg Sports Traumatol Arthrosc* 2006;14:1232–1237.
73. **Vinyard TR, Wolf BR.** Meniscal repair: outside-in repair. *Clin Sports Med* 2012;31:33–48.
74. **Beamer BS, Walley KC, Okajima S, et al.** Changes in contact area in meniscus horizontal cleavage tears subjected to repair and resection. *Arthroscopy* 2017;33:617–624.
75. **Koh JL, Yi SJ, Ren Y, Zimmerman TA, Zhang L-Q.** Tibiofemoral contact mechanics with horizontal cleavage tear and resection of the medial meniscus in the human knee. *J Bone Joint Surg Am* 2016;98:1829–1836.
76. **Salléde Chou E, Pujol N, Rochongar G, et al.** Analysis of short and long-term results of horizontal meniscal tears in young adults. *Orthop Traumatol Surg Res* 2015;101(suppl):S317–S322.
77. **Kurzweil PR, Lynch NM, Coleman S, Kearney B.** Repair of horizontal meniscus tears: a systematic review. *Arthroscopy* 2014;30:1513–1519.
78. **Pujol N, Bohu Y, Boisrenoult P, Macdes A, Beaufils P.** Clinical outcomes of open meniscal repair of horizontal meniscal tears in young patients. *Knee Surg Sports Traumatol Arthrosc* 2013;21:1530–1533.
79. **Bedi A, Kelly NH, Baad M, et al.** Dynamic contact mechanics of the medial meniscus as a function of radial tear, repair, and partial meniscectomy. *J Bone Joint Surg Am* 2010;92:1398–1408.
80. **Beamer BS, Masoudi A, Walley KC, et al.** Analysis of a new all-inside versus inside-out technique for repairing radial meniscal tears. *Arthroscopy* 2015;31:293–298.
81. **Alentorn-Geli E, Choi JHJ, Stuart JJ, et al.** Inside-out or outside-in suturing should not be considered the standard repair method for radial tears of the midbody of the lateral meniscus: a systematic review and meta-analysis of biomechanical studies. *J Knee Surg* 2016;29:604–612.
82. **Moulton SG, Bhatia S, Civitarese DM, Frank RM, Dean CS, LaPrade RF.** Surgical techniques and outcomes of repairing meniscal radial tears: a systematic review. *Arthroscopy* 2016;32:1919–1925.
83. **Bhatia S, Civitarese DM, Turnbull TL, et al.** A novel repair method for radial tears of the medial meniscus: biomechanical comparison of transtibial 2-tunnel and double horizontal mattress suture techniques under cyclic loading. *Am J Sports Med* 2016;44:639–645.
84. **Cinque ME, Geeslin AG, Chahla J, Dornan GJ, LaPrade RF.** Two-tunnel transtibial repair of radial meniscus tears produces comparable results to inside-out repair of vertical meniscus tears. *Am J Sports Med* 2017;45:2253–2259.
85. **Bhatia S, LaPrade CM, Ellman MB, LaPrade RF.** Meniscal root tears: significance, diagnosis, and treatment. *Am J Sports Med* 2014;42:3016–3030.

- 86. Fox AJS, Bedi A, Rodeo SA.** The basic science of human knee menisci: structure, composition, and function. *Sports Health* 2012;4:340–351.
- 87. Jones AO, Houang MTW, Low RS, Wood DG.** Medial meniscus posterior root attachment injury and degeneration: MRI findings. *Australas Radiol* 2006;50:306–313.
- 88. Kim SB, Ha JK, Lee SW, et al.** Medial meniscus root tear refixation: comparison of clinical, radiologic, and arthroscopic findings with medial meniscectomy. *Arthroscopy* 2011;27:346–354.
- 89. Krych AJ, Johnson NR, Mohan R, Dahm DL, Levy BA, Stuart MJ.** Partial meniscectomy provides no benefit for symptomatic degenerative medial meniscus posterior root tears. *Knee Surg Sports Traumatol Arthrosc* 2018;26:1117–1122.
- 90. Jung Y-H, Choi N-H, Oh J-S, Victoroff BN.** All-inside repair for a root tear of the medial meniscus using a suture anchor. *Am J Sports Med* 2012;40:1406–1411.
- 91. Kim J-H, Chung J-H, Lee D-H, Lee Y-S, Kim J-R, Ryu K-J.** Arthroscopic suture anchor repair versus pullout suture repair in posterior root tear of the medial meniscus: a prospective comparison study. *Arthroscopy* 2011;27:1644–1653.
- 92. Chahla J, Dean CS, Moatshe G, et al.** Meniscal ramp lesions: anatomy, incidence, diagnosis, and treatment. *Orthop J Sports Med* 2016;4:2325967116657815.
- 93. Liu X, Feng H, Zhang H, Hong L, Wang XS, Zhang J.** Arthroscopic prevalence of ramp lesion in 868 patients with anterior cruciate ligament injury. *Am J Sports Med* 2011;39:832–837.
- 94. Sonnery-Cottet B, Conteduca J, Thaumat M, Gunepin FX, Seil R.** Hidden lesions of the posterior horn of the medial meniscus: a systematic arthroscopic exploration of the concealed portion of the knee. *Am J Sports Med* 2014;42:921–926.
- 95. Taylor SA, Rodeo SA.** Augmentation techniques for isolated meniscal tears. *Curr Rev Musculoskelet Med* 2013;6:95–101.
- 96. Moran CJ, Busilacchi A, Lee CA, Athanasiou KA, Verdonk PC.** Biological augmentation and tissue engineering approaches in meniscus surgery. *Arthroscopy* 2015;31:944–955.
- 97. Ritchie JR, Miller MD, Bents RT, Smith DK.** Meniscal repair in the goat model. The use of healing adjuncts on central tears and the role of magnetic resonance arthrography in repair evaluation. *Am J Sports Med* 1998;26:278–284.
- 98. Zhang Z, Arnold JA.** Trephination and suturing of avascular meniscal tears: a clinical study of the trephination procedure. *Arthroscopy* 1996;12:726–731.
- 99. Tetik O, Kocabey Y, Johnson DL.** Synovial abrasion for isolated, partial thickness, undersurface, medial meniscus tears. *Orthopedics* 2002;25:675–678.
- 100. Howarth WR, Brochard K, Campbell SE, Grogan BF.** Effect of microfracture on meniscal tear healing in a goat (*capra hircus*). *Orthopedics* 2016;39:105–110.
- 101. Dean CS, Chahla J, Matheny LM, Mitchell JJ, LaPrade RF.** Outcomes after biologically augmented isolated meniscal repair with marrow venting are comparable with those after meniscal repair with concomitant anterior cruciate ligament reconstruction. *Am J Sports Med* 2017;45:1341–1348.
- 102. Arnoczky SP, Warren RF, Spivak JM.** Meniscal repair using an exogenous fibrin clot: an experimental study in dogs. *J Bone Joint Surg Am* 1988;70:1209–1217.
- 103. van Trommel MF, Simonian PT, Potter HG, Wickiewicz TL.** Arthroscopic meniscal repair with fibrin clot of complete radial tears of the lateral meniscus in the avascular zone. *Arthroscopy* 1998;14:360–365.
- 104. Ra HJ, Ha JK, Jang SH, Lee DW, Kim JG.** Arthroscopic inside-out repair of complete radial tears of the meniscus with a fibrin clot. *Knee Surg Sports Traumatol Arthrosc* 2013;21:2126–2130.
- 105. Wong C-C, Kuo T-F, Yang T-L, et al.** Platelet-rich fibrin facilitates rabbit meniscal repair by promoting meniscocytes proliferation, migration, and extracellular matrix synthesis. *Int J Mol Sci* 2017;18:1722.
- 106. Shahid M, Kundra R.** Platelet-rich plasma (PRP) for knee disorders. *EFORT Open Rev* 2017;2:28–34.
- 107. Pujol N, Salle De Chou E, Boisrenoult P, Beauflis P.** Platelet-rich plasma for open meniscal repair in young patients: any benefit? *Knee Surg Sports Traumatol Arthrosc* 2015;23:51–58.
- 108. Griffin JW, Hadeed MM, Werner BC, Diduch DR, Carson EW, Miller MD.** Platelet-rich plasma in meniscal repair: does augmentation improve surgical outcomes? *Clin Orthop Relat Res* 2015;473:1665–1672.
- 109. Vangsness CT, Farr J, Boyd J, Dellaero DT, Mills CR, LeRoux-Williams M.** Adult human mesenchymal stem cells delivered via intra-articular injection to the knee following partial medial meniscectomy: a randomized, double-blind, controlled study. *J Bone Joint Surg Am* 2014;96:90–98.
- 110. Yuan X, Wei Y, Villasante A, et al.** Stem cell delivery in tissue-specific hydrogel enabled meniscal repair in an orthotopic rat model. *Biomaterials* 2017;132:59–71.
- 111. Moran CJ, Withers DP, Kurzweil PR, Verdonk PC.** Clinical application of scaffolds for partial meniscus replacement. *Sports Med Arthrosc Rev* 2015;23:156–161.
- 112. Henning CE, Yearout KM, Vequist SW, Stallbaumer RJ, Decker KA.** Use of the fascia sheath coverage and exogenous fibrin clot in the treatment of complex meniscal tears. *Am J Sports Med* 1991;19:626–631.
- 113. Rothrauff BB, Numpaisal P-O, Lauro BB, et al.** Augmented repair of radial meniscus tear with biomimetic electrospun scaffold: an in vitro mechanical analysis. *J Exp Orthop* 2016;3:23.
- 114. Cooper DE, Arnoczky SP, Warren RF.** Meniscal repair. *Clin Sports Med* 1991;10:529–548.